# Image of the Month

*Emmanouil P. Pappou, MD; Catherine Velopulos, MD; Elliot K. Fishman, MD; Elliott R. Haut, MD*

A 49-YEAR-OLD WOMAN PRESENTED TO THE emergency department with a 2-day history of epigastric pain and malfunctioning of her peritoneal dialysis (PD) catheter. Her medical history was significant for sarcoidosis, end-stage renal disease secondary to focal segmental glomerulosclerosis associated with sarcoidosis, and hypertension. Her surgical history included a failed live-donor renal transplant and open and laparoscopic PD catheter placements. She had been on continuous ambulatory PD (CAPD) without any complications for a year since her last catheter had been placed. Her daily medications included prednisone, metoprolol succinate, nifedipine, clonidine hydrochloride, and multivitamins. Physical examination revealed a well-healed hockey stick scar in the right lower quadrant from her previous renal transplant, a well-healed infraumbilical scar from her laparoscopic PD catheter placement, and an obvious defect in the right paramedian portion of her upper abdomen underlying a previous incision, containing a mass and a palpated cordlike structure. Laboratory tests showed elevated levels of serum creatinine (9.9 mg/dL; reference range, 0.5-1.2 mg/dL; to convert to micromoles per liter, multiply by 88.4) and blood urea nitrogen (52 mg/dL; reference range, 7-22 mg/dL; to convert to millimoles per liter, multiply by 0.357). Computed tomography with intravenous contrast demonstrated a 3.1 × 2.0-cm right paramedian hernia (**Figure 1**).

**Author Affiliations:** Department of Surgery, Johns Hopkins University School of Medicine, Baltimore, Maryland.

### What Is the Diagnosis?

**A.** Hernia adjacent to PD inner cuff site
**B.** Hernia containing PD catheter
**C.** Hernia containing omentum and right gastroepiploic artery
**D.** Hernia containing foreign body from previous surgery

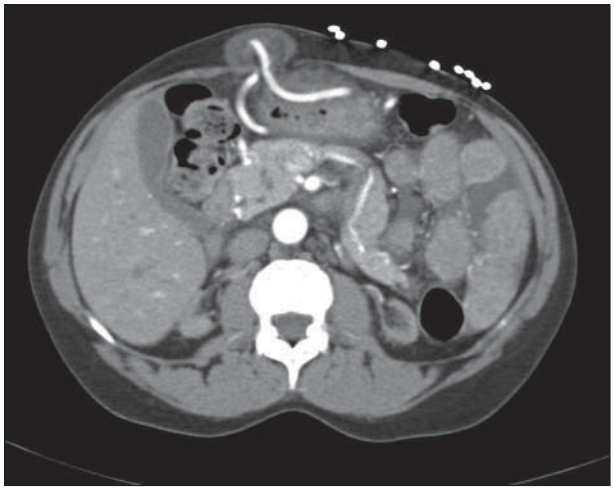

**Figure 1.** Contrast-enhanced axial computed tomographic slice demonstrating a right paramedian hernia.



©2012 American Medical Association. All rights reserved.
Downloaded From: http://archsurg.jamanetwork.com/ on 09/03/2015