SECTION EDITOR: CARL E. BREDENBERG, MD

Image of the Month

Mariana Chavez, MD; Jennifer Danniel, MD; Ronald Miick, MD; Doraid Jarrar, MD; Kamran Khanmoradi, MD; Jorge Ortiz, MD

A 68-YEAR-OLD WOMAN WITH HEPATOCELLULAR carcinoma (HCC) underwent a liver transplant (LT). On preoperative evaluation, she had an α_1-fetoprotein level of 43.7 ng/mL (normal range, <8 ng/mL [to convert to micrograms per liter, multiply by 1.0]), and a computed tomographic (CT) scan of her chest and a bone scan both had negative results. Her tumor was within the Milan criteria. Her native liver explant revealed a T2 lesion without vascular invasion or lymph nodes positive for tumor. One month later, she underwent a retransplant owing to hepatic artery disruption. The liver pathology only showed ischemia. The patient had a satisfactory recovery.

She presented to the emergency department a year later complaining of nausea, vomiting, and weight loss (6.3 kg [14 lb]). On physical examination, she was anicteric, afebrile, and normotensive with no hepatomegaly. Her workup included a white blood cell count of 3800 cells/μL (normal range, 4-11 cells/μL [to convert to $\times 10^9$/L, multiply by 0.001]), a hemoglobin level of 7.6 g/dL (normal range, 12-16 g/dL [to convert to grams per liter, multiply by 10.0]), a creatinine level of 1.3 mg/dL (normal range, 0.7-1.5 mg/dL [to convert to micromoles per liter, multiply by 88.4]), normal albumin and liver enzyme levels, and a normal coagulation profile. Imaging studies included magnetic resonance imaging of the abdomen, CT angiography, a chest CT scan, a bone scan, and ultrasonography, all of which had negative results. She subsequently underwent a positron emission tomographic/CT scan (**Figure 1**).

Author Affiliations: Departments of Transplant Surgery (Drs Chavez, Danniel, Jarrar, Khanmoradi, and Ortiz) and Pathology (Dr Miick), Albert Einstein Healthcare Network, Philadelphia, Pennsylvania.

What Is the Diagnosis?

A. Osteomyelitis
B. Chondrosarcoma
C. Multiple myeloma
D. Bone metastases from HCC

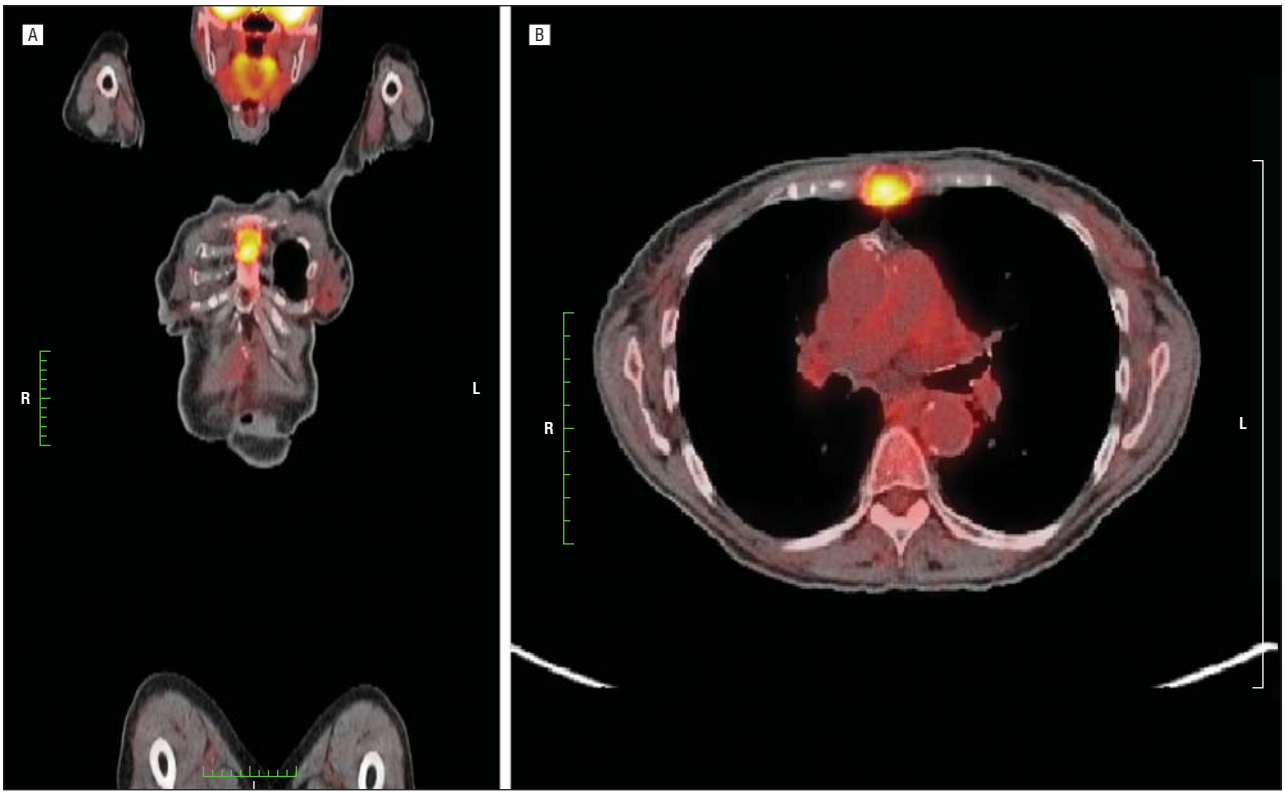

Figure 1. A and B, Fludeoxyglucose F18–positron emission tomographic/computed tomographic scans showing increased uptake in the upper half of the sternal body. L indicates left; and R, right.

©2013 American Medical Association. All rights reserved.

Downloaded From: http://archsurg.jamanetwork.com/ on 07/22/2014