SECTION EDITOR: GRACE S. ROZYCKI, MD

Image of the Month

David V. Feliciano, MD

A 32-YEAR-OLD previously healthy woman was seen for a slowly enlarging right anterior cervical mass. She denied a history of irradiation of the thymus in childhood, previous disease of the thyroid, any familial endocrine syndrome, or any systemic symptoms. Findings from physical examination demonstrated a firm nontender nodule that moved with swallowing and was adherent to the lateral aspect of the right lobe of the thyroid gland. Ultrasonography of the thyroid gland confirmed the presence of a 3.7 × 2.6 × 2.6-cm solid right thyroid nodule. A fine-needle aspiration (FNA) of the nodule was performed and was diagnosed by a cytopathologist as benign thyroid tissue. Levels from thyroid function tests included T_4, 172 nmol/L (13.4 µg/dL); T_3, 3.90 nmol/L; thyroid-stimulating hormone (TSH), 0.5 mIU/L; T_3 resin uptake, 31%; and free thyroxine index, 54 pmol/L (4.2 ng/dL). A thyroid radionuclide scan with ^{123}I demonstrated a "hot" nodule in the right lobe of the thyroid gland with suppression of all remaining thyroid tissue (**Figure 1**).

From Emory University School of Medicine and Grady Memorial Hospital, Atlanta, Ga.

What Is the Most Appropriate Management for This Patient?

A. Ultrasound-directed injection of sodium morrhuate
B. Administration of 3700 MBq of ^{131}I
C. Suppression with exogenous T_3
D. Thyroid lobectomy

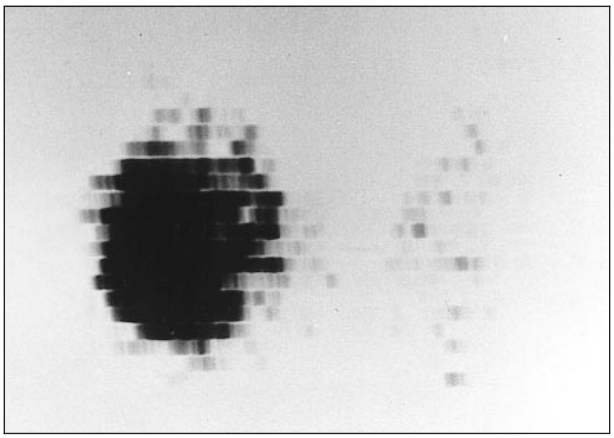

Figure 1. *Radionuclide scan demonstrates a "hot" nodule in the right lobe of the thyroid gland with suppression of all remaining thyroid tissue.*

©2001 American Medical Association. All rights reserved.
Downloaded From: http://archsurg.jamanetwork.com/ on 04/24/2017

Answer

Toxic Adenoma or Solitary Autonomous Nodule (Variant of Plummer Disease)

Palpable solitary thyroid nodules are present in approximately 5% to 6% of American women, a rate that is at least 4 times greater than that noted in men in several studies.[1] Despite the small number of patients who develop thyroid cancer in the United States each year (estimated 18 400 in 2000), many thyroidectomies in the past were performed to rule out a malignant tumor in such nodules.[2] The availability of early and accurate diagnosis from FNA, however, has significantly decreased unnecessary thyroidectomies for benign nodules over the past 25 years.[3,4] At present, indications for operation in patients with solitary thyroid nodules include the following:

- Nondiagnostic (15%-20%) or suspicious (10%) FNA
- Malignant cells on FNA (4%)
- Growth of nodule (use ultrasound to rule out hemorrhage into the nodule) in patient receiving thyroxine therapy
- Symptomatic (pain, tracheal deviation with respiratory symptoms, odynophagia) nodule in patient without evidence of hemorrhage into the nodule
- Patient request to improve cosmetic appearance
- Toxic (hyperfunctioning) adenoma

Clinical hyperthyroidism from a hyperfunctioning adenoma develops gradually over time. Asymptomatic patients with reasonably normal TSH levels associated with an FNA-benign nodule can be observed according to a standard endocrinology textbook. When TSH levels fall below normal levels and the patient is symptomatic, current therapeutic options for a toxic adenoma include antithyroid drugs, radioactive iodine, percutaneous injection of ethanol, and thyroidectomy.[5]

Antithyroid drugs have the disadvantage of recurrent hyperthyroidism when administration is stopped, but they have been used before administration of radioactive iodine or thyroidectomy in elderly patients. Radioactive iodine should be taken up by the hyperfunctioning nodule when the remainder of the thyroid gland is suppressed (Figure 1). Five to 15 mCi ^{131}I should result in a cure rate of 90% in elderly patients.[6,7] Multiple percutaneous injections of sterile 95% ethanol into the toxic adenoma with ultrasonography resulted in a cure rate of 78% in an Italian study (median follow-up, 2.5 years).[8]

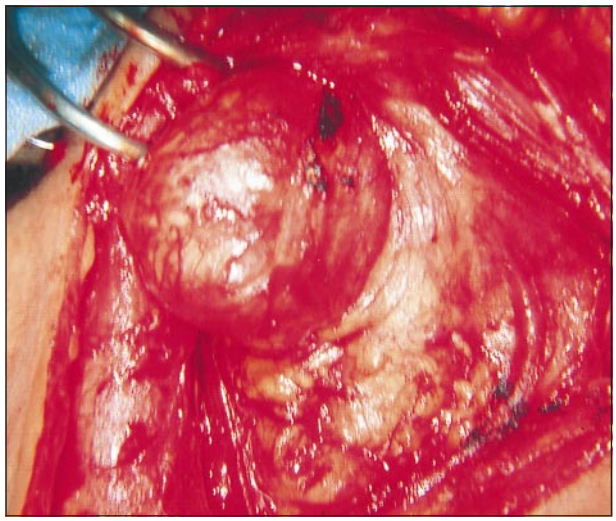

Figure 2. *"Hot" nodule. Treatment was a right thyroid lobectomy.*

Toxic adenomas are the third most common indication for surgical intervention for hyperthyroidism.[9,10] Depending on local referral patterns to endocrine surgeons, operations for toxic adenoma account for 5% to 20% of current operations for hyperthyroidism. Thyroidectomy is generally recommended for children, adults, and should be considered for otherwise healthy elderly patients with large nodules. Most patients referred from endocrinologists return to a euthyroid state by the administration of antithyroid drugs. Preoperative administration of a saturated solution of potassium iodide is unnecessary. Either nodulectomy or subtotal vs total thyroid lobectomy can be performed (**Figure 2**). Thyroidectomy is immediately curative in patients who are euthyroid at the time of operation. Postoperative and late rates of hypothyroidism are reported to be 10% to 20% in the medical literature.[7,11]

Corresponding author: David V. Feliciano, MD, Grady Memorial Hospital, Thomas K. Glenn Memorial Bldg, Department of Surgery, 69 Butler St SE, Third Floor, Atlanta, GA 30303.

REFERENCES

1. Vander JB, Gaston EA, Dawber TR. The significance of nontoxic thyroid nodules. *Ann Intern Med.* 1968;69:537-540.
2. Greenlee RT, Murray T, Bolden S, Wingo PA. Cancer statistics, 2000. *Cancer.* 2000;50:7-33.
3. Einhorn J, Franzen S. Thin needle biopsy in the diagnosis of thyroid disease. *Acta Radiol (Stockh).* 1962;58:321-336.
4. Gharib H, Goellner JR. Fine-needle aspiration of the thyroid: an appraisal. *Ann Intern Med.* 1993;118:282-289.
5. Hermus AR, Huysmans DA. Treatment of benign nodular thyroid disease. *N Engl J Med.* 1998;338:1438-1447.
6. Larsen PR, Davies TF, Hay ID. The thyroid gland. In: Wilson JD, Foster DW, Kronenberg HM, Larsen PR, eds. *Williams' Textbook of Endocrinology.* 9th ed. Philadelphia, Pa: WB Saunders Co; 1998:389-515.
7. Giuffrida D, Gharib H. Controversies in the management of cold, hot, and occult thyroid nodules. *Am J Med.* 1995;99:642-650.
8. Monzani F, Caraccio N, Goletti O, et al. Five-year follow-up of percutaneous ethanol injection for the treatment of hyperfunctioning thyroid nodules: a study of 117 patients. *Clin Endocrinol.* 1997;46:9-15.
9. Graves RJ. Newly observed affection of the thyroid gland in females. *London Med Surg J.* 1835;7(part 2):516-517.
10. Plummer HS. The clinical and pathological relationship of simple and exophthalmic goitre. *Trans Assoc Am Physicians.* 1913;28:587-594.
11. Ferrari C, Reschini E, Paracchi A. Treatment of the autonomous thyroid nodule: a review. *Eur J Endocrinol.* 1996;135:383-390.

Submissions

The Editor welcomes contributions to the *Image of the Month*. Those who wish to contribute should send their manuscripts to Grace S. Rozycki, MD, Department of Surgery, Emory University School of Medicine, 69 Butler St SE, Atlanta, GA 30303; (404) 616-3553; fax (404) 616-7333 (e-mail: grozycki@emory.edu). Articles and photographs accepted for publication will bear the contributor's name. There is no charge for reproduction and printing of color illustrations.

©2001 American Medical Association. All rights reserved.
Downloaded From: http://archsurg.jamanetwork.com/ on 04/24/2017