

SECTION EDITOR: GRACE S. ROZYCKI, MD

## Image of the Month

Grace S. Rozycki, MD

**A** 66-YEAR-OLD retired executive experienced sudden onset of severe interscapular pain after forceful vomiting. His medical history was notable for peptic ulcer disease and hiatal hernia, but he denied alcohol abuse. Remarkable findings on physical examination included decreased breath sounds and rales on the right side of his chest. Vital signs were

blood pressure, 170/90 mm Hg; respiratory rate, 32 breaths per minute; heart rate, 116 beats per minute; and temperature, 36.8°C. Radiographs were obtained (**Figure 1** and **Figure 2**).

### What Is the Diagnosis?

- A. Malory-Weiss tear
- B. Spontaneous rupture of the esophagus
- C. Perforated duodenal ulcer
- D. Severe gastritis

From the Department of Surgery, Emory University, Atlanta, Ga.

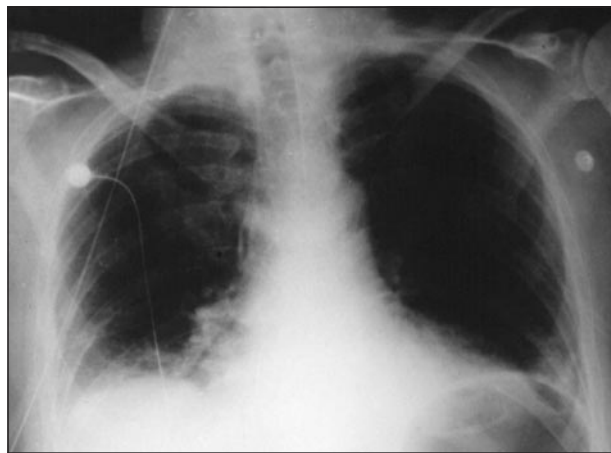


Figure 1.

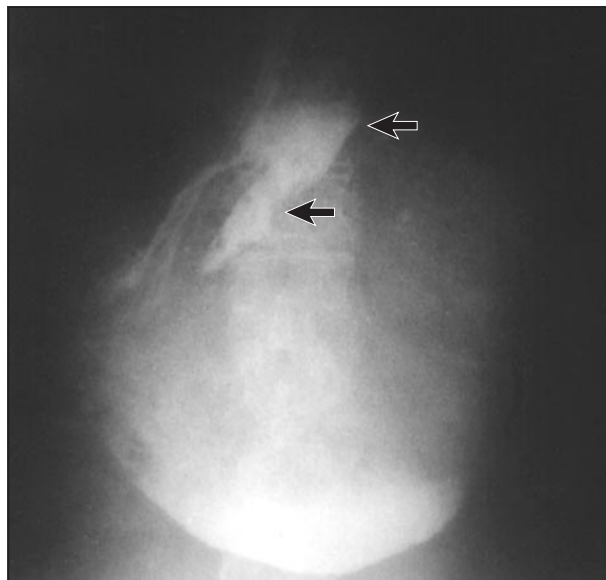


Figure 2.

# Answer

## Esophageal Perforation (Boerhaave Syndrome)

**Figure 1.** Chest x-ray film showing right pleural effusion.

**Figure 2.** Esophagram demonstrating extravasation of contrast at right lower esophagus (arrows).

**A**s a life-threatening problem, esophageal perforation should be diagnosed and treated rapidly to provide a good outcome for the patient and prevent serious adverse sequelae. In 1724, Hermann Boerhaave described the syndrome after observing, on post-mortem examination, a transmural rupture of the distal esophagus in Admiral Baron John de Wassenaeur of the Holland Navy.<sup>1,2</sup> Although gastroesophageal reflux is often associated with the syndrome, other entities, including neurological diseases, hypertension, alcoholism, peptic ulcer disease, esophageal stricture, esophagitis, or neoplasm, are contributory factors. Presenting symptoms are often vomiting, nausea, and sharp chest pain. Patients are frequently dyspneic and, in an effort to minimize discomfort, sit upright and forward. Pertinent physical findings include basilar rales, wheezing, and crepitus along the chest wall.

The chest x-ray film findings may show the “V” sign of Naclerio, which indicates chemical pneumonitis of the paramedial aspect of the left lower lobe of the lung.<sup>3,4</sup> Additional findings include atelectasis, effusion, and some mediastinal air. The diagnosis, however, is usually confirmed with an esophagram demonstrating extravasation of the contrast, but esophagoscopy may also be helpful. A full-thickness tear at the left postolateral area in the lower third of the esophagus is usually found. Occasionally, as in this patient, a right-sided perforation is detected.<sup>5,6</sup> If a tube thoracostomy is placed within a few hours of the perforation, clear fluid with some food particles is noted in the effluent. In those cases in which the diagnosis is delayed, the effluent is rusty brown in color and has a high amylase level.<sup>3,4</sup>

Surgical management remains the mainstay of therapy for esophageal rupture with debridement of the perforation, primary repair in 2 layers, and drainage of the pleural cavity. Because the perforation is usually on the left side, a thoracic approach is often used. In this patient, a transabdominal approach was used success-

fully, and his postoperative course was unremarkable. Before the perforation is repaired, the wound should be carefully examined to identify the mucosa, which is often lacerated beyond the extent of the muscular perforation. A buttress or patch over the repair is recommended such as a gastric fundal patch or a pericardial or pleural patch. Recently, some authors have recommended the application of an absorbable mesh with fibrin glue as a form of buttress.<sup>7</sup>

*Corresponding author and reprints: Grace S. Rozycki, MD, Department of Surgery, Emory University, Glenn Memorial Building, Room 302, 69 Butler St SE, Atlanta, GA 30303 (e-mail: grozyck@emory.edu).*

### REFERENCES

1. Derbes VJ, Mitchell RE. *Hermann Boerhaave's Atrocis, nec Descripti Prius. Morbi Historia: the first translation of the classic case report of rupture of the esophagus, with annotations.* *Bull Med Libr Assoc.* 1955;43:217.
2. Liebermann-Meffert D, Brauer RB, Stein HJ. Boerhaave's syndrome: the man behind the syndrome. *Dis Esophagus.* 1997;10:77-85.
3. Bjerke HS. Boerhaave's syndrome and barogenic injuries of the esophagus. *Chest Surg Clin North Am.* 1994;4:819-825.
4. Achem SR. Boerhaave's syndrome. *Dig Dis.* 1999;17:256.
5. Levy F, Mysko WK, Kelen GD. Spontaneous esophageal perforation presenting with right-sided pleural effusion. *J Emerg Med.* 1995;13:321-325.
6. Chang YC, Liu HC, Huang CJ, Wu CL. Right-sided pleural effusion in spontaneous esophageal perforation. *Ann Thorac Cardiovasc Surg.* 2000;6:73-76.
7. Bardaxoglou E, Manganas D, Meunier B, et al. New approach to surgical management of early esophageal thoracic perforation: primary suture repair reinforced with absorbable mesh and fibrin glue. *World J Surg.* 1997;21:618-621.

### Submissions

The Editor welcomes contributions to the *Image of the Month*. Those who wish to contribute should send their manuscripts to Grace S. Rozycki, MD, Department of Surgery, Emory University School of Medicine, 69 Butler St SE, Atlanta, GA 30303; (404) 616-3553; fax (404) 616-7333 (e-mail: grozycki@emory.edu). Articles and photographs accepted for publication will bear the contributor's name. There is no charge for reproduction and printing of color illustrations.