

SECTION EDITOR: GRACE S. ROZYCKI, MD

## Image of the Month

David V. Feliciano, MD

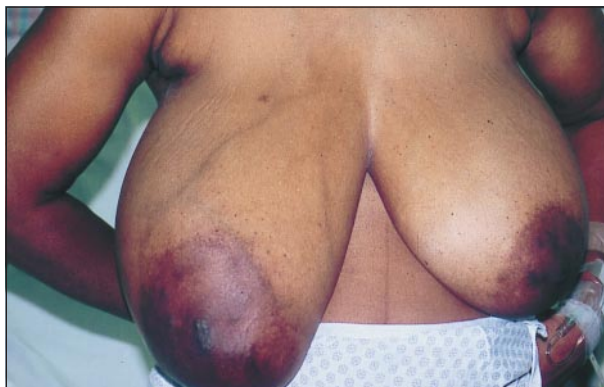**A** 46-YEAR-OLD previously healthy woman was seen for a rapidly enlarging right breast mass. She had been told many years before that she had a right breast “cyst,” and the size had evidently not changed until the past 8 to 12 weeks. The patient denied a history of familial breast disease, left breast disease, or nipple discharge. Physical examination demonstrated venous engorgement in the skin of the right breast and a 15 × 10-cm firm, nontender, movable mass (**Figure 1**). There were

no other skin changes, no fixation to the chest wall, and no palpable axillary nodes. Fine-needle aspiration of the right breast mass demonstrated multiple fragments of stroma with marked atypia.

### What Is the Most Appropriate Treatment for This Patient?

- A. External beam radiation therapy with 50 Gy in 20 fractions
- B. Induction chemotherapy with cyclophosphamide and doxorubicin
- C. Total mastectomy
- D. Tamoxifen 10 mg, twice daily

*From the Department of Surgery, Grady Memorial Hospital and Emory University School of Medicine, Atlanta, Ga.*



**Figure 1.** A 15 × 10-cm mass in the patient's right breast grew rapidly during the past 8 to 12 weeks. A “cyst” had been noted previously.

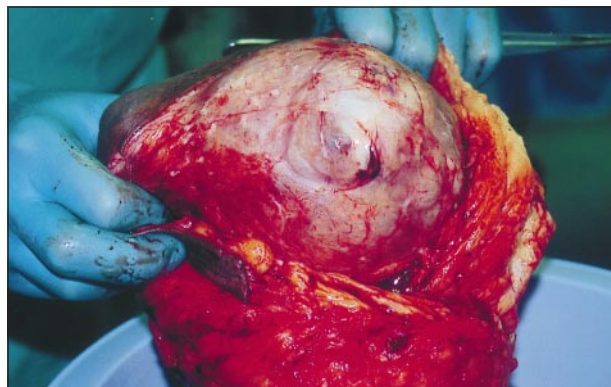
# Answer

## Right Total Mastectomy

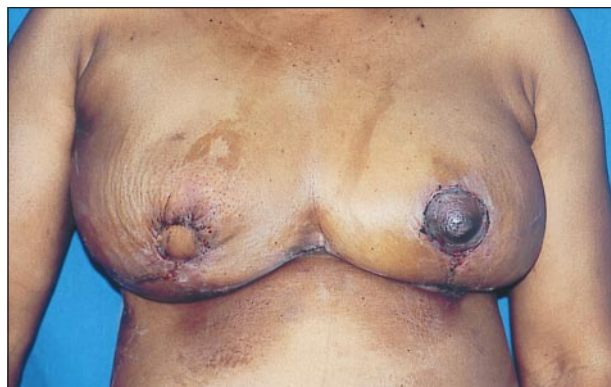**B**ased on the patient's history, physical examination, and the atypical stromal cells on fine-needle aspiration, a presumptive diagnosis of a malignant cystosarcoma phyllodes tumor (Müller tumor) of the right breast was made. The patient underwent a total right mastectomy without axillary dissection (**Figure 2**). At the patient's request, the right breast was immediately reconstructed with a right-sided latissimus dorsi myocutaneous flap and a saline implant by a plastic surgeon. Reduction mammoplasty of the left breast was also performed (**Figure 3**).

Final pathology described a 15 × 10 × 9-cm malignant phyllodes tumor with extensive myxoid change. The tumor was circumscribed, the margins of resection were clear, there was no involvement of the skin of the breast, nipple, or vascular channels, and there was marked pleomorphism and anaplasia. The patient received no further therapy and is being followed up by the surgery and medical oncology services. A physical examination and mammogram of the left breast both had normal findings at 20 months following right mastectomy and reconstruction.

Originally named by Johannes Müller in 1838, the term *cystosarcoma phyllodes* refers to an uncommon tumor with a cystic and lobulated appearance that most commonly appears in the female breast.<sup>1,2</sup> Cystosarcoma phyl-



**Figure 2.** Operative specimen of right total mastectomy. Note the cystic appearance of the cystosarcoma phyllodes tumor.



**Figure 3.** Appearance of patient after right breast reconstruction and left breast reduction.

lodes accounts for approximately 0.5% to 1.0% of all breast tumors.<sup>3,4</sup> The average age of onset is 45 years, but deaths from metastatic sarcoma have been reported in adolescent females.<sup>5,6</sup> A solitary and large unilateral breast mass is the usual sign, and approximately 25% of patients complain of recent rapid growth in a known breast mass.<sup>7</sup>

An ultrasound of a cystosarcoma phyllodes tumor will demonstrate a solid hypoechoic mass. On mammography, there will be a nonspiculated soft tissue mass that may represent either a benign or a malignant variant.<sup>8</sup>

A benign cystosarcoma phyllodes resembles a fibroadenoma histologically but has increased stromal cellularity.<sup>2,9</sup> There is not, however, uniform agreement about the histologic criteria that separate benign from malignant variants. In one review of the pathological specimens from 26 patients with cystosarcoma phyllodes, stromal overgrowth was found to be a significant predictor of metastatic spread and death of the patient.<sup>9</sup> Stromal overgrowth was defined as “mesenchymal proliferation with complete absence of a ductal epithelial element in an area greater than one low power (×40) field.”<sup>9(p2287)</sup>

The surgical treatment for smaller lesions is local excision with clear margins around the tumor. Because phyllodes tumors do not have true capsules, reexcision is necessary when the lesion is diagnosed on postoperative histologic sections and the margins are unclear.<sup>4</sup> Larger tumors and recurrences of borderline and malignant tumors are treated with total mastectomy with simultaneous reconstruction based on patient preference.<sup>10</sup> Axillary dissection is not indicated in the absence of clinically involved nodes on preoperative examination.<sup>11</sup> There is no indication for postoperative chemotherapy after the excision of malignant tumors. Postoperative radiation therapy has been suggested for large tumors or for recurrences involving the skin or fascia of the pectoralis major muscle.<sup>3</sup> In a series from M. D. Anderson Hospital and Tumor Institute (Houston, Tex), 7 (27%) of 26 patients died of uncontrolled local recurrence or metastatic disease at a mean period of 30 months following resection.<sup>9</sup>

Corresponding author and reprints: David V. Feliciano, MD, Department of Surgery, Grady Memorial Hospital, 69 Butler St SE, Atlanta, GA 30303 (e-mail: dfelici@emory.edu).

## REFERENCES

1. Müller J. *Über den feineren Bau und die Formen der krankhaften Geschwülste*. Berlin, Germany: G Reimer; 1838. Cited by: Fiks A. Cystosarcoma phyllodes of the mammary gland—Müller's tumor: for the 180th birthday of Johannes Müller. *Virchows Arch A Pathol Anat Histol*. 1981;392:1-6.
2. Fiks A. Cystosarcoma phyllodes of the mammary gland—Müller's tumor: for the 180th birthday of Johannes Müller. *Virchows Arch A Pathol Anat Histol*. 1981; 392:1-6.
3. Copeland EM III, Klimberg VS. Malignant breast disease. In: Levine BA, Copeland EM III, Howard RJ, Sugarman HJ, Warshaw AL, eds. *Current Practice of Surgery*. Vol 2. New York, NY: Churchill Livingstone; 1993:1-42.
4. Mies C. Mammary sarcoma and lymphoma. In: Bland KI, Copeland EM III, eds. *The Breast: Comprehensive Management of Benign and Malignant Diseases*. 2nd ed. Philadelphia, Pa: WB Saunders; 1998:307-322.

5. Kessinger A, Foley JF, Lemon HM, et al. Metastatic cystosarcoma phyllodes: a case report and review of the literature. *J Surg Oncol.* 1972;4:131-147.
6. Turalba CI, el-Mahdi AM, Ladaga L. Fatal metastatic cystosarcoma phyllodes in an adolescent female: case report and review of treatment approaches. *J Surg Oncol.* 1986;33:176-181.
7. Hawkins RE, Schofield JB, Fisher C, et al. The clinical and histologic criteria that predict metastases from cystosarcoma phyllodes. *Cancer.* 1992;69:141-147.
8. Liberman L, Bonaccio E, Hamele-Bena D, et al. Benign and malignant phyllodes tumors: mammographic and sonographic findings. *Radiology.* 1996;198:121-124.
9. Ward RM, Evans HL. Cystosarcoma phyllodes: a clinicopathologic study of 26 cases. *Cancer.* 1986;58:2282-2289.
10. Salvadori B, Cusumano F, Del Bo R, et al. Surgical treatment of phyllodes tumors of the breast. *Cancer.* 1989;63:2532-2536.
11. Haagensen CD. Cystosarcoma phyllodes. In: Haagensen CD. *Diseases of the Breast.* 3rd ed. Philadelphia, Pa: WB Saunders;1986:284-312.

The Editor welcomes contributions to the *Image of the Month*. Those who wish to contribute should send their manuscripts to Grace S. Rozycki, MD, Department of Surgery, Emory University School of Medicine, 69 Butler St SE, Atlanta, GA 30303; (404) 616-3553; fax (404) 616-7333 (e-mail: grozycki@emory.edu). Articles and photographs accepted for publication will bear the contributor's name. There is no charge for reproduction and printing of color illustrations.

#### IN OTHER AMA JOURNALS

##### ARCHIVES OF INTERNAL MEDICINE

##### Clinical and Economic Assessment of the Omeprazole Test in Patients With Symptoms Suggestive of Gastroesophageal Reflux Disease

Ronnie Fass, MD; Joshua J. Ofman, MD, MSHS; Ian M. Gralnek, MD, MSHS; Cynthia Johnson, MA; Elizabeth Camargo; Richard E. Sampliner, MD; M. Brian Fennerty, MD

**Objective:** To evaluate the diagnostic accuracy of a trial of a high-dose proton pump inhibitor (the omeprazole test) in detecting gastroesophageal reflux disease (GERD) in patients with heartburn symptoms.

**Design:** A randomized, double-blind, placebo-controlled, crossover trial.

**Patients and Setting:** Forty-three consecutive patients with symptoms suggestive of GERD were enrolled at a Veterans Affairs medical center.

**Main Outcome Measures:** Symptom response to the omeprazole test vs placebo in GERD-positive and GERD-negative patients; sensitivity, specificity, and positive and negative predictive values of the omeprazole test; and cost per correct diagnosis achieved with the omeprazole test compared with traditional diagnostic strategies.

**Results:** Of 42 patients (98%) who completed the study, 35 (83%) were classified as GERD positive and 7 (17%) as GERD negative. Twenty-eight GERD-positive and 3 GERD-negative patients responded to the omeprazole test, providing a sensitivity of 80.0% (95% confidence interval, 66.7%-93.3%) and a specificity of 57.1% (95% confidence interval, 20.5%-93.8%). Economic analysis revealed that the omeprazole test saves \$348 per average patient evaluated, and results in a 64% reduction in the number of upper endoscopies performed and a 53% reduction in the use of pH testing.

**Conclusions:** The omeprazole test is sensitive and fairly specific for diagnosing GERD in patients with typical GERD symptoms. This strategy could result in significant cost savings and decreased use of invasive diagnostic tests. (1999;159:2161-2168)

**Reprints:** Ronnie Fass, MD, Section of Gastroenterology (111G-1), Tucson VA Medical Center, 3601 S Sixth Ave, Tucson, AZ 85723 (e-mail: ronnie.fass@med.va.gov).