

SECTION EDITOR: GRACE S. ROZYCKI, MD

Image of the Month

Ruth L. Bush, MD; Peter H. Lin, MD; Alan B. Lumsden, MD

A 78-YEAR-OLD MAN with multiple medical comorbidities, including coronary artery disease, hypertension, and peripheral vascular disease, underwent aorto-bifemoral bypass grafting and concomitant femoral-popliteal bypass for short-distance buttock and thigh claudication. An arteriogram performed preoperatively demonstrated severe aortoiliac occlusive disease. He had been on long-term warfarin therapy since the 1960s for an unknown hypercoagulable state and recurrent episodes of deep venous thromboses.

The operation proceeded unremarkably; however, by postoperative day 6, the patient was noted to have necro-

sis of the tips of his fingers on both hands, the right being worse (**Figure 1**). He had been given intravenous heparin on postoperative day 2 due to his history of hypercoagulability. His presurgery platelet count was $205 \times 10^3/\mu\text{L}$. His platelet count postoperatively dropped to $81 \times 10^3/\mu\text{L}$. This decrease was felt to be due to operative dilution and blood loss. However, by the sixth postprocedure day, the platelet count had dropped further to $50 \times 10^3/\mu\text{L}$.

What Is the Most Appropriate Treatment for This Patient?

- Obtain PF4-heparin antibody enzyme-linked immunosorbent assay results
- Stop all heparin therapy and treat with lepirudin
- Amputate all necrotic digits
- Transfuse with platelets until level is within normal range

From the Joseph B. Whitehead Department of Surgery, Division of Vascular Surgery, Emory University School of Medicine and the Emory University Hospital, Atlanta, Ga.

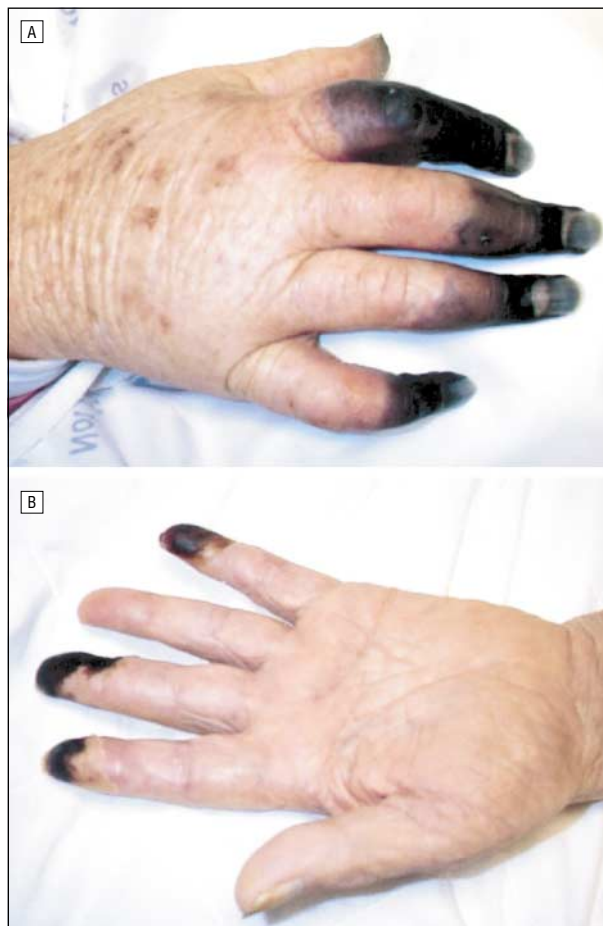


Figure 1.

Answer

Heparin-Induced Thrombocytopenia: Stop All Heparin Therapy and Treat With Lepirudin

Figure 1. Necrotic digits on both hands appearing on postoperative day 5.

Heparin was originally discovered in 1916 from liver extracts. Now it is more commonly prepared from either bovine or porcine mucosal extracts. The mechanism of action is via binding to antithrombin III, which then inactivates the activated coagulation factors IIa, IXa, and Xa (Figure 2). Heparin-induced thrombocytopenia (HIT) occurs in up to 6% of patients receiving heparin therapy for any reason. There are 2 types of HIT that occur clinically. Type I, which is more common, appears early on after the institution of therapy and is mild in nature. The patients tend to be asymptomatic and this type is rarely associated with thromboembolic sequelae. Conversely, type II is delayed in onset and is more severe.¹ Thromboembolic complications do occur with type II.

In type II HIT, an immune-mediated platelet aggregation caused by IgG and IgM binding to platelet factor 4 complex occurs.² Platelet activation by antiheparin platelet factor 4 antibodies results, with subsequent release of thrombogenic particles. This may lead to the “white clot” syndrome, associated with limb- and/or life-threatening thromboembolic complications. Risk factors for HIT include history of unfractionated heparin exposure, intravenous fractionated heparin, bovine heparin, and cardiopulmonary bypass.³

The clinical diagnosis of HIT is made when a patient's platelet count decreases below $1500 \times 10^3/\mu\text{L}$ or 30% to 50% from baseline, an effect that is seen at least 5 days following heparin exposure.⁴ Appropriate confirming laboratory data may include platelet counts, PF4-heparin antibody levels by enzyme-linked immunosorbent assay, heparin-induced platelet aggregation, and serotonin release assay.^{2,5,6} The management of HIT involves the discontinuation of all heparin, including flushes and heparin-coated catheters. The patient must then be treated against further thrombotic episodes with a direct thrombin inhibitor, such as lepirudin.⁷ This is an intravenous medication, which is monitored by maintaining the partial thromboplastin time 2 to 3 times above the baseline level. Hirudin was originally isolated from the salivary glands of the medicinal leech. It is now produced as lepirudin (r-hirudin) by recombinant DNA technology.

Corresponding author: Peter H. Lin, MD, The Emory Clinic, 1365 A Clifton Rd NE, Suite 3323, Atlanta, GA 30322 (e-mail: peter_lin@emory.org).

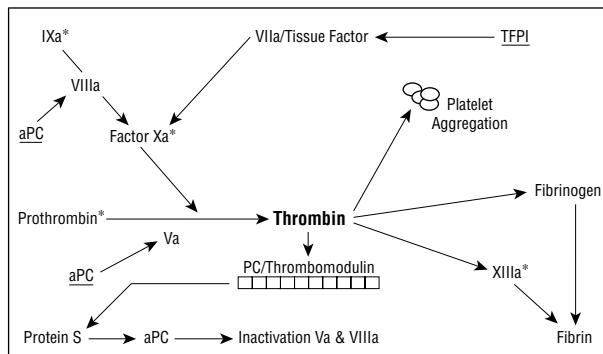


Figure 2. Diagram illustrating various sites of possible thrombin inactivation in the coagulation pathway. Asterisk indicates sites of heparin/inhibition; aPC, activated protein C; and TFPI, tissue factor pathway inhibitor.

REFERENCES

1. Baglin TP. Heparin induced thrombocytopenia thrombosis (HIT/T) syndrome: diagnosis and treatment. *J Clin Pathol.* 2001;54:272-274.
2. Rugeri L, Bauters A, Trillot N, et al. Hemostasis and thrombosis: clinical usefulness of combined use of platelet aggregation test and anti PF4-H antibodies elisa test for the diagnosis of heparin induced thrombocytopenia. *Hematology.* 1999; 4:367-373.
3. Manfredi JA, Wall RP, Sane DC, Braden GA. Lepirudin as a safe alternative for effective anticoagulation in patients with known heparin-induced thrombocytopenia undergoing percutaneous coronary intervention: case reports. *Catheter Cardiovasc Interv.* 2001;52:468-472.
4. Warkentin TE, Kelton JG. Temporal aspects of heparin-induced thrombocytopenia. *N Engl J Med.* 2001;344:1286-1292.
5. Harenberg J, Wang LC, Hoffman U, Huhle G, Feuring M. Laboratory diagnosis of heparin-induced thrombocytopenia type II after clearance of platelet factor 4/heparin complex. *J Lab Clin Med.* 2001;137:408-413.
6. Elalamy I, Lecrubier C, Horellou MH, Conard J, Samama MM. Heparin-induced thrombocytopenia: laboratory diagnosis and management. *Ann Med.* 2000;32 (suppl 1):60-67.
7. Greinacher A, Lubenow N. Recombinant hirudin in clinical practice: focus on lepirudin. *Circulation.* 2001;103:1479-1484.

Submissions

The Editor welcomes contributions to the *Image of the Month*. Send manuscripts to Grace S. Rozycki, MD, Department of Surgery, Emory University School of Medicine, 69 Butler St SE, Atlanta, GA 30303; (404) 616-3553; fax (404) 616-7333 (e-mail: grozyck@emory.edu). Articles and photographs accepted will bear the contributor's name. Manuscript criteria and information are per the Instructions for Authors for *Archives of Surgery*. No abstract is needed, and the manuscript should be no more than 3 typewritten pages. There should be a brief introduction, 1 multiple-choice question with 4 possible answers, and the main text. No more than 2 photographs should be submitted. There is no charge for reproduction and printing of color illustrations.