

SECTION EDITOR: GRACE S. ROZYCKI, MD

Image of the Month

Sasan Najibi, MD; Thomas T. Terramani, MD; Vinod H. Thourani, MD;
William T. Brinkman, MD; Alan B. Lumsden, MD; Thomas F. Dodson, MD

AN 80-YEAR OLD MAN had a pulsatile abdominal mass on physical examination. Findings on computed tomography of his abdomen showed a 5.2-cm infrarenal abdominal aortic aneurysm (not shown). In addition to this finding, there was a cal-

cified mass in the right upper quadrant of his abdomen (**Figure 1**).

What Is the Diagnosis?

- A. Superior mesenteric artery aneurysm
- B. Calcified lymph node
- C. Hepatic artery aneurysm
- D. Celiac artery aneurysm

From the Division of Vascular Surgery, Emory University School of Medicine, Atlanta, Ga.

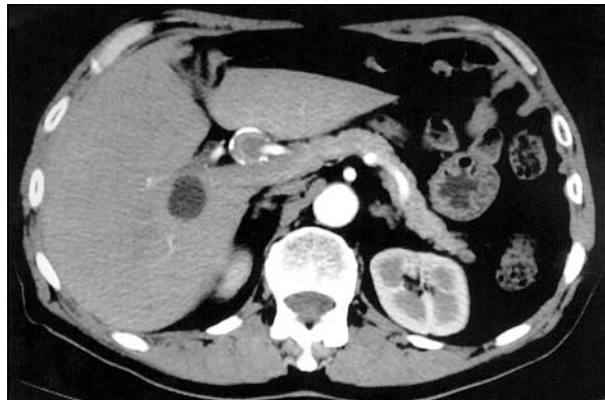

Figure 1.

Answer

Hepatic Artery Aneurysm

Figure 1. Computed tomographic scan of abdomen demonstrating a calcified hepatic artery aneurysm.

Figure 2. Intraoperative photograph of the hepatic artery aneurysm. RHA indicates right hepatic artery; LHA, left hepatic artery; CHA, common hepatic artery, and GDA, gastroduodenal artery.

Most extrahepatic artery aneurysms are solitary, involving the common or right hepatic artery (**Figure 2**). In general, because most patients are asymptomatic, the diagnosis is usually made as an incidental finding on imaging studies performed for other reasons.

Most of these aneurysms are true aneurysms and have pathologic changes suggestive of medial degeneration with secondary atherosclerosis. Other causes include mycotic aneurysms and the postinflammatory aneurysms that occur in the setting of acute pancreatitis or cholecystitis.

The exact natural history and rate of rupture are unknown because of their rarity. The incidence of rupture has been reported to be from 20%¹ to 80%^{2,3}; this variation is the result of the large number of asymptomatic aneurysms that are undetected.

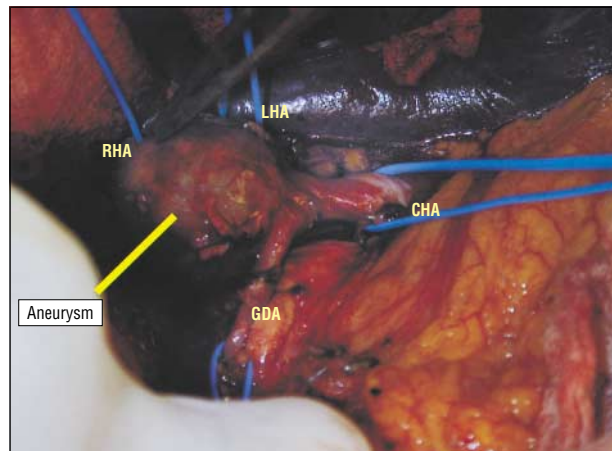


Figure 2.

Once the diagnosis is made, arteriography is needed to localize the lesion and identify collateral and aberrant hepatic arteries. In general, all extrahepatic arterial aneurysms greater than 2 cm in diameter should be treated with resection or ligation (if the aneurysm involves the common hepatic artery) depending on the anatomic location of the aneurysm.⁴ Those extrahepatic aneurysms of the proper hepatic artery require resection and revascularization.

Corresponding author and reprints: Thomas F. Dodson, MD, Division of Vascular Surgery, Emory University Hospital, 1364 Clifton Rd, Suite H-124, Atlanta, GA 30329.

REFERENCES

1. Stanley JC, Messina LM, Zelenock GB. Splanchnic and renal artery aneurysms. In: Moore WS, ed. *Vascular Surgery: A Comprehensive Review*. 5th ed. Philadelphia, Pa: WB Saunders Co; 1997.
2. Dougherty MJ, Gloviczi P, Cherry KJ Jr, Bower TC, Hallett JW, Pairorero PC. Hepatic artery aneurysms: evaluation and current management. *Int Angiol*. 1993; 12:178-184.
3. Rogers MD, Thompson JE, Garrett WV, Talkington CM, Patman RD. Mesenteric vascular problems: a 26-year experience. *Ann Surg*. 1982;195:554-565.
4. Lumsden AB, Mattar AG, Allen RC, Bacha EA. Hepatic artery aneurysms: the management of 22 patients. *J Surg Res*. 1995;60:345-350.

Submissions

The Editor welcomes contributions to the "Image of the Month." Send manuscripts to Grace S. Rozycki, MD, Department of Surgery, Emory University School of Medicine, 69 Butler St SE, Atlanta, GA 30303; (404) 616-3553; fax (404) 616-7333 (e-mail: grozyck@emory.edu). Articles and photographs accepted will bear the contributor's name. Manuscript criteria and information are per the "Instructions for Authors" for *Archives of Surgery*. No abstract is needed, and the manuscript should be no more than 3 typewritten pages. There should be a brief introduction, 1 multiple-choice question with 4 possible answers, and the main text. No more than 2 photographs should be submitted. There is no charge for reproduction and printing of color illustrations.