

SECTION EDITOR: GRACE S. ROZYCKI, MD

## Image of the Month

Kurt R. Stahlfeld, MD; Michael Edwards; Harry W. Sell, MD

**A** 65-YEAR-OLD man had a 1-week history of midepigastic pain, nausea, and vomiting. He denied any previous abdominal complaints. His medical history was significant for peripheral vascular disease, hypertension, a 2-pack-per-day smoking habit, and alcohol abuse (12 drinks per day). His physical examination was remarkable for an irregular heart rate of 124 beats/min, temperature of 38.4°C, and mild abdominal distention and tenderness, but no signs of peritonitis. His white blood cell count was  $20.1 \times 10^3 \mu\text{L}$

From the Department of Surgery, The Mercy Hospital of Pittsburgh, Pittsburgh, Pa.

and his sodium level was 119 mEq/L. Plain abdominal x-ray films were nonspecific.

Following aggressive fluid resuscitation and initiation of ampicillin-sulbactam and gentamycin, a computed tomographic (CT) scan of the abdomen (**Figure 1**) was obtained. Due to the retrogastric air-filled cavity seen on CT, he underwent celiotomy. The findings are shown in **Figure 2**.

### What is the Diagnosis?

- A. Foramen of Winslow hernia
- B. Duodenal diverticulum
- C. Infected pancreatic pseudocyst
- D. Perforated gastric ulcer
- E. Intestinal duplication cyst

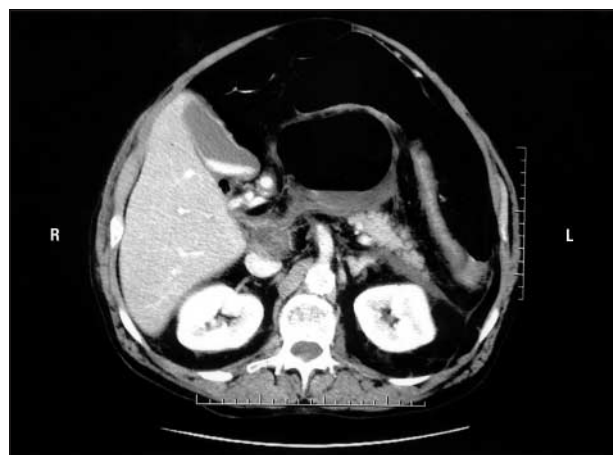


Figure 1.

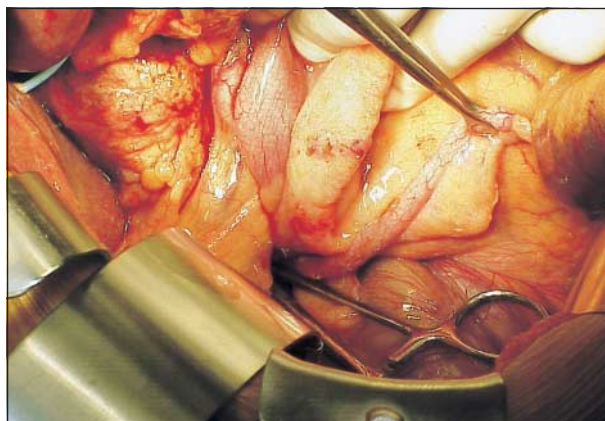


Figure 2.