

# Relapse and Morbidity in Patients Undergoing Sentinel Lymph Node Biopsy Alone or With Axillary Dissection for Breast Cancer

D. Kay Blanchard, MD, PhD; John H. Donohue, MD; Carol Reynolds, MD; Clive S. Grant, MD

**Hypothesis:** Axillary relapse in node-negative patients staged with sentinel lymph node (SLN) biopsy alone is no more frequent than in patients treated with standard axillary dissection. Morbidity is less for patients who had SLN biopsy.

**Design, Setting, and Patients:** Between October 14, 1997, and August 31, 2001, 1253 consecutive women with primary invasive breast cancer were prospectively entered into an SLN biopsy database. Completion axillary dissection was performed in 164 patients after SLN biopsy as part of a training protocol.

**Interventions:** Patients were contacted by questionnaire or telephone to determine breast cancer relapse; presence of arm lymphedema, arm pain, axillary infection, or seroma formation; and tumor recurrence or death.

**Main Outcome Measures:**  $\chi^2$  or Fisher exact tests and Wilcoxon rank sum tests were used to analyze categorical and continuous variables. Logistic regression was used to analyze morbidity.

**Results:** Of 1253 women, 894 (71%) were node negative by SLN biopsy alone (n=730 [82%]) or SLN biopsy and completion axillary dissection (n=164 [18%]). Questionnaires were completed by 776 patients (87%). Mean  $\pm$  SD follow-up was 2.4  $\pm$  0.9 years. Patients with axillary dissections reported a significantly higher occurrence of arm lymphedema (34%), arm pain (38%), seroma formation (24%), and infection (9%) vs SLN biopsy-only patients (6%, 14%, 7%, and 3%, respectively). One axillary relapse (0.1%) occurred during follow-up of 685 women who underwent SLN biopsy only.

**Conclusions:** With intermediate-term follow-up, there was 1 axillary recurrence in 685 SLN node-negative women, supporting use of SLN biopsy as an accurate method for staging breast cancer. Biopsy of the SLN was associated with significantly less morbidity than completion axillary dissection.

*Arch Surg.* 2003;138:482-488

**A**XILLARY LYMPH node metastasis in patients with early breast cancer is the most important prognostic indicator for recurrence and survival.<sup>1-3</sup> However, axillary lymph node dissection (ALND) is associated with acute complication rates of 20% to 55%, including lymphedema, sensory nerve damage, hemorrhage, and seroma formation, and chronic lymphedema rates of 7% to 56%.<sup>4-6</sup>

Many studies support the concept that a sentinel lymph node (SLN) is the first lymph node to receive lymphatic drainage from a primary breast cancer and the node most likely to contain metastatic cells. Focused histopathologic examination of these 1 or more SLNs can stage an early breast cancer and has been shown to be accurate in 93% or more of patients, particularly when blue dye and radiocolloid are used in combination.<sup>7-14</sup>

Biopsy of the SLN can also be performed with less of the associated morbidity of ALND because of less disruption of the axillary space.<sup>15</sup>

In some medical centers, including the Mayo Clinic, SLN biopsy has replaced ALND for patients in whom the SLN(s) is negative for metastasis. If the SLN is determined to be negative on frozen section during the original operation, further ALND is not completed. However, if metastatic disease is subsequently detected in the SLN by permanent section, a standard completion axillary dissection is often recommended to fully evaluate the extent of lymph node involvement for staging purposes and regional control of disease.

Although SLN biopsy has been shown to be efficacious in several studies for patients with newly diagnosed breast cancer, long-term follow-up of these patients is scarce. Giuliano et al<sup>16</sup> reported

From the Departments of Surgery (Drs Blanchard, Donohue, and Grant) and Pathology (Dr Reynolds), Mayo Clinic, Rochester, Minn.

**Table 1. Patient Demographics\***

Type of Dissection	Women, No. (N = 1253)	Age, y	Tumor Size, cm	SLNs, No.	Positive SLNs, No.	Axillary Nodes, No.	Positive Axillary Nodes, No.
Negative nodes							
Negative SLN	730	60.6 ± 12.8	1.3 ± 0.9	2.3 ± 1.3	0	NA	NA
Negative SLN + ALND	164	60.4 ± 12.5	1.5 ± 1.0	1.8 ± 1.0	0	12.6 ± 11.1	0
Positive nodes							
Delayed positive SLN†	125	57.5 ± 13.1	1.9 ± 1.4	2.2 ± 1.8	1.2 ± 0.4	17.3 ± 12.6	0.2 ± 0.5
Positive SLN	224	56.3 ± 13.6	2.6 ± 2.1	2.2 ± 1.4	1.3 ± 0.7	18.4 ± 9.7	1.8 ± 3.5
False-negative SLN	10	61.5 ± 14.8	1.9 ± 1.2	2.0 ± 2.2	0	10.9 ± 12.2	2.7 ± 4.4

Abbreviations: ALND, axillary lymph node dissection; NA, not applicable; SLN, sentinel lymph node.

\*Data are given as mean ± SD.

†Sentinel lymph nodes were negative by frozen section but positive by hematoxylin-eosin stain or immunohistochemical analysis (30.4% detected by immunohistochemical analysis alone).

the follow-up of 125 patients who underwent SLN biopsy for node-negative breast cancer, showing no recurrence of axillary metastasis during the study (median, 39 months) and negligible complication rates compared with axillary dissection. In the present study, the SLN database included women who underwent SLN biopsy with or without ALND for invasive breast cancer between October 14, 1997, and August 31, 2001, with no metastatic tumor found in either the SLN(s) or axillary nodes.

## METHODS

Consecutive women with early-stage invasive breast carcinoma with clinically negative nodes were entered into our database between October 14, 1997, and August 31, 2001. After an initial phase using blue dye only to localize the SLN(s), we adopted the use of radiocolloid and blue dye for optimal results. The techniques used are briefly described in the following subsections.

### RADIOCOLLOID

On the morning of surgery, the patient underwent lymphoscintigraphy. Briefly, in a volume of 0.4 mL, 0.4 mCi (14.8 MBq) of technetium Tc-99m sulfur colloid was injected intradermally either directly anterior to the tumor or along the upper outer aspect of the nipple-areolar complex. Scans were obtained to demonstrate the location of the first-draining axillary node(s), and the position of these nodes was marked with the aid of a handheld gamma probe.

### ISOSULFAN BLUE DYE

Two to 5 mL of isosulfan blue were injected subdermally along the upper outer aspect of the tumor cavity after the tumor had been excised or adjacent to the nipple-areolar complex. Approximately 7 to 15 minutes after injection, a curvilinear incision was made under the axillary hairline, and exploration for blue-stained, radioactive nodes was undertaken. If a mastectomy was performed, the lateral aspect of the mastectomy incision was opened and exploration into the axilla was conducted for blue-stained, radioactive nodes.

### FOLLOW-UP

We contacted patients with negative SLN biopsy findings by survey letter and questionnaire for follow-up information. Also included in this study were women who had SLN biopsy followed by ALND to compare recurrence and morbidity rates of

the procedures. Institutional review board approval was obtained for this study. Of 1253 consecutive patients, 730 had negative SLN biopsy findings and 164 women had negative findings on SLN biopsy with ALND. Node-negative patients were mailed the survey letter inviting them to participate in the study. Patients who did not initially return the survey letter were mailed a second letter or were contacted by telephone. Patient medical records were also reviewed for local or distant recurrences or death.

## STATISTICAL ANALYSIS

Patient and tumor characteristics such as age at diagnosis, estrogen receptor and progesterone receptor status, grade, stage, tumor size, and histologic features were collected. For each continuous variable, either the Wilcoxon rank sum test or the 2-sample Z test was used to assess whether there was a significant association between that variable and type of operation (SLN biopsy vs ALND). For dichotomous variables, the Fisher exact test was used. Disease-free survival was defined as the time from surgery to local or distant recurrence (excluding local in-breast recurrence or ipsilateral axillary tumor recurrence) or death without a documented recurrence. Survival was defined as the time from surgery to death due to breast cancer. Patients who died of other causes are not included in these analyses. The distribution of disease-free survival times and survival times was estimated using the Kaplan-Meier method.

## RESULTS

The Mayo Clinic evaluation of SLN biopsy for patients with invasive breast cancer was initially performed as an institutional review board-approved training protocol during which isosulfan blue was used for SLN localization. An ALND was then performed in all cases after SLN biopsy to evaluate the sensitivity and specificity of this study. After completing the protocol and when individual surgeons had acquired sufficient experience, SLN biopsy alone was performed if no nodal metastases were detected on histologic evaluation of the SLN. During our initial experience, 1 or more SLNs were successfully identified in 663 (98%) of 675 patients. In the total group of 1253 patients entered into the SLN database between October 14, 1997, and August 31, 2001, a false-negative rate of 2.8% was determined (**Table 1**). False-negative dissections were more frequent in the early training phase of this study, during which patients with worrisome palpable nodes were included in the SLN protocol.

**Table 2. Tumor and Treatment Characteristics of 776 Patients Completing a Follow-up Survey**

Variable	SLN Biopsy Only	SLN Biopsy + ALND	P Value
Age, mean ± SD, y	61.6 ± 12.5	58.3 ± 11.6	.03
Mastectomy	202/685 (30)	20/91 (22)	.14
Chemotherapy	161/631 (26)	28/84 (33)	.13
Radiation treatment	439/665 (66)	67/89 (75)	.08
ER positive	529/625 (85)	75/88 (85)	.89
PR positive	512/625 (82)	76/88 (86)	.32
Stage			
0	36/682 (5)	0/94	.01
I	535/682 (78)	68/90 (77)	
II	104/682 (15)	21/90 (23)	
III	5/682 (1)	1/90 (1)	

Abbreviations: ALND, axillary lymph node dissection; ER, estrogen receptor; PR, progesterone receptor; SLN, sentinel lymph node.

\*Data are given as number (percentage) except where indicated otherwise.

Of the 776 patients for whom follow-up information was obtained, 685 underwent SLN biopsy only and 91 underwent SLN biopsy with ALND. Before analysis of primary outcomes and end points, the 2 groups were compared based on age, year of surgery, mastectomy vs lumpectomy, estrogen receptor and progesterone receptor status, grade, and stage of tumor. The 2 groups showed significantly different distributions for age ( $P = .03$ ), year of surgery ( $P < .001$ ), and stage ( $P = .01$ ). Demographic, tumor, and treatment characteristics are given in **Table 2**. The type of axillary operation according to year performed is given in **Table 3**.

Univariate and multiple logistic regression were used to analyze the following outcomes: lymphedema of the arm, seroma formation, infection, and arm pain (**Table 4**). Of those who responded to the survey question about lymphedema, 39 (6%) of 683 patients who underwent SLN biopsy only reported experiencing lymphedema compared with 31 (34%) of 91 patients who underwent ALND ( $P < .001$ ). Of 39 patients reporting lymphedema in the SLN biopsy only group, 34 (5%) described it as mild or moderate, and 4 (0.6%) reported severe lymphedema, as defined by needing to use a special sleeve some or all of the time. Of the 31 patients reporting lymphedema in the ALND group, 8 (9%) described it as severe and 23 (25%) as mild or moderate.

Of women who responded to the survey question about arm pain, 95 (14%) of 681 patients who underwent SLN biopsy only reported pain in the arm on the side where they had surgery compared with 35 (38%) of 91 patients who underwent ALND ( $P < .001$ ). Of 95 patients who underwent SLN biopsy alone and reported pain, 86 (13%) had mild or moderate pain and 6 (0.9%) had severe pain, requiring pain medication beyond 1 month after surgery. Of 35 patients reporting pain after ALND, 30 (33%) had mild or moderate pain and 4 (4%) had severe pain.

Of survey respondents, 50 (7%) of 681 who underwent SLN biopsy only reported fluid collection that needed to be drained compared with 21 (24%) of 89 who underwent ALND. Whether a patient had a complete axillary dissection was a significant predictor of seroma formation ( $P < .001$ ). This difference remained significant

in a multivariate model adjusting for age, whether the patient had a mastectomy, and tumor stage ( $P < .001$ ).

There was also an association between axillary infection and ALND. In the SLN biopsy group, 20 (3%) of 681 women had an infection that was drained, needed antibiotic therapy, or both, and 8 (9%) of 88 women who underwent ALND experienced this morbidity ( $P = .006$ ).

The 2 groups were also assessed for an association of lymphedema or pain with adjuvant radiation treatment, since this treatment also has its own constellation of associated morbidities. There were 52 (10%) of 505 patients who complained of lymphedema who also had adjuvant radiation treatment to the breast or chest wall, axilla, or both. This was not significantly different from 18 (7%) of 247 patients who reported lymphedema but did not have radiation treatment ( $P = .18$ ). Similarly, 81 (16%) of 504 patients reported pain and had radiation treatment compared with 44 (17%) of 245 patients with pain but no radiation treatment ( $P = .52$ ).

Patients were also surveyed on the duration of staining of the breast tissue after injection of isosulfan blue dye. Overall, 712 (92%) of 776 patients had isosulfan blue dye used as part of the SLN localization protocol. Of these women, 45 (6%) reported that the dye still had not faded at the time of the survey (median, 24 months; range, 15-53 months). For the 314 patients (44%) who reported that their dye had faded, the median number of months noted was 1 (range, 0-32 months).

Of the node-negative patients included in this study, 8 died of metastatic breast cancer. Six patients had undergone SLN biopsy only and 2 had undergone SLN biopsy with completion axillary dissection. The median time to death was 28 months (range, 7-46 months) from the time of the initial breast/axillary surgery. Eight patients developed distant metastases during follow-up (3 ultimately died of disease and 5 were alive with disease at the time of the survey). The median time to diagnosis of distant disease was 23 months (range, 13-46 months). Locally recurrent disease was seen in 6 patients: 5 had in-breast or chest wall recurrences and 1 had an axillary recurrence. The median time to local-regional recurrence was 30 months (range, 4-49 months). The patient with axillary disease had undergone mastectomy and SLN biopsy, with 2 negative nodes confirmed by hematoxylin-eosin staining and immunohistochemical (IHC) analysis. The patient received adjuvant chemotherapy. An axillary mass was noted 41 months after the initial operation and was surgically excised, revealing a metastatically involved low axillary lymph node. Nineteen other axillary nodes removed at that time were negative for tumor. To date, this represents the only clinical axillary failure after SLN biopsy of 685 surveyed patients who had received SLN biopsy alone. This calculated to be a clinical false-negative rate of 0.1%.

#### COMMENT

Sentinel lymph node biopsy has become an accepted method of staging breast cancer in many institutions, validated by false-negative rates of 5% or less with completion axillary dissection.<sup>12,16-18</sup> Before introducing the technique into clinical practice at the Mayo Clinic, a training

**Table 3. Distribution of Type of Operation by Year\***

Operation	Year					Total
	1997	1998	1999	2000	2001	
SLN biopsy only	2 (<1)	7 (1)	150 (22)	303 (44)	223 (33)	685
SLN biopsy + ALND	10 (11)	55 (60)	20 (22)	3 (3)	3 (3)	91
<b>Total</b>	<b>12 (2)</b>	<b>62 (8)</b>	<b>170 (22)</b>	<b>306 (39)</b>	<b>226 (29)</b>	<b>776</b>

Abbreviations: ALND, axillary lymph node dissection; SLN, sentinel lymph node.

\*Data are given as number (percentage).

protocol was conducted. Using only isosulfan blue dye, SLNs were identified in 92% of patients, with a false-negative rate of 6%, verified by ALND in all patients. By adding preoperative lymphoscintigraphy, intraoperative gamma probe localization of the SLN(s), disallowing SLN biopsy in patients with palpably worrisome axillary adenopathy, and including intraoperatively discovered worrisome nodes as SLNs, our immediate false-negative rate was reduced. Only 3 completion ALNDs were performed after a negative SLN biopsy finding after August 31, 2000. Because of this, there was a longer median follow-up time for patients with ALND in this study compared with those having SLN biopsy alone. However, longer-term follow-up information for local-regional recurrences has been limited. In addition, the potential advantages of SLN biopsy, regarding the established morbidities of ALND, have not been extensively documented. The aims of this study were 2-fold: to determine the intermediate-term axillary relapse rate and to compare the morbidity rates of both procedures.

Arm lymphedema was reduced in this study from 34% in patients who underwent ALND to 6% in patients who underwent SLN biopsy only. Furthermore, severe lymphedema, which we defined as requiring compression sleeves, was similarly reduced from 9% in ALND patients to less than 1% in patients who underwent SLN biopsy. Although these percentages are based on patient self-assessment, and not on formal volumetric or arm circumference measurements, the differences are striking. Because 75% of arm edema will be evident within 1 year of ALND,<sup>19</sup> we believed that our minimum follow-up of 1 year would reasonably reflect morbidity rates of both groups of patients. A subset of our patients (those operated on between October 14, 1997, and August 31, 2000) were sent 2 surveys, one in April 2001 and a second in September 2002. The mean  $\pm$  SD follow-up of this group of patients was  $3.0 \pm 0.8$  years. Of the 39 women who reported lymphedema in the first survey, 24 (63%) reported persistent lymphedema and 14 (37%) reported resolution of arm swelling at the time of the second survey. Of the 24 women who reported lymphedema on both surveys, 2 reported increased severity, 2 reported decreased severity, and the remainder had no change in symptoms. There were no significant changes in lymphedema scores in patients with either SLN biopsy or ALND. The literature emphasizes the alarming frequency of arm complaints in patients having axillary lymphadenectomy as part of their definitive breast surgery. In a study by Maunsell et al,<sup>3</sup> 82% of respondents had at least 1 arm problem 3 months after surgery, with self-reported symptoms of swelling, weakness, limi-

**Table 4. Responses to Survey Questions by Type of Operation**

Variable	SLN Biopsy Only	SLN Biopsy + ALND	Univariate P Value†
Lymphedema	39/683 (6)	31/91 (34)	<.001
Mild/moderate	34/683 (5)	23/91 (25)	
Severe	4/683 (0.6)	8/91 (9)	
Pain	95/681 (14)	35/91 (38)	<.001
Mild/moderate	86/681 (13)	30/91 (33)	
Severe	6/681 (0.9)	4/91 (4)	
Seroma	50/681 (7)	21/89 (24)	<.001
Infection	20/681 (3)	8/88 (9)	.006

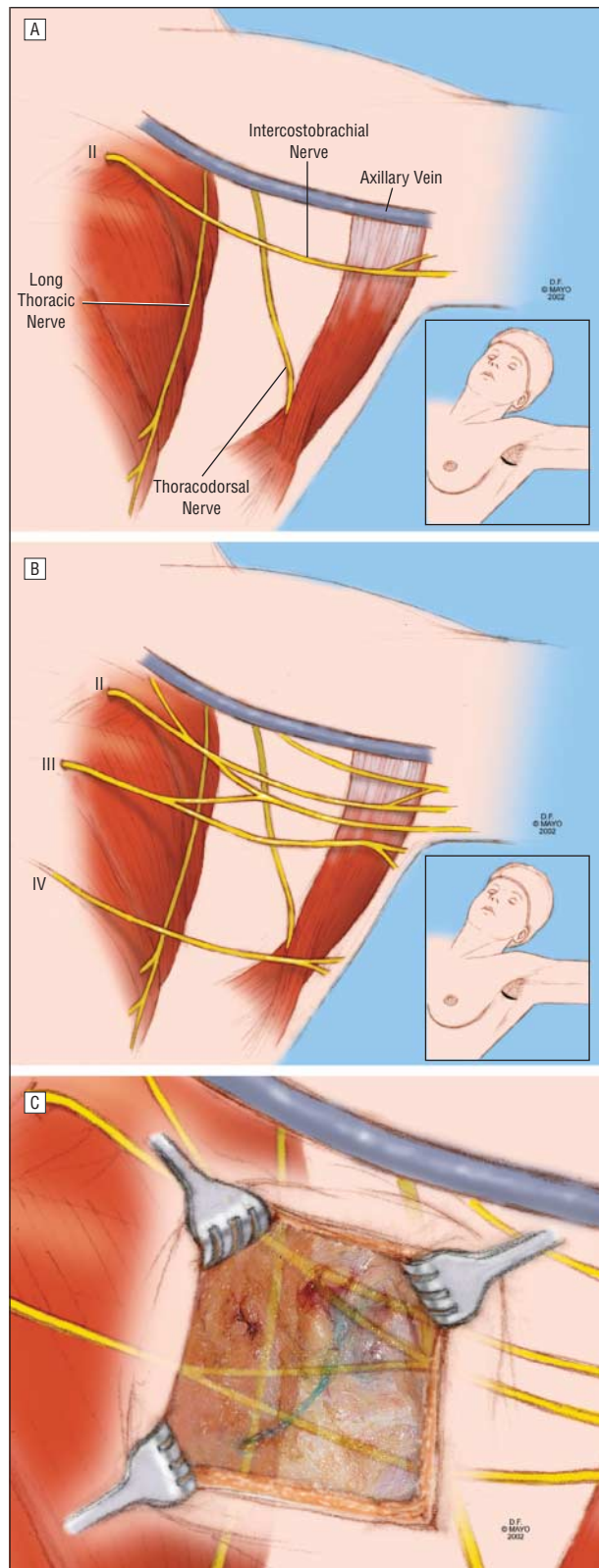
Abbreviations: ALND, axillary lymph node dissection; SLN, sentinel lymph node.

\*Data are given as number (percentage).

†Logistic regression.

tation of arm movement, pain, and numbness. Lymphedema is a well-known, and perhaps the most feared, complication of axillary dissection, with prevalences ranging from 10% to 40%.<sup>4,7,15,20-22</sup> Superficial lymphatics from the upper extremity ultimately coalesce into a medial bundle of 3 to 4 trunks that traverses the axillary space, which is vulnerable to disruption during ALND.<sup>19</sup> A smaller lateral bundle follows the deltopectoral groove, farther from operative danger, and may have connections with the medial bundle, thereby protecting the extremity from subsequent lymphedema if the medial bundle is occluded. The technique of SLN biopsy, by minimizing the potential of disrupting the medial bundle, reduces the risk of arm lymphedema.

The most commonly reported morbidity in the present study was subjective arm pain, which was present in 33% of our ALND patients but in only 14% of those who received SLN biopsy only. In the initial survey, 82 of 396 patients reported arm pain. However, 37 of the patients (45%) reported that the pain had resolved by the second survey. Similar decreases were reported for the SLN biopsy and ALND groups. Ivens et al<sup>23</sup> reported frequencies of 70% for numbness and 33% for arm pain. Similarly, Warmuth et al<sup>24</sup> reported numbness in 35% of patients and pain in 30%, whereas Maunsell et al<sup>3</sup> reported arm pain in 55%. Less attention has been focused on preventing arm pain, as classic descriptions of axillary dissection rarely protect the cutaneous nerves traversing the axilla (**Figure**). The intercostobrachial nerve is only 1 of as many as 4 cutaneous nerves that are at risk, including the medial brachial cutaneous and branches of the third and fourth intercostal nerves. These are of-



A, Classically described axillary anatomy. B, Commonly encountered axillary anatomy with multiple interconnecting cutaneous nerves (intercostal nerves II-IV) traversing the axilla. C, Axillary sentinel lymph node biopsy picture superimposed on graphic representation of the axillary anatomy demonstrating the vulnerability to damage of the cutaneous nerves.

ten imbedded in the axillary adipose tissue located superficially, in contrast to the deeply located motor nerves

of the serratus anterior and the latissimus dorsi muscles. With heightened awareness of this complication of arm pain and even closer attention to protecting these nerves, the frequency of this problem can be reduced, especially in patients undergoing SLN biopsy only.

An important step in the validation of SLN biopsy for the staging and management of breast carcinoma is determining the clinical axillary recurrence rate in node-negative patients who do not have completion axillary dissections performed. Several studies<sup>16,25-28</sup> have reported nodal recurrences of 0% to 1.4%, with mean follow-up of 22 to 39 months. In the present study, there was 1 axillary relapse in 685 SLN-negative women (0.1%). This failure was noted 41 months after surgery. Our current method of evaluating sentinel nodes for metastatic cells combines thin sectioning of the node and IHC analysis. Several studies<sup>29-31</sup> have shown that IHC analysis can upstage breast cancer in 10% to 20% of cases. Only patients shown to be node negative by IHC analysis and serial sections were included in this study. This careful pathological evaluation likely contributed to the low clinical false-negative rate seen, adding support for the use of IHC analysis in the histologic examination of sentinel nodes.

Lymphadenectomy has served as the traditional method of choice for the axillary staging of breast cancer. However, this procedure is commonly associated with postoperative morbidity, particularly lymphedema and arm pain. The present study demonstrated significantly decreased rates of both complications, plus a minimal prevalence of axillary relapse, in patients who underwent SLN biopsy only compared with those who underwent SLN biopsy plus ALND. These data provide strong support for SLN biopsy as the staging method of choice for patients with clinically node-negative breast cancer.

Accepted for publication December 22, 2002.

This study was presented at the 110th Scientific Session of the Western Surgical Association, Vancouver, British Columbia, November 19, 2002, and is published after peer review and revision. The discussions that follow this article are based on the originally submitted manuscript and not the revised manuscript.

We thank Tanya Hoskins, MS, and Scott Harmsen, MS, of the Statistics Center, Mayo Clinic, for their statistical analyses of these data and Anne Harris, BA, of the Survey Center, Mayo Clinic, for her assistance in obtaining follow-up information.

Corresponding author and reprints: Clive S. Grant, MD, Mayo Clinic, 200 First St SW, Rochester, MN 55905 (e-mail: cgrant@mayo.edu).

## REFERENCES

1. Carter CL, Allen C, Henson DE. Relation of tumor size, lymph node status, and survival in 24,740 breast cancer cases. *Cancer*. 1989;63:181-187.
2. Fisher ER, Sass R, Fisher B. Pathologic findings from the National Surgical Adjuvant Project for Breast Cancers (protocol no. 4). *Cancer*. 1984;53:712-723.
3. Maunsell E, Brisson J, Deschenes L. Arm problems and psychological distress after surgery for breast cancer. *Can J Surg*. 1993;36:315-320.
4. Ivins D, Hoe AL, Podd TJ, et al. Assessment of morbidity from complete axillary dissection. *Br J Cancer*. 1992;66:136-138.
5. Kissin MW, Querci della Rovere G, Easton D, et al. Risk of lymphoedema following the treatment of breast cancer. *Br J Surg*. 1986;73:580-584.

6. Gerber L, Lampert M, Wood C, et al. Comparison of pain, motion, and edema after modified radical mastectomy vs local excision with axillary dissection and radiation. *Breast Cancer Res Treat.* 1992;21:139-145.
7. Krag DN, Weaver DL, Ashikaga T, et al. The sentinel node in breast cancer: a multicenter validation study. *N Engl J Med.* 1998;339:941-946.
8. Giuliano AE, Kirgan DM, Guenther JM, et al. Lymphatic mapping and sentinel lymphadenectomy for breast cancer. *Ann Surg.* 1994;220:391-401.
9. Borgstein PJ, Meijer S, Pijpers R. Intradermal blue dye to identify sentinel lymph node in breast cancer. *Lancet.* 1997;349:1668-1669.
10. Giuliano AE, Jones RC, Brennan N, Statman R. Sentinel lymphadenectomy in breast cancer. *J Clin Oncol.* 1997;15:2345-2350.
11. Alex JC, Krag DN. Gamma probe-guided localization of lymph nodes. *Surg Oncol.* 1993;2:137-143.
12. Veronesi U, Paganelli G, Galimberti V, et al. Sentinel-node biopsy to avoid axillary dissection in breast cancer with clinically negative lymph nodes. *Lancet.* 1997;349:1864-1867.
13. Albertini JJ, Lyman GH, Cox C, et al. Lymphatic mapping and sentinel node biopsy in the patient with breast cancer. *JAMA.* 1996;276:1818-1822.
14. Reynolds C, Mick R, Donohue JH, et al. Sentinel lymph node biopsy with metastasis: can axillary dissection be avoided in some patients? *J Clin Oncol.* 1999;17:1720-1726.
15. Schrenk P, Rieger R, Shamiyeh A, Wayand W. Morbidity following sentinel node biopsy versus axillary lymph node dissection for patients with breast carcinoma. *Cancer.* 2000;88:608-614.
16. Giuliano AE, Haigh PI, Brennan MB, et al. Prospective observational study of sentinel lymphadenectomy without further axillary dissection in patients with sentinel node-negative breast cancer. *J Clin Oncol.* 2000;18:2553-2559.
17. McMasters KM, Tuttle TM, Carlson DJ, et al. Sentinel lymph node biopsy for breast cancer: a suitable alternative to routine axillary dissection in multi-institutional practice when optimal technique is used. *J Clin Oncol.* 2000;18:2560-2566.
18. Hill ADK, Tran KN, Akhurst T, et al. Lessons learned from 500 cases of lymphatic mapping for breast cancer. *Ann Surg.* 1999;229:528-535.
19. Pain SJ, Purushotham AD. Review: lymphedema following surgery for breast cancer. *Br J Surg.* 2000;87:1128-1141.
20. Burak WE, Hollenbeck ST, Zervos EE, et al. Sentinel lymph node biopsy results in less postoperative morbidity compared with axillary lymph node dissection for breast cancer. *Am J Surg.* 2002;183:23-27.
21. Petrek JA, Heelan MC. Incidence of breast carcinoma-related lymphedema. *Cancer.* 1998;83:2776-2781.
22. Ganz PA. The quality of life after breast cancer: solving the problem of lymphedema. *N Engl J Med.* 1999;340:383-385.
23. Ivens D, Hoe AL, Podd TJ, Hamilton CR, Taylor I, Royle GT. Assessment of morbidity from complete axillary dissection. *Br J Cancer.* 1992;66:136-138.
24. Warmuth MA, Bowen G, Prosnitz LR, et al. Complications of axillary lymph node dissection for carcinoma of the breast: a report based on a patient survey. *Cancer.* 1998;83:1362-1368.
25. Chung MA, Steinhoff MM, Cady B. Clinical axillary recurrence in breast cancer patients after a negative sentinel node biopsy. *Am J Surg.* 2002;184:310-314.
26. Schrenk P, Hatzl-Griesenhodfer M, Shamiyeh A, et al. Follow-up of sentinel node negative breast cancer patients without axillary lymph node dissection. *J Surg Oncol.* 2001;77:165-170.
27. Roumen RM, Kuijt GP, Liem IH, et al. Treatment of 100 patients with sentinel node-negative breast cancer without further axillary dissection. *Br J Surg.* 2001;88:1639-1643.
28. Veronesi U, Galimberti V, Zurrada S, et al. Sentinel lymph node biopsy as an indicator for axillary dissection in early breast cancer. *Eur J Cancer.* 2001;37:454-458.
29. Pendas S, Dauway E, Cox CE, et al. Sentinel node biopsy and cytokeratin staining for the accurate staging of 478 breast cancer patients. *Am Surg.* 1999;65:500-506.
30. Turner RR, Ollila DW, Krans DL, et al. Histopathologic validation of the sentinel lymph node hypothesis for breast carcinoma. *Ann Surg.* 1997;226:271-278.
31. Sabel MS, Zhang P, Barnwell JM, et al. Accuracy of sentinel node biopsy in predicting nodal status in patients with breast cancer. *J Surg Oncol.* 2001;77:243-246.

## DISCUSSION

Kelly McMasters, MD, Louisville, Ky: The authors should be congratulated for an important study. In this study, the rate of axillary nodal recurrence after a negative sentinel lymph node (SLN) biopsy was 0.1%, and SLN biopsy was associated with decreased morbidity compared with axillary dissection. I have a few questions:

1. In the paper you describe an injection technique that is somewhat different from other techniques that I have en-

countered. The radioactive colloid was, in some cases, injected *intradermally* just anterior to the tumor (as our group has recommended), but in others along the upper outer aspect of the nipple-areolar complex, regardless of tumor location. Similarly, the isosulfan blue dye was injected *subcutaneously* in the upper outer aspect of the nipple-areolar complex in some patients. In how many patients were these periareolar injection techniques performed? What is the rationale for this injection technique?

2. Do you think the relatively short follow-up period (mean, 2.4 years) is sufficient for detection of missed axillary nodal metastases?

3. It is interesting that 6% of patients who underwent SLN biopsy reported subjective lymphedema vs 37% of those who underwent axillary dissection. While these numbers seem high for what most of us would consider clinically meaningful lymphedema, it is clearly meaningful to the patients. Did the patients who had SLN biopsy only who reported lymphedema have an excessive number of SLNs removed? Furthermore, were there any differences in reported complications for patients who underwent mastectomy compared with breast conservation?

4. Finally, you recommend the use of immunohistochemistry (IHC) for evaluation of SLNs, and suggest that this contributes to a low false-negative rate. Over 35% of your positive SLNs were found only by IHC. As you know, the use of IHC for SLN biopsy has become very controversial because the clinical significance of micrometastases remains unproven. In some institutions, IHC has been shown to detect nodal micrometastases in 12% to 13% of patients with pure DCIS [ductal carcinoma in situ] (no microinvasion), which does not match the clinical reality that greater than 98% of such patients are cured without axillary dissection. Do you perform axillary dissection on all patients (even those with DCIS) who have IHC-detected micrometastases? Do the IHC findings affect the decision to give chemotherapy at your institution?

Jose M. Velasco, MD, Skokie, Ill: I only have the abstract, so I am sure that the manuscript might provide some of the answers. Something that I was curious about is the incidence of positive lymph nodes in the early vs delayed part of your study. Just looking at the slides, I can see that the number of completion axillary lymph node dissections appears to have decreased. Were the tumors similar early on to the ones later on? Second, 50% of patients who had completion axillary lymph node had negative lymph nodes. Were the nodes positive by H&E [hematoxylin-eosin]? By histochemistry? How many nodes were, as an average, obtained in the completion axillary lymph node dissection? Were there at least 10 of them? The issue with lymphedema raises a question of adjuvant therapy. Did the patients who had completion axillary lymph node dissection have radiation therapy? Do they have a higher incidence of lymphedema, which is what I would suspect? The issue with pain is a similar one. Where was the pain? Was the pain in the intercostal brachialis nerve distribution? Was the pain in the shoulder joint? Was the axilla radiated in those patients who had severe pain? Last, I would like to know whether you used any drains when an axillary dissection was performed or were any drains used ever?

David Winchester, MD, Evanston, Ill: We recorded our experience with our sentinel node biopsy population at Evanston Northwestern Healthcare and found that 3% of our patients had lymphedema if you carefully measured for it. So we believe as well that it is a real problem for these patients but much less so than for patients undergoing a complete axillary dissection. My question for the authors is, what are your recommendations for these patients after a sentinel node biopsy has been performed? Do you take any extra precautions with regard to exercises, or do they take precautions, for example, with air travel?

**David S. Robinson, MD, Kansas City, Mo:** I, too, am interested in those patients who developed lymphedema following sentinel lymph node biopsy. In extension of Dr McMasters' question regarding the number of nodes involved, can you tell us whether the radiation port included the axilla in those sentinel node–biopsied patients with lymphedema who would have had lumpectomy?

**James E. Goodnight, Jr, MD, PhD, Sacramento, Calif:**

An excellent paper and a remarkable result. Based on those results, do you consider this sentinel lymph node biopsy in breast cancer now an expectation of care? And I will avoid the question, do you consider it the standard of care?

**Claude H. Organ, Jr, MD, Oakland, Calif:** What is your training protocol? Would you define what you determine to be a sentinel node and whether or not the intercostals or Roter's nodes are considered sentinel nodes?

**Dr Grant:** Dr McMasters, regarding our injection techniques, over time they have evolved. Initially we injected both the radioactive tracer and the blue dye peritumorally in the breast tissue itself. Subsequently, based on yours and a number of other reports in the literature, it became clear that there were 2 factors that influence this. One is that we are mapping the lymphatics of the breast. We are not specifically trying to map lymphatics unique to a single tumor within that breast. The second is that the skin overlying the breast tissue follows the same lymphatic drainage as does the underlying breast parenchyma. So, utilizing these 2 facts as we learned them through the course of our experience with sentinel node dissection, we were able to inject the radioactive tracer intradermally utilizing the rapid spread just for practical reasons to shorten the period of time that the lymphatic drainage takes to get to the sentinel node. We don't do that with the blue dye because we want to avoid the blue tattooing that would occur with intradermal injections, so we inject it subcutaneously, but essentially it follows the same lymphatic pattern.

I don't have the specific numbers that we utilized each of these techniques throughout the course of the study. It's important to recognize, however, that the radioactivity and the blue dye regularly show up in the same lymph nodes.

The follow-up of nearly 2½ years is really not sufficient to identify all of the missed axillary nodal metastases, but we are very encouraged that at this point the frequency is only clinically 0.1%. I think your statement regarding the lymphedema is worth reemphasis. That is, whatever the amount of lymphedema reported, it's what the patient perceives that is important. It's interesting also that between the 2 survey letters that we sent out, in a third of the patients who originally said they had lymphedema, it had resolved by the time of the second survey. So what is clinically meaningful even at a month or 2 months may resolve at 6 to 8 months. There was no statistical difference in lymphedema between patients undergoing mastectomy and breast conservation.

Regarding the use of immunohistochemistry, the protocol that we follow is to use frozen section on the sentinel nodes the day of surgery at the time of the operation. The day after

the operation, we get H&E and immunohistochemistry results back. We don't count those as false negatives. It's only if we find that later on clinical follow-up or if a nonsentinel node is positive that that node would be a false negative. Nodes that were H&E negative but immunohistochemistry positive accounted for 11% of our total series.

The question of the implications of immunohistochemistry is a very good and timely one. We don't have an answer for what is the most appropriate care of patients whose nodes are positive only by immunohistochemistry. Whether we do a completion axillary dissection, utilize axillary radiation, or simply observe the patient is a difficult discussion right now and we individualize. Most of the time, if the node is IHC-positive only, we don't alter our treatment plans with regard to chemotherapy or radiation. We do struggle with that topic, and hopefully studies that are ongoing right now, including the ACOSOG Z-10 and -11, will give us definitive information.

In response to Dr Velasco's questions, the percentage of nodes positive did not change throughout the course of the study. We have roughly 28% nodes positive, and that occurred throughout the course of the entire study. The average number of sentinel nodes retrieved was 2.2. That obviously varies from 1 to as many as 6 or 7. The average number of nonsentinel lymph nodes removed in an axillary dissection is probably more a function of the diligence, at least in my opinion, of the pathology technician than it is so much the differing techniques in the axillary dissection. Roughly 10 to 20 nodes are removed. We did not have a statistical difference either in pain or lymphedema comparing those who did and did not have radiation. We don't have any specific recommendations regarding avoidance of lymphedema in the sentinel lymph node patients. This is a very small percentage, less than 1% have severe lymphedema, and I think it probably has to do with the degree of disruption that occurs during the occasional difficult sentinel lymph node, but we don't have statistics about that.

Regarding our training protocol, this was similar I am sure to what many others in the room have followed when first starting a program of sentinel node biopsy. Whether it is from melanoma or breast cancer or other organs, we dissect the sentinel node and then complete the appropriate lymph node basin dissection. In the breast it's the axillary nodes. We followed the protocol until we convinced ourselves of our accuracy. It took us about 160 patients to achieve this because we were doing this during a time when sentinel lymph node biopsy was first introduced. We had the surgeons, radiation oncologists, nuclear medicine, and the pathologists participating and eventually working smoothly to all of our satisfaction. Then we stopped doing axillary dissection. We were careful in that last slide and in the manuscript to state that the sentinel node biopsy technique is the preferred method of axillary staging. We intentionally stopped short of calling it the standard of care. It requires a multidisciplinary cooperation, and until the entire program is instituted appropriately and tested at individual institutions, and sufficient clinical experience is achieved by each surgeon, it can't really be considered a standard of care.