ORIGINAL ARTICLE

Are Solitary Breast Papillomas Entirely Benign?

Haim Gutman, MD; Jacob Schachter, MD; Nir Wasserberg, MD; Itzchak Shechtman, MD; Franklin Greiff, MD

Hypothesis: Solitary breast papillomas are potentially malignant and are associated with a higher risk of breast cancer.

Design: Retrospective review of all pathological reports containing breast papilloma (1983-2000) and review of selected specimens.

Setting: Tertiary, referral, university-affiliated medical center.

Participants: Ninety-five women with a breast specimen containing a papilloma or papillomatosis. Patients with overt papillary carcinoma without papilloma were excluded.

Intervention: All histopathological characteristics of the papilloma and the surrounding tissue were noted. The incidence of malignant and other proliferative histopathological findings were analyzed, comparing solitary ductal papilloma cases to multiple papilloma cases. The Fisher exact test and χ^2 test were applied for statistical analysis.

Main Outcome Measures: Surgical removal of solitary ductal papillomas should include margins wide enough to secure removal of any proliferative tissue within or around the papilloma and to enable thorough evaluation of the risk for future breast cancer.

Results: Solitary papillomas were associated with breast carcinoma in 7 patients (10%) in this series. An additional 9% (n=6) presented with invasive or noninvasive carcinoma within the papilloma. Atypical papilloma was noted in 6% of patients (n=4). The risk of associated malignancy was not significantly different between solitary ductal papilloma and multiple papilloma.

Conclusion: Increased risk of breast cancer is associated with all forms of papilloma.

Arch Surg. 2003;138:1330-1333

From the Departments of Surgery (Drs Gutman, Wasserberg, and Greiff), Oncology (Dr Schachter), and Pathology (Dr Shechtman), Rabin Medical Center, Beilinson Campus, Petah Tiqva, Israel, and Sackler School of Medicine, Tel Aviv University (Drs Gutman, Schachter, Shechtman, and Greiff), Tel Aviv, Israel.

PAPILLOMA IS identified in approximately 1% to 3% of all breast biopsy specimens.[1] Despite this relatively low occurrence rate, the significance of papilloma of the breast should not be underestimated. Although papillomas are generally perceived as a benign disorder, diverse findings in the literature have raised the possibility of a considerable potential for malignancy.

There are 2 major variants of papillomas of the breast: solitary ductal papilloma (SDP), which originates in the large ducts and is located centrally beneath the nipple, and multiple intraductal papilloma (MP), which is located in the terminal ducts at the periphery of the breast. Originally, SDP was considered benign and MP was considered to be potentially malignant.[2] However, Tavassoli and Norris[3] showed that SDP and MP may be a single aspect of the larger clinical picture of atypical ductal hyperplasia (ADH), which is itself a variant of low-grade ductal carcinoma in situ (DCIS). More recently, researchers showed that some forms of both SDP and MP increase the risk of invasive breast cancer.[4]

To determine whether papillomas are associated with a higher risk of developing breast cancer, we reviewed the pathological reports of all women with a diagnosis of papilloma of the breast in our institution during the past 20 years. We particularly sought those pathological findings that are known to increase the risk of breast cancer.

METHODS

We reviewed the computerized archives of the Department of Pathology, Rabin Medical Center, Petah Tiqva, Israel, a major tertiary care referral facility, for all breast biopsies conducted from January 1983 to October 2000 in which papilloma was either an isolated or an incidental finding. Overt papillary carcinomas without papillomas were excluded. The pathological reports were then carefully reviewed for morphological and pathological details of the papillary lesion and the surrounding tissue.

We paid special attention to the presence, relation, and location of proliferative and invasive disorders in either the papilloma itself or its close vicinity. The diagnosis of ADH was assigned to any proliferative lesion that fulfilled some but not all criteria for the diagnosis of DCIS. In addition, quantitative criteria

©2003 American Medical Association. All rights reserved.
Downloaded From: http://archsurg.jamanetwork.com/ on 05/01/2017

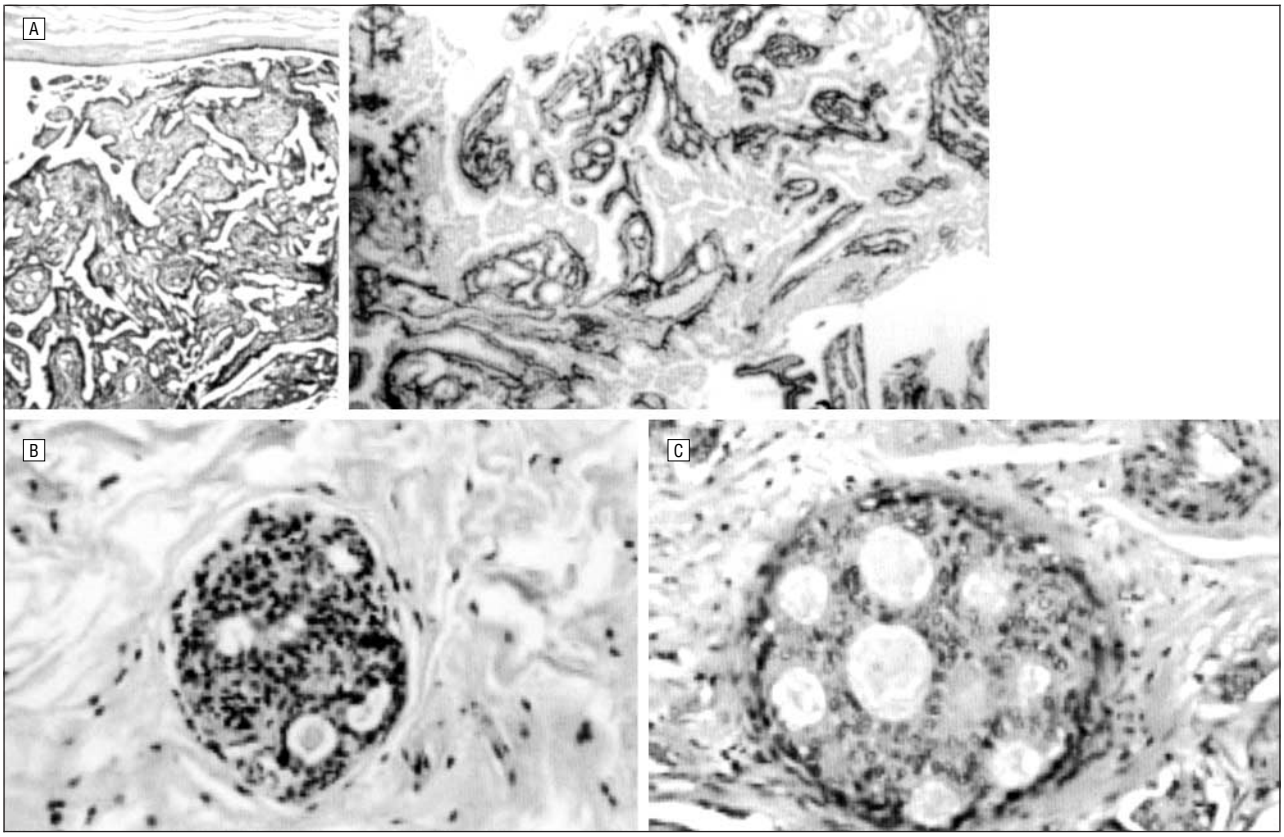

Demonstrative cases of atypical ductal hyperplasia, ductal carcinoma in situ (DCIS), and carcinoma within a papilloma. A, Carcinoma in papilloma (left; hematoxylin-eosin, original magnification ×40; right; immunostain smooth muscle actin, original magnification ×100). B, Atypical ductal carcinoma (hematoxylin-eosin, original magnification ×200). C, Low-grade DCIS (hematoxylin-eosin, original magnification ×200).

were used extensively; a low-grade DCIS limited to a single duct or to a few neighboring ducts in an area of 2 mm or less was considered ADH as well.[5] A diagnosis of carcinoma within a papilloma was assigned to carcinoma that arises in papillomas that retain areas of papilloma and that have foci of more cellular proliferation.[6] Demonstrative cases are depicted in the **Figure**. All specimens defined as carcinoma within papilloma were reviewed, and in any case of doubt, blocks were resectioned, stained, and evaluated.

The Fisher exact test and χ^2 test were used where applicable. $P \leq .05$ was considered statistically significant.

RESULTS

Ninety-five women with a breast specimen containing a papilloma or papillomatosis were identified. Ages ranged from 29 to 82 years (median age, 56 years). Twenty-six patients were younger than 50 years, and the rest were nearly equally divided in each of the sixth to ninth decades. Indications for surgery were as follows.

Indication	Patients, No. (%)
Palpable lump	44 (46)
Lump at nipple	18 (19)
Mammographic findings	16 (17)
Nipple discharge	12 (13)
Solitary cyst	5 (5)
Total	**95** (100)

Solitary ductal papilloma was diagnosed in 68 patients (72%). In 6 of them (9%), the papilloma was contained within a single cyst. Multiple intraductal papilloma was found in 27 patients (28%).

Papillomas (either SDP or MP) were associated with benign, hyperplastic, atypical, and carcinomatous histologic features (**Table**, Figure). Invasive carcinoma was detected in 7 patients (10%) with SDP. In 6 of them, the tumor was located close to the papilloma, and in 1, it was in the other breast. Another 6 patients (9%) had an invasive or noninvasive carcinoma that originated within the papilloma. Four solitary papillomas were defined as atypical. In 2, atypical papilloma was the only finding, 1 was a part of a DCIS specimen, and 1 was part of an invasive carcinoma. In the MP group, invasive carcinoma was found in 5 patients (18%); 3 of the lesions were papillary and 2 were ductal.

COMMENT

Purcell and Norris[7] claimed that ADH is a point in time when proliferating hyperplastic mammary epithelium begins to acquire histological and biological characteristics of DCIS. Therefore, its presence increases the risk of future development of invasive breast cancer by 4- to 5-fold. Accordingly, Tavassoli and Norris,[3] in their characterization of the histological changes in papilloma, defined lesions smaller than 3 mm as ADH and atypia larger than 3 mm as small DCIS. In 1985, Page et al[8] and Du-

©2003 American Medical Association. All rights reserved.
Downloaded From: http://archsurg.jamanetwork.com/ on 05/01/2017

Associated Pathological Findings by Type of Papilloma

Papilloma Type	No. (%) of Patients SDP	No. (%) of Patients MP	*P* Value
Fibrocystic changes and/or ductal hyperplasia	38 (56)	10 (37)	.10
Atypical hyperplasia	7 (10)	5 (18)	.28
Atypical papilloma	2 (3)	0	.51
DCIS	8 (12)*	7 (26)†	.09
Invasive carcinoma	7 (10)‡	5 (18)§	.28
Carcinoma arising within papilloma	6 (9)‖	0	.11
Total	**68** (100)	**27** (100)	. . .

Abbreviations: DCIS, ductal carcinoma in situ; MP, multiple intraductal papilloma; SDP, solitary ductal papilloma.

*One of 8 patients had atypical papilloma.

†Two of 7 patients had atypical hyperplasia.

‡Three of 7 patients had papillary carcinoma, 4 of 7 had ductal carcinoma, 4 of 7 had DCIS, and 1 of 7 had atypical papilloma.

§Two of 5 patients had ductal carcinoma, 3 of 5 had papillary carcinoma, 5 of 5 had atypical ductal hyperplasia, and 2 of 5 had DCIS.

‖Four of 6 patients had atypical ductal hyperplasia, 4 of 6 had carcinoma in situ, and 2 of 6 had carcinoma in situ with microinvasion.

pont and Page[9] showed that some proliferative disorders of the breast, including SDP, increase the risk of breast cancer by 2-fold. In a more recent study,[4] the same group demonstrated a 4-fold risk of invasive carcinoma in women with atypical SDP either in the papilloma itself or in the neighboring tissue. In patients without atypia, the risk remained relatively low. Ciatto et al[10] followed up 339 women with benign intraductal papillomas of the breast for an average of 6.6 years. Invasive breast cancer developed in 10 patients, which was more than expected on the basis of age-specific incidence rates. There were no differences in the rate of invasive breast cancer between women with SDP and those with MP.

In our series, as in others, intraductal papillomas seemed to be associated with other proliferative breast pathological features in 44% to 63% of cases. The pattern of association, however, differed somewhat between SDP and MP. Multiple intraductal papilloma was more frequently found in close vicinity to other proliferative disorders (or vice versa), but no malignant changes were detected in the papilloma itself. By contrast, SDP presented with neoplastic changes within the papilloma in 6 cases and with atypia in an additional 4. There were no statistically significant differences in the frequencies of the various proliferative disorders between SDP and MP.

These findings indicate that both MP and SDP are part of the spectrum of proliferative breast disorders and may be considered markers of higher risk. Patients with MP more frequently have associated histological features that predict an increased risk. In addition, SDP itself carries a potential for malignant transformation. There is also a group of patients in whom either SDP or MP is associated with only fibrocystic changes or benign hyperplasia and no atypia. This group is probably not at higher risk of developing cancer.

Our data and those of Page et al[8] and Dupont and Page[9] differ from those of Haagensen,[11] who approached SDP as a basically benign breast disease that requires minimal excision limited to the affected duct and MP as a potentially malignant entity that requires close follow-up. Of a series of 172 patients with SDP followed up for an average of 15 years, Haagensen[12] found only 8 patients who developed carcinoma of the breast (5 in the opposite breast and 3 in the same breast) within 6 to 11 years. By contrast, 6 of the 52 patients with MP developed ipsilateral invasive breast cancer after an average of 17 years, a rate 3.7 times higher than expected by life tables.[12] Similar findings were also reported by others,[13-15] including some surgical textbooks.[16,17]

There are 2 possible explanations for the discrepancies among the earlier and later studies. In the past, patients with large areas of atypia were considered to have either papillary carcinoma or DCIS and were treated with mastectomy.[18,19] Furthermore, during the 1970s and 1980s, screening mammograms were not performed as frequently,[20] and their resolution was poorer than today. This may have led to underdiagnosis of papilloma, ADH, and DCIS. Accordingly, some of Haagensen's patients might have been a selected group with SDP without atypia within the papilloma or neighboring tissue. These patients are at low risk of invasive cancer, according to our data as well.

The results of the present retrospective, histopathological study are weakened by the absence of clinical follow-up. Nevertheless, the analysis of all the papilloma specimens of a tertiary referral center throughout a 20-year period makes it possible to better define specific subgroups of patients and the cancer risk associated with each, as well as to further characterize papillomatous lesions.

We failed to find any statistically significant differences between MP and SDP with regard to the associated pathological conditions (Table). In both cases, the lesions that were associated only with fibrocystic changes or benign hyperplasia seemed to be at lower risk of cancer. This situation was more common for the SDPs ($P = .10$).

Approximately 35% of the patients with papillomatous lesions presented with concurrent cancer. The distribution of SDPs and MPs within this subgroup was not significantly different. It is noteworthy that ADH occurred more often in patients with MP and malignancy (7/12) than in patients with SDP with malignancy (4/21). Carcinoma within a papilloma was seen only in the patients with SDP.

In conclusion, our data indicate that papilloma of the breast, either solitary ductal or multiple, should be considered a risk factor for breast cancer. The risk is more prominent in the presence of atypical ductal or papillomatous hyperplasia. Solitary ductal papilloma is not an entirely benign entity and may undergo malignant transformation or be associated with atypia in or around it. Thus, surgeons must be careful to obtain a large enough sample of tissue around a papilloma or duct to eradicate the lesion and to estimate the risk in the individual patient of the presence or future development of invasive breast cancer. Close postbiopsy follow-up should be recommended.

Accepted for publication May 3, 2002.

Corresponding author: Haim Gutman, MD, Department of Surgery B, Rabin Medical Center, Beilinson Campus, Petah Tiqva 49100, Israel (e-mail: hgutman@post.tau.ac.il).

©2003 American Medical Association. All rights reserved.
Downloaded From: http://archsurg.jamanetwork.com/ on 05/01/2017

REFERENCES

1. Liberman L, Bracero N, Vuolo MA, et al. Percutaneous large core biopsy of papillary breast lesions. *AJR Am J Roentgenol.* 1999;172:331-337.
2. Kraus FT, Neubecker RD. The differential diagnosis of papillary tumours of the breast. *Cancer.* 1962;15:444-455.
3. Tavassoli FA, Norris TJ. A comparison of the results of long term follow-up for atypical intraductal hyperplasia and intraductal hyperplasia of the breast. *Cancer.* 1990;65:518-529.
4. Page DL, Salhany KE, Jensen RA, Dupont WD. Subsequent breast carcinoma risk after biopsy with atypia in breast papilloma. *Cancer.* 1996;78:258-266.
5. Rosen PP. Ductal hyperplasia. In: Rosen PP, ed. *Rosen's Breast Pathology.* 2nd ed. Baltimore, Md: Lippincott Williams & Wilkins; 2001:213.
6. Rosen PP. Papillary carcinoma. In: Rosen PP, ed. *Rosen's Breast Pathology.* 2nd ed. Baltimore, Md: Lippincott Williams & Wilkins; 2001:391.
7. Purcell CA, Norris HJ. Intraductal proliferation of the breast: a review of histologic criteria for atypical intraductal hyperplasia and ductal carcinoma in situ, including apocrine and papillary lesions. *Ann Diagn Pathol.* 1998;2:135-145.
8. Page DL, Dupont WD, Rogers LW, Rados MS. Atypical hyperplastic lesions of the female breast: a long term follow-up study. *Cancer.* 1985;55:2698-2708.
9. Dupont WD, Page DL. Risk factors for breast cancer in women with proliferative breast disease. *N Engl J Med.* 1985;312:146-151.
10. Ciatto S, Andreoli C, Cirillo A, et al. The risk of breast cancer subsequent to histologic diagnosis of benign intraductal papilloma follow-up study of 339 cases. *Tumori.* 1991;77:41-43.
11. Haagensen CD. Solitary intraductal papilloma. In: Haagensen CD, ed. *Disease of the Breast.* 3rd ed. Philadelphia, Pa: WB Saunders Co; 1986:138-175.
12. Haagensen CD. Multiple intraductal papilloma. In: Haagensen CD, ed. *Disease of the Breast.* 3rd ed. Philadelphia, Pa: WB Saunders Co; 1986:176-191.
13. Carter D. Intraductal papillary tumors of the breast: a study of 78 cases. *Cancer.* 1977;39:1689-1692.
14. Murad TM, Swaid S, Prichett P. Malignant and benign papillary lesions of the breast. *Hum Pathol.* 1977;8:379-390.
15. Ohuchi N, Abe R, Kasai M. Possible cancerous changes of intraductal papillomas of the breast: a 3-D reconstruction study of 25 cases. *Cancer.* 1984;54:605-611.
16. Iglehart DJ, Kaelin CM. Diseases of the breast. In: Townsend CM, Beauchamp DR, Evers MB, Mattox KL, eds. *Sabiston Textbook of Surgery.* 16th ed. Philadelphia, Pa: WB Saunders Co; 2001:555-590.
17. Greenall MJ. Benign conditions of the breast. In: Morris PJ, Malt RA, eds. *Oxford Text Book of Surgery, 1994.* Oxford, England: Oxford University Press; 1994: 789-808.
18. Haagensen CD. Papillary breast carcinoma. In: Haagensen CD, ed. *Disease of the Breast.* 3rd ed. Philadelphia, Pa: WB Saunders Co; 1986:729-757.
19. Haagensen CD. Intraductal breast carcinoma. In: Haagensen CD, ed. *Disease of the Breast.* 3rd ed. Philadelphia, Pa: WB Saunders Co; 1986:782-789.
20. Asch T, Haagensen CD. Mammography. In: Haagensen CD, ed. *Disease of the Breast.* 3rd ed. Philadelphia, Pa: WB Saunders Co; 1986:577-605.

Surgical Anatomy

The superior, middle, and inferior rectal or haemorrhoidal veins accompany their arteries and drain corresponding parts of the rectum and anal canal. The superior vein bcomes the inferior mesenteric vien and, therefore, belongs to the portal system. The middle and inferior veins are paired and belong to the caval system. The superior vein begins in the anal columna. It has extensive mucous and submucous plexuses, and it receives branches from the perirectal tissues. The middle rectal vein is a much more important vessel than the corresponding artery. It drains the rectum above the Internal Sphincter and communicates both submucously and perimuscularly with the inferior rectal vein, and it makes free anastomoses submucously with the superior rectal vein. Its branches communicate with the prostatic (vaginal and uterine) plexus. It is the chief link between the portal and caval systems, and it ends in the internal iliac vein. The inferior vein drains the anus and Sphincter Ani Externus.

Source: Boileau Grant JC. *A Method of Anatomy: Descriptive and Deductive.* 5th ed. Baltimore, Md: Williams & Wilkins Co; 1952:350.

©2003 American Medical Association. All rights reserved.
Downloaded From: http://archsurg.jamanetwork.com/ on 05/01/2017