

Completion Pancreatectomy for Postoperative Peritonitis After Pancreaticoduodenectomy

Early and Late Outcome

Sylvie Gueroult, MD; Yann Parc, MD, PhD; Françoise Duron, MD; Françoise Paye, MD, PhD; Rolland Parc, MD

Hypothesis: Completion pancreatectomy in patients with pancreatic leakage associated with postoperative peritonitis after pancreaticoduodenectomy is a viable salvage procedure.

Design: Retrospective analysis from a cohort of consecutive patients admitted between January 1, 1989, and December 31, 1999, for postoperative peritonitis originating from pancreaticojejunostomy leakage.

Setting: Tertiary referral center with surgical intensive care unit specializing in the treatment of intra-abdominal sepsis.

Patients: Eight consecutive patients with postoperative peritonitis originating from pancreaticojejunostomy after pancreaticoduodenectomy, with a mean Acute Physiology and Chronic Health Evaluation II score of 18.6. We excluded patients with pancreatic fistulas or abscesses amenable to percutaneous drainage or other conservative treatment.

Intervention: Completion pancreatectomy.

Main Outcome Measures: Mortality, morbidity, and long-term outcome, which was assessed by interview.

Results: Three patients died in the postoperative period: 2 required early reoperation during the postoperative period and died of hemorrhage and sepsis, and 1 died of multiorgan failure without reoperation. Recurrence of carcinoma was responsible for late death of 2 other patients.

Conclusions: Postoperative peritonitis after pancreaticoduodenectomy still has high mortality; however, completion pancreatectomy may represent the only means to achieve source control of infection in cases of postoperative peritonitis.

Arch Surg. 2004;139:16-19

WHIPPLE ET AL,¹ INSPIRED by the work of Kausch,² popularized the use of pancreaticoduodenectomy more than 65 years ago. Since then, operative mortality has been significantly reduced to about 5% in specialized centers.³⁻⁵ However, morbidity remains high, between 30%⁶ and 60%.⁷ Common complications include hemorrhage, intra-abdominal abscesses, and leakage of the anastomosis of the pancreatic remnant to the gastrointestinal tract. Mortality in patients with pancreatic anastomotic leakage is reported to be between 8% and 40%.^{5,8,9} Treatment of pancreatic anastomotic leakage depends on the presence or absence of peritonitis. Although leakage not associated with peritonitis can be treated medically combined with percutaneous drainage if necessary, this conservative approach is not possible for pancreatic leakage associated with peritonitis.

The prognosis in patients with postoperative peritonitis is linked to the ability to control the source of infection.¹⁰ In case of intestinal leakage, stomas are recognized as the gold standard treatment.¹⁰ When stomas are not possible, as for duodenal leakage, intubation with continuous intraluminal irrigation can be used.¹¹ However, for postoperative peritonitis originating from pancreaticojejunostomy, the pancreatic remnant cannot be pulled out through the skin or intubated for continuous intraluminal irrigation, and completion pancreatectomy is the only available treatment. We report our experience with completion pancreatectomy in patients with pancreatic leakage associated with postoperative peritonitis after pancreaticoduodenectomy.

METHODS

PATIENTS

From January 1, 1989, to December 31, 1999, 282 patients underwent a Whipple procedure

From the Departments of Digestive Surgery (Drs Gueroult, Y. Parc, Paye, and R. Parc) and Endocrinology (Dr Duron), Hôpital Saint-Antoine, Assistance Publique/Hôpitaux de Paris, Université Pierre et Marie Curie, Paris, France.

in our institution. Among these patients, 31 developed pancreatic fistulas that were conservatively managed and 7 developed postoperative peritonitis suspected on clinical grounds and confirmed at surgery. During the same period, 2 patients were referred to our institution for the treatment of postoperative peritonitis after a Whipple procedure. One of them was referred after 3 reoperations and died before reoperation at our institution, on the day of his admission. This study included the 7 patients initially operated on at our institution and the patient referred to us for treatment of postoperative peritonitis that could be operated on.

There were 2 women and 6 men, with a median age of 58.5 years (range, 45-70 years; mean \pm SD, 58.1 \pm 10.5 years). The pancreaticoduodenectomy was performed for adenocarcinoma of the pancreas (n=2), adenocarcinoma of the duodenum (n=1) or ampulla (n=3), chronic pancreatitis (n=1), and stage IV duodenal lesion of familial adenomatous polyposis classification¹² (n=1). During pancreaticoduodenectomy, the gross texture of the pancreas was described by the surgeon as normal in 7 patients and hard in 1 patient. The pancreatic duct was managed by nonintussuscepting pancreaticojejunostomy (n=7) and pancreaticogastrostomy (n=1). Partial portal vein resection followed by reconstruction was performed in 1 patient, and 1 other patient required dissection of the celiac trunk under intermittent vascular exclusion of 2 hours for extrinsic compression of the celiac trunk.

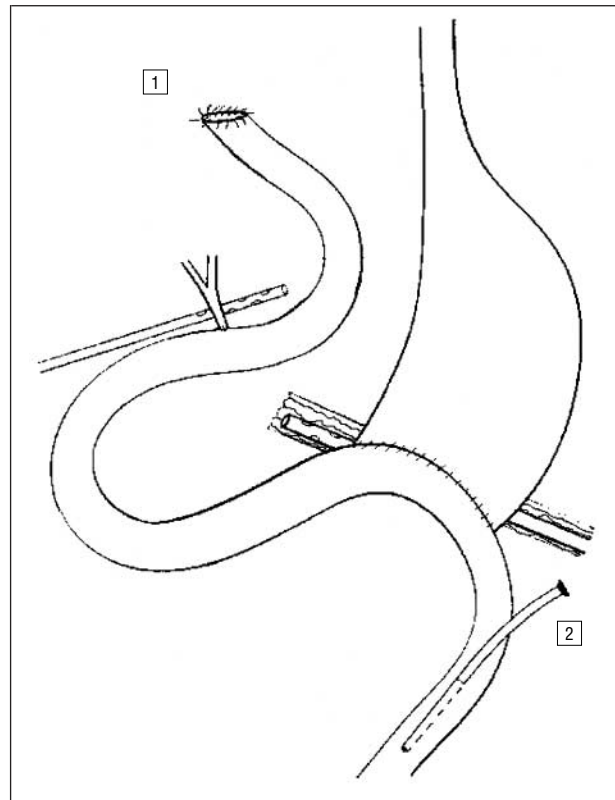
Medical comorbidity was present in 7 patients: cardiac disease (n=3), chronic respiratory insufficiency (n=1), familial adenomatous polyposis (n=1), alcoholism (n=1), and previous gastric resection for ulcer followed by a gastrojejunostomy (n=1).

Postoperative peritonitis in patients operated on at our institution was suspected with the appearance of fever (n=7) and abdominal tenderness (n=6). Failure of at least 1 organ was an indication for reoperation in 6 patients. The mean number of organs failed in these 6 patients was 2 (renal insufficiency, n=2; shock, n=5; liver failure, n=1; pulmonary deficiency, n=1). In 1 patient, operation was indicated because fluid was found in the peritoneal cavity on ultrasonography. The patient referred to our institution was in shock and required artificial ventilation.

The median time between the initial operation and treatment in this department was 6 days (range, 2-11 days). The referred patient was operated on the same day he was admitted (day 3 after initial operation). The mean \pm SD APACHE (Acute Physiology and Chronic Health Evaluation) II score,¹³ measured within 24 hours of operation for pancreatic leak associated with postoperative peritonitis, was 18.6 \pm 5.2 (median, 17.5; range, 12-28).

SURGICAL PROCEDURE

For all patients, peritonitis was confirmed during laparotomy. The surgical procedure included a laparotomy for complete exploration and lavage of the abdominal cavity, eradication of all sources of infection, drainage of dependent areas, jejunostomy for continuous enteral nutrition, and primary abdominal wound closure.¹⁴ The pancreatic remnant was ablated. The jejunal stump was pulled out as a stoma in 7 patients with leakage of a pancreaticojejunal anastomosis. The stomach was closed after edge excision in 1 patient with leakage of a pancreaticogastric anastomosis. A capillary Mikulicz drain was placed in the pancreatic area and/or in the Douglas pouch, depending on the local conditions. A Mikulicz packing (B. Braun Medical SA, Boulogne, France) was made of a gauze bag containing long gauze swabs and a 16F silicone tube and was placed with the following technique: The gauze bag was laid in the pancreas area or the pelvis. Then the gauze swabs were loosely packed into the bag; 3 to 5 swabs were usually required. The bag formed a vertical cylinder that was exteriorized through a 5-cm opening at the left extrem-



Gastrointestinal tract after completion pancreatectomy, showing stoma (1) and Witzel feeding jejunostomy placement (2).

ity of the chevron incision for pancreatic drainage and through a 5-cm median incision just above the pubis for pelvic drainage. Witzel jejunostomy was performed in the ileal loop immediately distal to the gastroenterostomy (**Figure**) or, in the patient with a gastropancreatic anastomosis, in the ileal loop immediately distal to the hepaticojejunostomy. The abdominal wall was primarily closed in a conventional manner or by exclusive cutaneous suture, depending on the abdominal wall tension.¹⁴

Parenteral nutrition was started as soon as possible and replaced by enteral nutrition through jejunostomy once the gastrointestinal ileus resolved.

The Mikulicz packing was left in an open appliance for 7 days, allowing for capillary drainage, or placed in a closed appliance with 100 mm Hg of suction applied on the drain. The exteriorized part of the packing was cleaned every day with oxygenated water. From day 8 onward, irrigation (1 L of isotonic sodium chloride solution plus 10 mL of povidone-iodine in 30 minutes) was performed daily through the silicone tube, in preparation for packing removal. The gauze swabs were removed at postoperative days 9 and 11, and the gauze bag itself at day 14. After removal, a 14F soft silicone tube was placed on the track for a mean of 5 days, allowing for daily irrigation (100 mL in 5 minutes).

Glycemia and capillary tests were performed during hospitalization, and diabetes was treated with regular insulin. Induced pancreatic exocrine insufficiency was treated with oral pancreatic enzymes when feeding started.

RESULTS

SURGICAL FINDINGS AND PROCEDURES

Surgical findings are detailed in the **Table**. Three patients had Mikulicz drainage, 1 in the Douglas pouch and

Patients and Operative Findings

Patient No./ Sex/Age, y	Reintervention (Operative Day)	Operative Findings	APACHE II	Follow-up Outcome
1/F/51	Completion pancreatectomy, splenectomy (11)	PJ leakage, peritonitis	16	Chronic enterocutaneous fistula of GJ (alive)
2/M/70	Completion pancreatectomy, splenectomy, Mikulicz packing (6)	PJ leakage, peritonitis, pancreatitis pancreatic necrosis*	19	Multivisceral failure not corrected with reintervention (early postoperative death)
3/M/64	Completion pancreatectomy, splenectomy (7)	PJ leakage, peritonitis, pancreatitis	16	Anastomotic recurrence of colon cancer, peritoneal carcinosis (late death)
4/M/70	Completion pancreatectomy, splenectomy, Mikulicz packing (6)	PJ leakage, pancreatitis	28	Jejunal necrosis + GJ leakage 1.5 mo after completion (early postoperative death)
5/M/45	Completion pancreatectomy, splenectomy (9)	PJ leakage, peritonitis, pancreatitis	23	Persistent sepsis, recovery from MOF, local recurrence 1 y later (late death)
6/M/66	Completion pancreatectomy, splenic preservation (2)	PJ leakage, peritonitis, pancreatitis	12	Splenic vein bleeding and GJ + HJ leakage (early postoperative death)
7/F/46	Completion pancreatectomy, splenectomy (3)	PJ leakage, peritonitis, pancreatitis, pancreatic necrosis	18	Alive
8/M/53†	Completion pancreatectomy, splenic preservation, biliary intubation, Mikulicz packing (3)	Peritonitis, PJ leakage, HJ leakage, pancreatitis	17	Biliary refection (alive)

Abbreviations: APACHE, Acute Physiology and Chronic Health Evaluation; GJ, gastrojejunostomy; HJ, hepaticojejunostomy; MOF, multiorgan failure; PJ, pancreaticojejunostomy.

*Celiomesenteric trunk.

†This patient was referred to our institution.

2 in the pancreatic area. Five patients had their abdominal wall closed conventionally and 3 had exclusive cutaneous closure. The intraperitoneal microorganisms associated with postoperative peritonitis were *Candida albicans* (n=1), *Escherichia coli* (n=5), *Proteus* species (n=1), *Pseudomonas* species (n=1), and *Enterobacter cloacae* (n=2). Two patients had polymicrobial infection and 6 had monomicrobial infection.

OPERATIVE MORTALITY AND MORBIDITY

Three patients (38%) died in the early postoperative period (2, 19, and 57 days after completion pancreatectomy). Two of these patients required early reoperation. One patient had a recurrent intra-abdominal abscess due to jejunal necrosis. He was reoperated on 49 days after completion pancreatectomy and had a partial jejunal resection with intubation of gastrojejunal anastomosis and double enterostomy. He died 8 days later. One patient had postoperative bleeding secondary to splenic vein erosion, associated with biliary and gastric anastomosis leak. He was reoperated on for splenic vein ligation and intubation of both anastomosis. He died 11 days later.

Six patients had postoperative medical complications: hypoglycemia (n=2), pneumopathy (n=2), myocardial infarction (n=1), renal failure (n=2), and severe confusion (n=1). Mean hospital stay was 64 days for survivors.

LONG-TERM OUTCOME

Four patients had their enterostomy closed without mortality or morbidity. Two patients died of cancer recurrence in the year after their Whipple procedure (11 and 13 months). An enterocutaneous fistula appeared 13 months after pancreatic completion and required resection of the fistulated gastrojejunostomy and a new gastrojejunostomy.

None of the patients died of the consequences of diabetes. Two patients had severe diabetic complications: severe hypoglycemia without the need for hospitalization (n=1) and hypoglycemic coma with neurologic complications (n=1). The other 2 patients had difficult diabetes control with regimens of subcutaneous low-dose insulin, 0.38 U/kg per day. Moreover, 1 of these 2 patients had intolerance to oral pancreatic enzyme and experienced diarrhea and malabsorption.

COMMENT

The safety of the pancreatic anastomosis is closely related to the quality of the pancreatic remnant. While there is no more than 8% anastomotic leak in chronic pancreatitis, it can reach 14% to 23% when the pancreatic parenchyma is normal.¹⁵⁻¹⁸ Among patients with a postoperative pancreatic anastomotic leak, 70% to 80% can be treated nonoperatively, but 10% to 15% need invasive attempts and percutaneous drainage of intra-abdominal abscess. Moreover, 10% to 15% of the patients with pancreatic anastomotic leak develop severe complications such as peritonitis or bleeding, requiring reintervention.^{19,20} Few articles have been written about the results of completion pancreatectomy in the early postoperative period regarding the management of postoperative peritonitis associated with pancreatic leakage. Most published series about completion pancreatectomy mention it as a means to control postoperative complications such as uncontrollable anastomotic leaks, bleeding, or abscesses, but not specifically peritonitis. In our group of patients, completion pancreatectomy was chosen as a salvage procedure for the treatment of postoperative peritonitis associated with pancreatic leakage.

The importance of considering postoperative peritonitis separately has been stressed by many authors.^{10,21,22} This distinction between other forms of peritonitis and post-

operative peritonitis is further justified by the high mortality rates reported in series focused on the subject, which average 50%, well above the usual mortality rate associated with primary peritonitis, which averages 20%. In our series, the early death rate was 38%.

Postoperative leakage from the upper gastrointestinal tract associated with peritonitis represents a specific technical challenge to the surgeon, as exteriorization of the source of infection is impossible. Other series have published the outcome of completion pancreatectomy.^{15,23,24} van Berge Henegouwen et al¹⁶ compared the outcomes of percutaneous drainage and completion pancreatectomy. The group of patients undergoing completion pancreatectomy showed fewer relaparotomies, less mortality, and a shorter hospital stay. However, in this series, most of the patients were reoperated on for persistent pancreatic fistula, without peritonitis. Farley et al,²³ in their series of 17 patients mainly reoperated on for postoperative complications, pointed out the necessity for completion pancreatectomy when operative findings are irreparable pancreatic anastomotic dehiscence with extended sepsis or severe pancreatitis.

Reoperation was not delayed in our series; patients were reoperated on a mean of 5.8 days after pancreaticoduodenectomy. Smith et al²⁴ reported in a selected group of patients with postoperative complications that delayed reexploration with possible completion pancreatectomy can lead to death. Seven (64%) of their 11 patients reoperated on a mean of 18 days after Whipple resection died. The authors suspected that reoperation came too late in patients with systemic manifestations.

Splenic preservation was performed in 2 patients in our series. Our aim was to reduce the space left after completion pancreatectomy and splenectomy, not to reduce the risk of overwhelming postsplenectomy infection. However, as one of our patients died of splenic vein erosion after splenic preservation, we decided to not preserve the spleen in subsequent patients.

Induced diabetes after completion pancreatectomy is unstable, with frequent, severe, potentially lethal hypoglycemic events^{25,26} and low need for insulin. In our series, none of the patients died of severe hypoglycemia, but one of them had a coma with neurologic sequelae.

In conclusion, postoperative peritonitis after pancreaticoduodenectomy is a major complication associated with a high mortality rate. However, completion pancreatectomy is probably the only surgical option available to control the source of infection.

Accepted for publication June 28, 2003.

Corresponding author: Yann Parc, MD, PhD, Department of Digestive Surgery, Hôpital Saint-Antoine, Assistance Publique/Hôpitaux de Paris, Université Pierre et Marie Curie, 184 rue du Faubourg Saint-Antoine, F-75571 Paris, France (e-mail: yann.parc@sat.ap-hop-paris.fr).

- Whipple A, Parsons W, Mullins C. Treatment of carcinoma of the ampulla of Vater. *Ann Surg.* 1935;102:763-779.
- Kausch W. Das Carcinom der Papilla Duodeni und seine radikale Entfernung: beibrage klinischen. *Chirurgie.* 1912;78:439-486.
- Allema JH, Reinders ME, van Gulik TM, et al. Prognostic factors for survival after pancreaticoduodenectomy for patients with carcinoma of the pancreatic head region. *Cancer.* 1995;75:2069-2076.
- Cameron JL, Pitt HA, Yeo CJ, Lillemoe KD, Kaufman HS, Coleman J. One hundred and forty-five consecutive pancreaticoduodenectomies without mortality. *Ann Surg.* 1993;217:430-435.
- Miedema BW, Sarr MG, van Heerden JA, Nagorney DM, McIlrath DC, Ilstrup D. Complications following pancreaticoduodenectomy: current management. *Arch Surg.* 1992;127:945-949.
- Sohn TA, Yeo CJ, Cameron JL, et al. Resected adenocarcinoma of the pancreas—616 patients: results, outcomes, and prognostic indicators. *J Gastrointest Surg.* 2000;4:567-579.
- Büchler MW, Friess H, Wagner M, Kulli C, Wagener V, Z'Graggen K. Pancreatic fistula after pancreatic head resection. *Br J Surg.* 2000;87:883-889.
- Cullen JJ, Sarr MG, Ilstrup DM. Pancreatic anastomotic leak after pancreaticoduodenectomy: incidence, significance, and management. *Am J Surg.* 1994;168:295-298.
- Trede M, Schwall G. The complications of pancreatectomy. *Ann Surg.* 1988;207:39-47.
- Wittmann DH, Schein M, Condon RE. Management of secondary peritonitis. *Ann Surg.* 1996;224:10-18.
- Parc Y, Frileux P, Vaillant JC, Ollivier JM, Parc R. Post-operative peritonitis originating from the duodenum: operative management by intubation and continuous intraluminal irrigation. *Br J Surg.* 1999;86:1207-1212.
- Spigelman AD, Williams CB, Talbot IC, Domizio P, Phillips RKS. Upper gastrointestinal cancer in patients with familial adenomatous polyposis. *Lancet.* 1989;2:783-785.
- Knaus W, Draper EA, Wagner DP, Zimmerman JE. APACHE II: a severity of disease classification system. *Crit Care Med.* 1985;13:818-829.
- Lévy E, Palmer DL, Frileux P, Hannoun L, Nordlinger B, Tiret E. Septic necrosis of the midline wound in postoperative peritonitis: successful management by debridement, myocutaneous advancement, and primary skin closure. *Ann Surg.* 1988;207:470-479.
- Hamanaka Y, Nishihara K, Hamasaki T. Pancreatic juice outcome after duodenopancreatectomy in relation to pancreatic consistency, duct size, and leakage. *Surgery.* 1996;119:281-287.
- van Berge Henegouwen MI, De Wit LT, Van Gulik TM, Obertop H, Gouma DJ. Incidence, risk factors and treatment of pancreatic leakage after pancreaticoduodenectomy: drainage versus resection of the pancreatic remnant. *J Am Coll Surg.* 1997;185:18-24.
- Stapleton GN, Williamson RCN. Proximal pancreaticoduodenectomy for chronic pancreatitis. *Br J Surg.* 1996;83:1433-1440.
- Traverso LW, Kozarek RA. The Whipple procedure for severe complications of chronic pancreatitis. *Arch Surg.* 1993;128:1047-1053.
- Cullen JJ, Sarr MG, Ilstrup DM. Pancreatic anastomosis leak after pancreaticoduodenectomy: incidence, significance and management. *Am J Surg.* 1994;168:295-298.
- Yeo CJ. Management of complications following pancreaticoduodenectomy. *Surg Clin North Am.* 1995;75:913-924.
- Billing A, Fröhlich D, Schildberg FW, Peritonitis Study Group. Prediction of outcome using the Mannheim peritonitis index in 2003 patients. *Br J Surg.* 1994;81:209-213.
- Krukowski ZH, Matheson NA. Ten-year computerized audit of infection after abdominal surgery. *Br J Surg.* 1988;75:857-861.
- Farley DR, Schwall G, Trede M. Completion pancreatectomy for surgical complication after pancreaticoduodenectomy. *Br J Surg.* 1996;83:176-179.
- Smith CD, Sarr MG, Van Heerden JA. Completion pancreatectomy following pancreaticoduodenectomy: clinical experience. *World J Surg.* 1992;16:521-524.
- Assan R, Alexandre JH, Tiengo A, Marre M, Costamailles L, Lhomme C. Survival and rehabilitation after total pancreatectomy: a follow-up of 36 patients. *Diabete Metab.* 1985;11:303-309.
- Inse I, Anderson H, Andrén-Sandberg Å. Total pancreatectomy for cancer of the pancreas: is it appropriate? *World J Surg.* 1996;20:288-284.