

An Algorithm to Maximize Use of Minimally Invasive Parathyroidectomy

Roderick M. Quiros, MD; Joseph Alioto, BA; Scott M. Wilhelm, MD; Amjad Ali, MD; Richard A. Prinz, MD

Hypothesis: Minimally invasive parathyroidectomy (MIP) depends on accurate preoperative localization of abnormal parathyroid glands. If the findings of a technetium Tc 99m sestamibi-labeled single-photon emission computed tomography (SPECT) (hereafter referred to as sestamibi SPECT or scan) are negative or ambiguous, cervical ultrasonography (CUS) may increase the success of preoperative gland localization and MIP, avoiding bilateral neck exploration.

Design: We collected data regarding preoperative sestamibi SPECT and CUS for parathyroid gland localization and intraoperative findings.

Setting: Tertiary care university hospital.

Patients: From August 1, 2000, through January 31, 2003, 71 patients (12 men and 59 women; mean age, 59 years) with primary hyperparathyroidism underwent preoperative sestamibi SPECT and CUS. Patients with prior or concurrent thyroid surgery, reoperative parathyroid disease, secondary/tertiary hyperparathyroidism, or studies performed at outside hospitals, were excluded. The MIP was performed by 1 surgeon with a 2- to 3-cm incision made on the side of the neck where the abnormal gland was preoperatively located.

Main Outcome Measurements: Operative findings were compared with results of preoperative studies to determine the accuracy of sestamibi SPECT and CUS for successful MIP.

Results: All 71 patients underwent preoperative sestamibi SPECT and CUS. Sestamibi scanning was accurate in 53 (75%) of 71 patients, whereas CUS was accurate in 40 (56%) in determining the side where the glands were located. Sestamibi scan and CUS findings were negative in 5 patients. These patients underwent planned bilateral neck exploration. Of the remaining 66 patients, MIP was successfully performed in 60 (91%). The CUS was complementary to sestamibi scanning in 9 (15%) of these 60 patients, allowing them to avoid bilateral neck exploration.

Conclusions: A positive sestamibi scan finding is the only preoperative requirement for most patients with primary hyperparathyroidism for MIP. If the sestamibi scan findings are negative or ambiguous, preoperative CUS can localize an additional 14% of enlarged parathyroid glands, further facilitating an MIP in these patients.

Arch Surg. 2004;139:501-507

THE TRADITIONAL SURGICAL approach for primary hyperparathyroidism involves bilateral neck exploration (BNE) and evaluation of all 4 glands. The high cure rate achieved with BNE (98%-99%) and a morbidity and mortality of less than 1% make this approach the gold standard for surgical cure of primary hyperparathyroidism.¹ However, developments during the past decade, most notably preoperative imaging for gland localization and biochemical confirmation of surgical cure by means of intraoperative intact parathyroid hormone (IOPTH) assay, have made minimally invasive parathyroidectomy (MIP) an alternative approach for primary hyperparathyroidism.

For patients with single-gland disease, MIP results in similar rates of surgical cure, morbidity, and mortality.^{2,3} In addition, various authors have shown that MIP can be performed less expensively than conventional BNE, with reduced operative times and overall hospital lengths of stay that are comparable to those of BNE.^{4,5} The feasibility of MIP depends largely on preoperative localization of the abnormal gland. Technetium Tc 99m (^{99m}Tc) sestamibi-labeled scanning with or without single-photon emission computed tomography (SPECT) (hereafter referred to as sestamibi scan or SPECT), ultrasonography, computed tomographic scanning, and magnetic resonance imaging have all been proposed as localization studies for MIP.^{6,7}

From the Departments of General Surgery (Drs Quiros, Wilhelm, and Prinz and Mr Alioto) and Radiology (Dr Ali), Rush University Medical Center, Chicago, Ill.

We propose an algorithm using sestamibi SPECT as the primary method of preoperative gland localization. Cervical ultrasonography (CUS) is used as a complementary study when the sestamibi scan findings are nonlocalizing or equivocal. The IOPTH assay is also used to confirm surgical cure.

METHODS

From August 1, 2000, through January 31, 2003, 169 consecutive patients with hyperparathyroidism underwent parathyroidectomy performed by one of us (R.A.P.) in a university-based, tertiary care center. Patients were referred with various symptoms of hyperparathyroidism, ranging from subjective symptoms such as general malaise or depressed mood to objective signs and symptoms such as decreased bone mineral density or nephrolithiasis. Hyperparathyroidism, although suggested by clinical signs and symptoms, was diagnosed by the presence of elevations in serum intact parathyroid hormone (PTH) levels in all patients. Biochemical confirmation of hyperparathyroidism in all patients, with the presence of symptoms in most patients, was considered an operative indication. Because we wanted to compare the accuracy of sestamibi SPECT and CUS in MIP, we excluded patients with CUS only or CUS and sestamibi scans from outside institutions ($n=28$), sestamibi scans alone ($n=10$), previous or concurrent thyroid surgery ($n=26$), reoperative parathyroid disease ($n=5$), secondary or tertiary hyperparathyroidism ($n=20$), multiple endocrine neoplasia syndromes ($n=2$), and ectopic or mediastinal glands on preoperative studies ($n=3$); those who underwent parathyroidectomy using an intraoperative gamma probe ($n=3$); and those who had no preoperative studies ($n=1$). The remaining 71 patients were included in the study. All 71 patients preoperatively underwent sestamibi SPECT and CUS at Rush University Medical Center, Chicago, Ill. One nuclear medicine physician (A.A.) interpreted all of the sestamibi scans. The CUS was performed and the results were read by various radiologists. More recently, the CUS studies have been performed in the surgeon's office.

The scintigraphy technique included static planar imaging and SPECT imaging of the neck and chest after intravenous isotope injection (25 mCi [925 MBq] of ^{99m}Tc sestamibi). The static images were acquired 15 minutes after injection for 100 000 counts (approximately 5 minutes for the first acquisition) in a 128×128 matrix. SPECT imaging was then performed immediately after static imaging. SPECT images were obtained with a 64-view noncircular rotation using low-energy, high-resolution, parallel-hole collimators on a dual-head camera. Each view was acquired with 80 000 counts in a 128×128 matrix. The static and SPECT imaging was repeated 3 hours after the initial isotope injection.

Once the glands were localized, the patients underwent parathyroidectomy under general anesthesia or laryngeal mask airway. Our technique uses a 2- to 3-cm transverse incision placed on the side of the abnormal gland, medial to the medial margin of the sternocleidomastoid muscle. The incision for presumed inferior glands is placed 1 to 2 cm above the clavicle, whereas that for presumed superior glands is placed somewhat higher. The platysma is transected, and the sternocleidomastoid muscle is retracted laterally to expose the strap muscles. These are retracted medially or transected, exposing a space bordered by the thyroid gland anteromedially, the carotid sheath laterally, and the prevertebral fascia posteriorly. Most glands are sought and detected within this space. The intraoperative locations of glands were noted and compared with the locations suggested on preoperative localizing study findings. Patients whose preoperative sestamibi

scans and CUS yielded negative or nonlocalizing findings underwent planned BNE.

The adequacy of resection was assessed with IOPTH measurements, using the Immulite Turbo intact PTH assay (Diagnostic Products Corp, Los Angeles, Calif). The IOPTH levels were measured peripherally after induction of anesthesia (baseline), at 5 and 10 minutes after resection of the abnormal gland, and, in some patients, at skin closure. We considered a decrease of at least 50% from baseline at 5 to 10 minutes after gland resection as indicative of successful parathyroidectomy, as described by Irvin and Deriso.⁸

Most patients were discharged on the day of surgery or were kept overnight as 23-hour admissions. Patients were routinely seen in the office within the first week after operation. Most patients also returned to the office for a 1-month follow-up visit. Serum calcium and intact PTH levels were measured 1 month after operation.

RESULTS

The 71 patients consisted of 59 females and 12 males, with a mean age of 59 years (range, 11-88 years). All were diagnosed as having primary hyperparathyroidism by means of history and confirmed elevations of serum calcium and intact PTH levels. The mean preoperative serum calcium level was 10.6 ± 0.7 mg/dL (2.7 ± 0.2 mmol/L) (range, 9.3-12.2 mg/dL [2.3 - 3.0 mmol/L]), and the mean baseline IOPTH level was 238.4 ± 274.2 pg/mL (range, 63.6-2134.0 pg/mL). The reference ranges for serum calcium and intact PTH levels at our institution are 8.7 to 10.7 mg/dL (2.2 - 2.7 mmol/L) and 22 to 60 pg/mL, respectively.

All patients successfully underwent sestamibi SPECT at our university. Preoperative sestamibi scanning was correct in identifying exact gland location in 49 (69%). Preoperative sestamibi scanning was correct in identifying the side of the neck where the glands were situated in 53 (75%) of 71 patients.

Of these 53 patients, 51 underwent successful MIP based on the preoperative sestamibi scan findings. The other 2 patients had accurate sestamibi scans indicative of lower glands, which were not recognized by the surgeon as intrathymic. These 2 patients, therefore, underwent conversion from MIP to BNE (**Figure 1**).

In 18 patients, preoperative sestamibi scan findings were negative, ambiguous, or incorrect (Figure 1). Of these, 9 were still able to undergo successful MIP because CUS correctly identified the side of the neck where the abnormal glands were located. In 4 of these 18 patients with equivocal sestamibi scan findings, CUS findings were incorrect. The MIP was started at the location indicated by sonogram, although conversion to BNE was mandatory for surgical cure owing to inaccuracy of the CUS studies. In 5 of the 18 patients, preoperative sestamibi scan and CUS findings were negative. These 5 patients were not considered candidates for MIP and subsequently underwent planned BNE (**Table 1**).

Because 5 patients from the original 71 underwent a planned BNE owing to failure of the sestamibi scan and CUS findings to detect abnormal glands, a maximum of 66 patients were true candidates for MIP (Figure 1). Of these 66 patients, 60 (91%) underwent successful MIP. Of these 60 patients, 9 (14%) had negative or ambiguous sestamibi scan findings, but CUS studies correctly

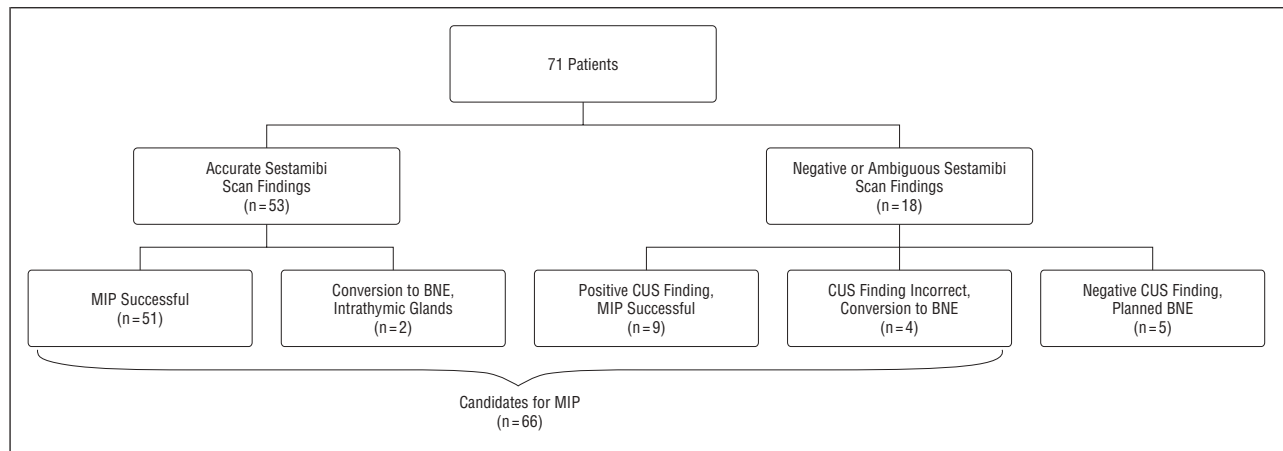


Figure 1. Patient distribution. MIP indicates minimally invasive parathyroidectomy; BNE, bilateral neck exploration; CUS, cervical ultrasound (CUS); and sestamibi scan, scan labeled with technetium Tc 99m sestamibi.

localized glands, enabling MIP. Fifty-one patients (77%) underwent successful MIP irrespective of CUS results (**Figure 2**).

All patients successfully underwent CUS. Sonography correctly localized abnormal parathyroid glands in 34 (48%) of 71 patients and accurately indicated the side of the neck where the glands were located in 40 (56%). When determining the start site for MIP, more weight was given toward sestamibi scan results than CUS results.

All 71 patients in our study had unoperated primary hyperparathyroidism. Sixty-six patients (93%) had single-gland adenomas. Three patients (4%) had 4-gland hyperplasia. These 3 patients ultimately underwent BNE (2 planned and 1 conversion from MIP). Two patients (3%) had double adenomas. Because the abnormal glands were on the same side of the neck in both patients, both underwent successful MIP.

Four of our 71 patients had intrathyroidal glands. This was not recognized in 2 of these patients, despite accurate sestamibi scan findings, and led to conversion from MIP to BNE. One of these patients had a negative CUS finding (patient 1 in **Table 2**), and the other had an accurate CUS (patient 3 in **Table 2**). In 1 of the 4 patients with intrathyroidal glands, sestamibi scan findings were negative, but CUS accurately indicated an inferiorly located gland (patient 2 in **Table 2**). This was not found by the surgeon during MIP, and a BNE was pursued instead. In the last of these 4 patients, preoperative sestamibi scan findings were negative, and CUS findings were incorrect (patient 4 in **Table 2**). She also underwent conversion from MIP to BNE.

Mean baseline IOPTH levels measured 238.3 ± 274.2 pg/mL. Mean IOPTH levels measured 101.7 ± 144.9 and 47.0 ± 117.8 pg/mL at 5 and 10 minutes, respectively, after parathyroidectomy. The IOPTH levels decreased by 50% or more of baseline values in 46 (65%) of 71 patients at 5 minutes after parathyroidectomy, and in all 71 patients (100%) at 10 minutes after parathyroidectomy. At closure, the mean IOPTH level was 26.2 ± 16.6 pg/mL. The mean intact PTH level was 78.7 ± 61.0 pg/mL at the 1-month follow-up. The mean preoperative serum calcium level measured 10.6 ± 0.8 mg/dL (2.7 ± 0.2 mmol/L), and decreased to 9.2 ± 0.6 mg/dL (2.3 ± 0.2

Table 1. Patients With Negative, Ambiguous, and Incorrect Results of Sestamibi Scans

Patient No.	CUS Finding	Procedure	Diagnosis
Sestamibi Scan Findings Negative			
1	+	MIP	SA
2	-	Planned BNE	SA
3	+	MIP	SA
4	-	Planned BNE	4GH
5	+	MIP	DA
6	+	Conversion to BNE	SA (intrathyroidal)
7	+	MIP	SA
8	-	Planned BNE	SA
9	+	MIP	SA
10	-	Planned BNE	SA
11	+	MIP	SA
12	-	Planned BNE	SA
13	Incorrect +	Conversion to BNE	SA (intrathyroidal)
14	+	MIP	SA
Sestamibi Scan Findings Ambiguous			
15	+	MIP	SA
16	+	MIP	SA
Sestamibi Scan Findings Incorrect			
17	Incorrect +	Conversion to BNE	4GH
18	-	Conversion to BNE	4GH

Abbreviations: BNE, bilateral neck exploration; CUS, cervical ultrasonography; DA, double adenoma; 4GH, 4-gland hyperplasia; MIP, minimally invasive parathyroidectomy; SA, single adenoma; sestamibi scan, scan labeled with technetium Tc 99m sestamibi; +, gland detected; -, gland not detected.

mmol/L) by the 1-month follow-up. All 71 patients were normocalcemic or were receiving calcium supplementation 1 month after parathyroidectomy.

The mean and median weights of parathyroid glands successfully removed during MIP were 1.6 and 1.0 g, respectively. The mean and median weights of parathyroid glands removed during BNE were 0.7 and 0.4 g, respectively.

COMMENT

For patients with primary hyperparathyroidism, MIP has been shown to be as effective as BNE in achieving im-

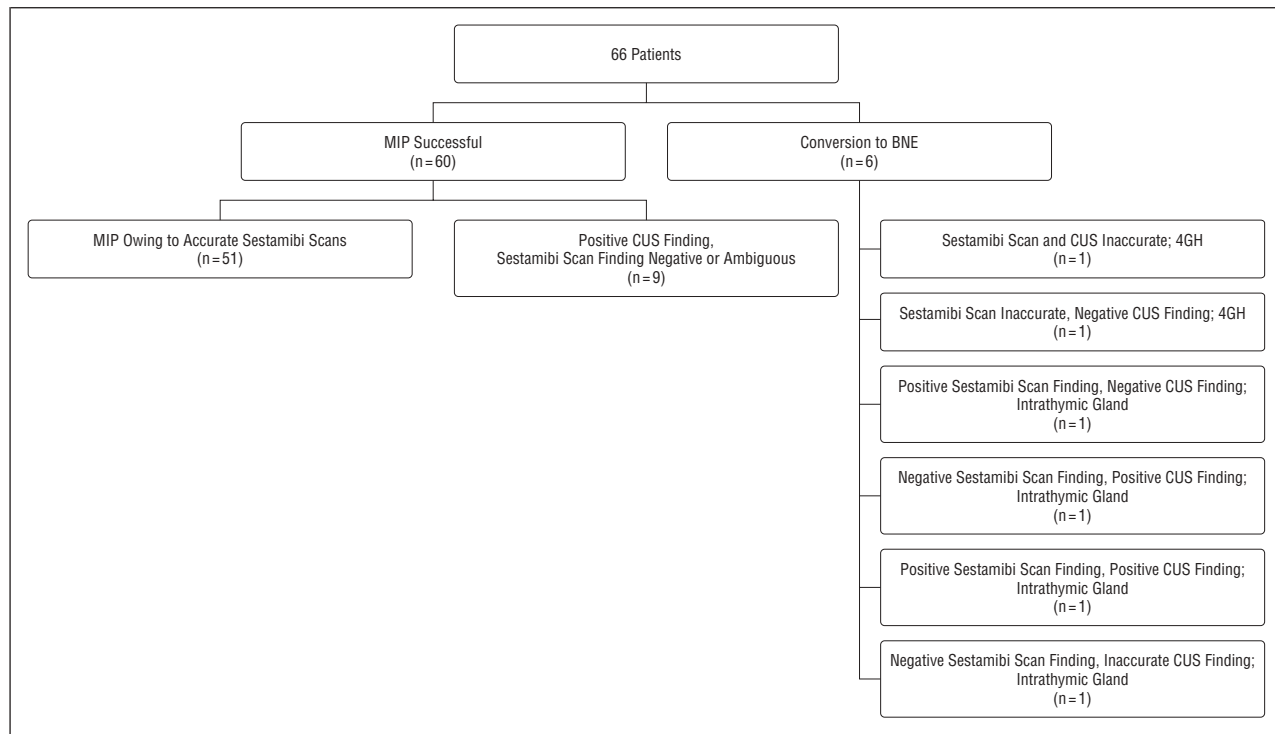


Figure 2. Among patients who were candidates for minimally invasive parathyroidectomy (MIP), cervical ultrasound (CUS) increased the number of patients who underwent successful MIP by 14%. The studies and final diagnoses of the 6 patients who underwent conversion to bilateral neck exploration (BNE) are shown. 4GH indicates 4-gland hyperplasia; other abbreviations are explained in the legend to Figure 1.

Table 2. Intrathyroidic Parathyroid Glands

Patient No.	Sestamibi Scan Finding	CUS	Procedure	Diagnosis
1	+	-	Conversion to BNE	SA
2	-	+	Conversion to BNE	SA
3	+	+	Conversion to BNE	SA
4	-	Incorrect +	Conversion to BNE	SA

Abbreviations: See Table 1.

mediate surgical cure.⁹⁻¹¹ For patients with sporadic primary hyperparathyroidism, the long-term outcome of MIP is comparable to that of BNE, with similar rates of biochemical cure at 2 to 7 years after surgery.^{12,13} The MIP is efficacious from clinical and cost perspectives and has become an accepted means of surgical treatment for patients with primary hyperparathyroidism.¹⁴

Minimally invasive parathyroidectomy is completely dependent on preoperative localization of abnormal parathyroid glands. The introduction of new radio-nuclide agents and scanning technology has stimulated its use during the past several years. Although a number of radioisotopes are available, ^{99m}Tc sestamibi has been shown to be most accurate in the detection of parathyroid adenomas, making it attractive and effective for use in MIP.¹⁵⁻¹⁸ However, preoperative sestamibi scanning is not without its limitations. Sestamibi scan findings often fail to predict the presence of multigland disease, and when they do, they are often incorrect.^{19,20} With the rate of multigland disease in patients with sporadic primary hyperparathyroidism as high as 15%, some patients will

require conversion from MIP to BNE because of the failure of sestamibi scanning to detect more than a single abnormal gland, even if they are preoperatively considered candidates for MIP.¹⁹

In our study, only 5 (7%) of 71 patients with primary hyperparathyroidism had multiple-gland disease. This is clearly less than other reported figures.^{3,19,20} Two of these patients had double adenomas, both located on the same side of the neck. Both underwent successful MIP, as both glands were accessible through the same incision. One of these patients had a single gland initially localized by means of sestamibi scanning and CUS, and the other had a negative sestamibi scan finding but a CUS finding indicative of a single gland. In both of these patients, resection of the preoperatively located gland by means of MIP did not yield the appropriate decrease in IOPH levels. Search and resection of the second ipsilateral gland through the same incision, instead of immediate conversion to BNE, enabled both patients to undergo MIP. Three of our 71 patients had 4-gland hyperplasia. All 3 patients underwent BNE. Two of these 3 patients had a single gland detected by means of sestamibi scan findings, with negative or inaccurate CUS findings. Although their operations were started as MIP, they ultimately resulted in conversion to BNE. The last of these 3 patients had a planned BNE, as the sestamibi scan and CUS findings were negative. These patients illustrate the shortcomings of preoperative sestamibi scanning, namely, inaccuracy in the face of multiple abnormal glands.

The benefit of CUS as an adjunct to sestamibi scanning may be questioned, because the latter has been shown to be more sensitive than CUS in localizing parathyroid adenomas.^{21,22} In the era of conventional BNE, the use

of both preoperative studies increased the sensitivity of detection of abnormal glands compared with the sensitivity of either test alone.²³ This was found even when the less accurate planar sestamibi scanning without SPECT was used. In hospitals where preoperative sestamibi scanning has a low sensitivity owing to physician experience or equipmental/institutional limitations, or in the high likelihood of multigland disease, preoperative CUS may be helpful in directing MIP.²⁴ Preoperative sestamibi scanning and CUS may also be complementary in the setting of small parathyroid glands, which may not retain enough radioisotope to be readily detectable on sestamibi scan, or in the presence of hyperactive thyroid nodules or multinodular goiter, which may retain too much radioisotope on sestamibi scan, masking abnormal parathyroid glands.²⁵ Moreover, in patients with primary hyperparathyroidism undergoing reoperation, preoperative sestamibi scan and CUS findings have been shown to be complementary.^{26,27}

In this study, the accuracy of preoperative sestamibi scanning in predicting the exact gland location and the correct side of the parathyroid adenoma was 69% and 75%, respectively, compared with 48% and 56%, respectively, for CUS. This may be explained by a number of factors. First, the sestamibi scans were read by a single senior radiologist specializing in nuclear medicine, with particular expertise in the imaging of endocrine tumors. In contrast, CUS studies were performed and interpreted by various radiology residents and attending staff. Sestamibi scans were performed with SPECT imaging, which literally adds another dimension in the detection of abnormal glands, allowing better localization of isotope uptake compared with single-isotope dual-phase scanning.²⁸ Even with a high overall sensitivity, preoperative sestamibi scanning was augmented by CUS in 9 patients in our study. This allowed 14% more patients who were candidates for MIP to successfully undergo this operation. In patients where the preoperative sestamibi scan finding is negative or ambiguous, CUS should be performed. If CUS identifies a gland despite such sestamibi scan findings, there is a high likelihood for successful MIP if IOPTH monitoring is used to ensure that further exploration is not required.

Surgeon experience plays a role in the success of MIP. Our results suggest that even if preoperative localization is not perfectly accurate in predicting the exact location of the abnormal gland, MIP is still possible, as long as the gland is localized to the correct side of the neck. The success of the minimally invasive approach in the face of inaccurate preoperative studies depends on the surgeon's familiarity with the anatomy and alternate locations for glands, as well as his or her ability to operate through a small incision. A unilateral incision can be slightly enlarged to facilitate examination of the upper and lower glands on the same side of the neck. However, the surgeon should be prepared to convert to BNE should this approach be unsuccessful. In the present study, 2 patients had sestamibi scans that correctly localized inferior parathyroid glands, and 1 patient had CUS study results indicative of an inferior gland. Despite surgeon experience, these patients underwent conversion to BNE,

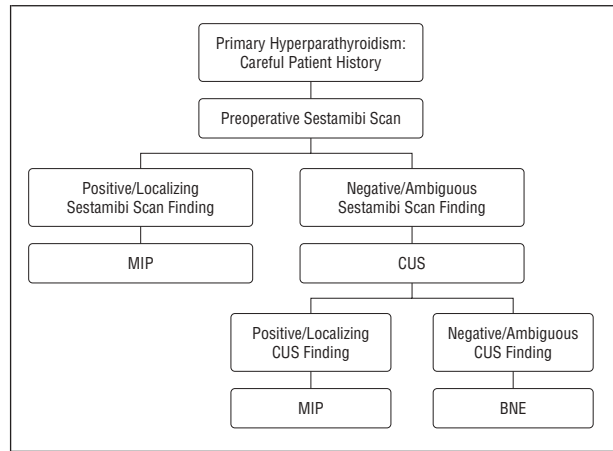


Figure 3. An algorithm for minimally invasive parathyroidectomy (MIP). Other abbreviations are explained in the legend to Figure 1.

as the glands in question turned out to be intrathymic glands. It may be argued that MIP could have been successful if the surgeon had recognized this fact before converting to BNE. Of the 66 patients who were candidates for MIP, these 3 patients underwent conversion because of inherent difficulty recognizing glands adherent to or within the thymus.

Minimally invasive parathyroidectomy depends on accurate preoperative localization and the use of IOPTH monitoring.²⁹ The assay allows appropriate termination of the operation and rules out the possibility of missed multigland disease. Some surgeons have suggested that MIP can be performed without the IOPTH assay, using the intraoperative gamma probe instead to evaluate for completeness of surgical resection.³⁰ Others have compared the use of IOPTH monitoring and the intraoperative gamma probe in MIP and have found that the latter contributes little to surgical success³¹ and may even provide confusing information in MIP.²⁵ We have found that the intraoperative gamma probe is helpful in reoperative procedures and in the detection of ectopic glands, although we prefer to use it with IOPTH monitoring in these situations.³²

CONCLUSIONS

Minimally invasive parathyroidectomy is a feasible option in many patients with primary hyperparathyroidism. Its success first depends on taking a careful patient history to exclude those with familial syndromes or chronic renal failure predisposing to multigland disease. In patients with concurrent thyroid disease, MIP is not the best option if a thyroidectomy must also be performed. Successful MIP is also dependent on preoperative localization. Although there are several modalities to localize abnormal glands, preoperative sestamibi SPECT, with selective use of preoperative CUS in cases where sestamibi scan findings are negative or ambiguous, is the only study needed for MIP. Finally, the extent of operation is determined by functional cure of hyperparathyroidism, which is confirmed by use of IOPTH monitoring. Our algorithm to maximize the use of MIP is shown in **Figure 3**.

Accepted for publication January 2, 2004.

This study was presented at the 111th Scientific Session of the Western Surgical Association; November 11, 2003; Tucson, Ariz, and is published after peer review and revision. The discussions that follow this article are based on the originally submitted manuscript and not the revised manuscript.

Corresponding author and reprints: Richard A. Prinz, MD, Department of General Surgery, Rush University Medical Center, 1653 W Congress Pkwy, Chicago, IL 60612-3833 (e-mail: rprinz@rush.edu).

REFERENCES

1. van Heerden JA, Grant CS. Surgical treatment of primary hyperparathyroidism: an institutional perspective. *World J Surg.* 1991;15:688-692.
2. Burkey SH, Snyder WH, Nwariaku F, Watumull L, Mathews D. Directed parathyroidectomy: feasibility and performance in 100 consecutive patients with primary hyperparathyroidism. *Arch Surg.* 2003;138:604-609.
3. Udelsman R, Donovan PI, Sokoll LJ. One hundred consecutive minimally invasive parathyroid explorations. *Ann Surg.* 2000;232:331-339.
4. Chen H, Sokoll LJ, Udelsman R. Outpatient minimally invasive parathyroidectomy: a combination of sestamibi-SPECT localization, cervical block anesthesia, and intraoperative parathyroid hormone assay. *Surgery.* 1999;126:1016-1022.
5. Irvin GL, Sfakianakis G, Yeung L, et al. Ambulatory parathyroidectomy for primary hyperparathyroidism. *Arch Surg.* 1996;131:1074-1078.
6. Smit PC, Rinkles IHMB, van Dalen A, van Vroonhoven TJMV. Direct, minimally invasive adenectomy for primary hyperparathyroidism: an alternative to conventional neck exploration? *Ann Surg.* 2000;231:559-565.
7. Ishibashi M, Nishida H, Hiromatsu Y, Kojima K, Tabuchi E, Hayabuchi N. Comparison of technetium-99m-MIBI, technetium-99m-tetrofosmin, ultrasound, and MRI for localization of abnormal parathyroid glands. *J Nucl Med.* 1998;39:320-324.
8. Irvin GL, Deriso GT. A new, practical intraoperative parathyroid hormone assay. *Am J Surg.* 1994;168:466-468.
9. Delbridge LW, Dolan SJ, Hop TT, Robinson BG, Wilkinson MR, Reeve TS. Minimally invasive parathyroidectomy: 50 consecutive cases. *Med J Aust.* 2000;172:418-422.
10. Reeve TS, Babidge WJ, Parkyn RF, et al. Minimally invasive surgery for primary hyperparathyroidism: systematic review. *Arch Surg.* 2000;135:481-487.
11. Norman J, Shheda H, Farrell C. Minimally invasive parathyroidectomy for primary hyperparathyroidism: decreasing operative time and potential complications while improving cosmetic results. *Am Surg.* 1998;64:391-396.
12. Carneiro DM, Irvin GL. Late parathyroid function after successful parathyroidectomy guided by intraoperative hormone assay (QPTH) compared with the standard bilateral neck exploration. *Surgery.* 2000;128:925-929.
13. Gavin R, Johnson PR, Bolia A, Iqbal JS, Bell PRF. Long-term results of unilateral neck exploration for preoperatively localized nonfamilial parathyroid adenomas. *Am J Surg.* 1996;172:311-314.
14. Sackett WR, Barraclough B, Reeve TS, Delbridge LW. Worldwide trends in the surgical treatment of primary hyperparathyroidism in the era of minimally invasive parathyroidectomy. *Arch Surg.* 2002;137:1055-1059.
15. Vinay G, Yeh K, Burke GJ, Wei JP. 99m-Technetium sestamibi localized solitary parathyroid adenoma as an indication for limited unilateral surgical exploration. *Am J Surg.* 1998;176:409-412.
16. Martin D, Rosen IB, Ichise M. Evaluation of single isotope technetium 99m-sestamibi in localization efficiency for hyperparathyroidism. *Am J Surg.* 1996;172:633-636.
17. Malhotra A, Silver CE, Deshpande V, Freeman L. Preoperative parathyroid localization with sestamibi. *Am J Surg.* 1996;172:637-640.
18. Borley NR, Collins REC, O'Doherty M, Coakley A. Technetium-99m sestamibi parathyroid localization is accurate enough for scan-directed unilateral exploration. *Br J Surg.* 1996;83:989-991.
19. Moore FD, Manning F, Tanasijevic M. Intrinsic limitations to unilateral parathyroid exploration. *Ann Surg.* 1999;230:382-391.
20. Shen W, Sabanci U, Morita ET, Siperstein AE, Duh QY, Clark OH. Sestamibi scanning is inadequate for directing unilateral neck exploration for first-time parathyroidectomy. *Arch Surg.* 1997;132:969-976.
21. Light VL, McHenry CR, Jarjoura D, Sodee DP, Miron SD. Prospective comparison of dual-phase technetium-99m-sestamibi scintigraphy and high resolution ultrasonography in the evaluation of abnormal parathyroid glands. *Am Surg.* 1996;62:562-568.

22. Casas AT, Burke GJ, Sathyanarayana S, Mansberger AR, Wei JP. Prospective comparison of technetium-99m-sestamibi/iodine-123 radionuclide scan versus high resolution ultrasonography for the preoperative localization of abnormal parathyroid glands in patients with previously unoperated primary hyperparathyroidism. *Am J Surg.* 1993;166:369-373.
23. Arici C, Cheah K, Ituarte PHG, et al. Can localization studies be used to direct focused parathyroid operations? *Surgery.* 2001;129:720-729.
24. Purcell GP, Dirbas FM, Jeffrey RB, et al. Parathyroid localization with high-resolution ultrasound and technetium Tc 99m sestamibi. *Arch Surg.* 1999;134:824-830.
25. Inabnet WB, Kim CK, Haber RS, Lopchinsky RA. Radioguidance is not necessary during parathyroidectomy. *Arch Surg.* 2002;137:967-970.
26. Arkles LB, Jones T, Hicks RJ, De Luise MA, Chou ST. Impact of complementary parathyroid scintigraphy and ultrasonography on the surgical management of hyperparathyroidism. *Surgery.* 1996;120:845-851.
27. Feingold DL, Alexander R, Chen CG, et al. Ultrasound and sestamibi scan as the only preoperative imaging tests in reoperation for parathyroid adenomas. *Surgery.* 2000;128:1103-1110.
28. Pattou F, Huglo D, Proye C. Radionuclide scanning in parathyroid disease. *Br J Surg.* 1998;85:1605-1616.
29. Carty SE, Worsley MJ, Virji MA, Brown ML, Watson CG. Concise parathyroidectomy: the impact of preoperative SPECT ^{99m}Tc sestamibi scanning and intraoperative quick parathormone assay. *Surgery.* 1997;122:1107-1116.
30. Goldstein RE, Billheimer D, Martin WH, Richards K. Sestamibi scanning and minimally invasive radioguided parathyroidectomy without intraoperative parathyroid hormone measurement. *Ann Surg.* 2003;237:722-731.
31. Dackiw APB, Sussman JJ, Fritsche HA, et al. Relative contributions of technetium tc 99m sestamibi scintigraphy, intraoperative gamma probe detection, and the rapid parathyroid hormone assay to the surgical management of hyperparathyroidism. *Arch Surg.* 2000;135:550-557.
32. Quiros RM, Warren W, Prinz RA. Excision of a mediastinal parathyroid gland using video-assisted thoracoscopy, intraoperative ^{99m}Tc sestamibi scanning, and intraoperative intact PTH monitoring. *Endocr Pract.* In press.

DISCUSSION

Gary B. Talpos, MD, Detroit, Mich: Dr Prinz and I have previously discussed whether the glass is half full or half empty. Is there an algorithm that could prevent failed operations for this disease? The answer appears to be yes, according to this manuscript. It's evident that the seed for this paper occurred during the discussion of Dr Bill Snyder's paper at last year's meeting in Vancouver. The topic is increasingly important because the new National Institutes of Health guidelines for the management of primary hyperparathyroidism recommend that patients be referred for surgery at lower levels of hypercalcemia because, regardless of the degree of hypercalcemia, most patients are truly symptomatic and improve on quality-of-life instruments postoperatively. The crux of this issue is how we diagnose an abnormal parathyroid gland. Previously, we relied upon gross characteristics such as size, weight, color, and texture. The minimally invasive parathyroidectomy, or MIP, relies upon abnormal gland function as determined by sestamibi scan. When the functional or sestamibi scan is negative or ambiguous, the authors once again rely upon their eyes with the help of preoperative ultrasound to detect an abnormal gland. Intraoperative PTH monitoring provides the safety net.

My questions deal with patient selection, methodology, and outcomes. What constitutes the diagnosis of primary hyperparathyroidism in Chicago? What is the normal range for serum calcium? At least one of your patients, according to the manuscript, had a preoperative calcium of 8 mg/dL [2 mmol/L]. That is an aggressive definition for primary hyperparathyroidism, even for us from Detroit. Likewise, what are the preoperative PTH levels and the PTH normal range on your operated patients? The mean baseline intraoperative PTH level is measured at 238 pg/mL. Do you utilize the same machine for your preoperative diagnostic determinations? How many of your patients had normal nonsuppressed PTH levels? Some authors feel that this select group of earlier diagnosed patients or pa-

tients with milder disease remains troublesome for the MIP. Historically, what percent of patients at Rush were found to have multigland parathyroid disease on bilateral neck exploration? Your figure of 7% in the manuscript includes only those found utilizing this algorithm. What is the historical figure?

With regard to imaging, I note that the ultrasound study is now performed in Dr Prinz's office, hopefully after attending the American College of Surgeons ultrasound course. Initially, several radiologists performed your studies, leading to an accuracy rate of 48%. This is significantly below the 88% reported last year by Dr Snyder, who utilized only 2 radiologists. You missed an opportunity to highlight the importance of developing ultrasound expertise for parathyroid disease.

You also changed the methodology of your nuclear scanning during the study by adding SPECT (single-photo emission computed tomography). Did this impact your results? The many operational details of scanning behooves each one of us to understand the techniques used at our home institutions. Many authors have reported varying degree of scan accuracy depending upon calcium and PTH levels. Did you perform a subset analysis for this topic?

Intraoperative PTH determinations played an important role, preventing 2 failed operations in your series. We frequently find the incision closed long before the final levels are available. Consequently, we've gone to a same-day approach. What is your experience in this area? The manuscript states that all patients were normocalcemic postoperatively or maintained on calcium supplements. Are these the 2 patients with 4-gland disease? Can you reassure us that there were no complications?

Dr Prinz and his group are to be commended. The glass is half full for these patients when you can successfully perform the MIP in 91% of these carefully selected patients and achieve 100% cure. Whether we debate the merits of a 2- to 3-cm incision for MIP as reported here, vs a 4-cm incision for bilateral neck exploration, our patients and referring physicians are determining or have already determined that this will be the new gold standard. While the MIP can't yet be performed on every parathyroid patient, surgeons need to develop expertise with these techniques in order to achieve the success rates reported here. Thank you again for the opportunity to discuss this paper.

Dr Prinz: Dr Talpos, the diagnosis of primary hyperparathyroidism in this study was made in a standard manner. The patients had symptoms that could be attributable to hyperparathyroidism and had intact parathyroid hormone [PTH] levels that were inappropriately high compared to the serum calcium levels. The normal range for serum calcium at Rush is 8.5 to 10.3 mg/dL [2.1-2.6 mmol/L], and the normal range for intact PTH is 25 to 65 pg/mL. Almost all our patients had both elevated serum calcium and intact PTH levels. The 8.5-mg level of calcium was in error, and the lowest preoperative serum calcium was 9.9 mg/dL (2.5 mmol/L). This patient had episodes of kidney stones and intact PTH levels that were repeatedly greater than twice the upper limit of normal. The assay that we use in the operating room is modified so that it can give us quicker results. It is different than the standard assay, which was used to measure preoperative and postoperative intact PTH levels.

The question about how often multiglandular disease occurred in our experience prior to taking on minimally invasive parathyroidectomy probably relates or impacts to our cri-

teria for this study. In other words, we eliminated patients with MEN syndromes and other familial types of hyperparathyroidism. This cone down has also eliminated reoperative patients, another group that would increase the rate of multiglandular disease. In our prior experience, multiple gland disease would range from 10% to 15%, which is fairly standard.

You alluded to the fact that we had a rather low rate of positive identification of enlarged parathyroid glands with ultrasound. As you know, ultrasound is very user specific. It was not done in the most ideal way, since multiple ultrasonographers were performing the study. We now are doing the ultrasound in our office. We have taken the American College of Surgeons' head and neck ultrasound course and hope to improve on those results.

You commented about changing methodology for the sestamibi scan. It is true [that] when we started to do sestamibi scans, we did use planar studies, but all the patients in this particular group that we've reported had SPECT studies. We believe SPECT provides more accurate information, and there was no patient who did not have a SPECT scan in this series. We have not done subset analysis of either levels of calcium or levels of PTH to see if this impacts on the rate of imaging positivity with either ultrasound or sestamibi scanning. We could cull that data out, but we have not done so at this point.

You mention that intraoperative PTH monitoring is a safety net and did identify 2 patients who were not cured after removal of an enlarged gland. I'm really anal compulsive about the intraoperative PTH levels and I don't follow Dr Irvin's 50% drop. I am much more rigorous and like to see that level back into a normal range before I leave the operating room. This is probably not a cost-effective approach for use of operating room time. Truly, there were no complications in this series. All of the patients we are reporting were normocalcemic. However, as we have reported in the past, about 20% to 30% of our patients after operation will have an elevated PTH value. Most of these have come down as we follow them. We are also very compulsive in following these patients to be sure that they do have normal PTH levels ultimately, but we still have some that are elevated.

Quan-Yang Duh, MD, San Francisco, Calif: Do you use intraoperative ultrasound before the incision? Do you use it to help you make the incision and, if not, how do you decide where to make the incision? The other question is when we do MIP, especially for the upper gland, frequently we will take a peek at the lower gland and, if so, it is not a truly limited exploration. How often do you look at 2 glands on one side rather than 1?

Dr Prinz: Thanks very much, Quan. The last question, we do wait for our PTH values and that allows us sometimes to look a little bit more and see if we can identify a normal gland. Obviously, that's reassuring. However, I must admit that I don't have the numbers to say how often this has been done in our experience. In this study, the ultrasound was used in the radiology department. We did not bring the ultrasound to the operating room. Even in the more recent patients where we have been doing our own ultrasound, we have done that in our office. The ultrasound is portable, obviously, and can be brought to the operating room. We've usually taken the information either from the sestamibi report or from the ultrasound and tried to direct our incision either just above the clavicle or higher for an inferior gland or a little bit higher for a superior gland.