ORIGINAL ARTICLE

Colonic Pacing

A Therapeutic Option for the Treatment of Constipation Due to Total Colonic Inertia

Ahmed Shafik, MD, PhD; Ali A. Shafik, MD; Olfat El-Sibai, MD, PhD; I. Ahmed, MB, BCh, MCh

Hypothesis: The treatment of constipation caused by total colonic inertia is problematic and its results are unsatisfactory. We speculated that colonic pacing would initiate electric activity in the inertial colon and effect rectal evacuation.

Methods: Nine patients with constipation due to total colonic inertia (age range, 39-52 years; 7 women, 2 men) were enrolled in the study. One pacing electrode was applied to each of the 4 potential colonic pacemaker sites, and 2 to 3 temporary recording electrodes were applied distally. A stimulator was embedded subcutaneously in the inguinal area. Home pacing was practiced after patients were trained; the recording electrodes were removed before home pacing was started.

Results: Colonic pacing evoked electric waves, which effected defecation in 6 of the 9 patients. Three of these 6 patients had spontaneous defecation after a few months of pacing, and their electrodes and stimulators were removed. In the other 3 of these 6 patients, the pacemakers are still in place and continue to effect rectal evacuation. Colonic pacing did not produce rectal evacuation in 3 patients and is believed to have failed because of an advanced stage of colonic inertia.

Conclusion: Colonic pacing induced rectal evacuation in 66.6% of the patients with total colonic inertia. No complications were encountered. We suggest that colonic pacing be considered as a new therapeutic option in the treatment of total colonic inertia.

Arch Surg. 2004;139:775-779

From the Department of Surgery and Experimental Research, Faculty of Medicine, Cairo University, Cairo (Drs A. Shafik, A. A. Shafik, and Ahmed), and the Department of Surgery, Faculty of Medicine, Menoufia University, Shebin El-Kom (Dr El-Sibai), Egypt.

Constipation due to colonic inertia is problematic.[1-7] Colonic inertia is a disorder of colonic motility and may be total or segmental.[8-10] Previous studies have shown that the colon normally exhibits electric activity in the form of slow waves, or pacesetter potentials (PPs), and fast activity spikes, or action potentials (APs).[11-18] Action potentials occur randomly and follow, or are superimposed on, the PPs, and they are coupled with elevated colonic pressure. The electric waves are transmitted through smooth muscles of the gut and are partially controlled by intrinsic and extrinsic colonic innervation.[19,20]

A recent study has shown that the colons of patients with colonic inertia do not exhibit electric activity; no PPs or APs were recorded.[21] In a few patients, sporadic electric waves were occasionally registered from the right side of the colon. Because colonic electric activity presumably regulates colonic motility,[14-18] its disorders may impair colonic motility. This is evident from the electrocologram recorded from the various colonic lesions.[17] The diminished frequency, amplitude, and conduction velocity of the electric waves in these conditions are believed to be below the thresholds required for induction and propagation of colonic contraction.

The treatment of colonic inertia presents a problem. The results of medical and surgical therapies are controversial and unsatisfactory.[22-30] Recent experiments may have contributed important findings to this field when they showed the potential existence of at least 4 pacemakers located at the cecal pole, the cecocolonic junction, the midtransverse colon, and the colosigmoid junction.[31] The colonic electric waves started at these sites, and the wave variables differed from one colonic segment to the next.[31] We suggested that the absence of electric waves in colonic inertia is due to disordered colonic pacemakers.[31]

We have recently investigated the parameters necessary for colonic pacing and its effect on colonic electric activity and pressure in patients with constipation resulting from total colonic inertia.[32] On pacing, the colonic pressure rose sig-

©2004 American Medical Association. All rights reserved.
Downloaded From: http://archsurg.jamanetwork.com/ on 05/01/2017

Clinical Data and Method of Evacuation of the 9 Patients With Colonic Inertia Constipation

Patient No./ Sex/Age, y	Stool Frequency, per wk	Duration, y	Evacuation Method
1/F/43	0	23	Laxatives
2/F/39	0-1	15	Enemas
3/F/41	0	21	Laxatives
4/M/38	0	17	Enemas
5/F/50	0	26	Laxatives
6/F/47	0-1	21	Laxatives
7/F/40	0	17	Enemas
8/M/49	0	20	Laxatives
9/F/46	0	17	Laxatives

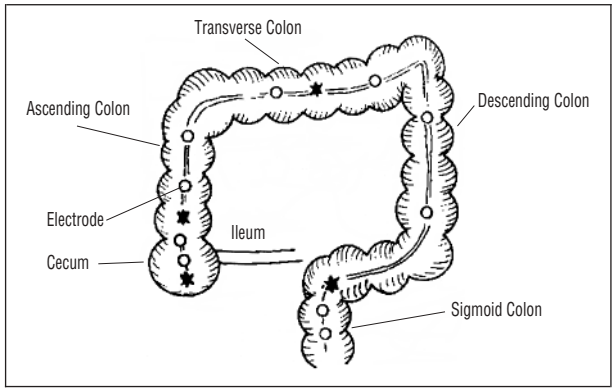

Figure 1. Sites of the electrodes applied to the colon. Stimulating electrodes are marked as stars, and the recording ones as circles.

nificantly with the appearance of electric waves and balloon expulsion. The 4 colonic pacemakers had to be activated for the distended cecal balloon to reach the rectum.

In view of the aforementioned studies, we postulated that colonic pacing could be a method for the treatment of constipation due to total colonic inertia.

METHODS

SUBJECTS

Nine patients (7 women, 2 men) with constipation were enrolled in the study. They were refractory to standard medical therapy. All subjects gave informed consent. Clinical data and the method of bowel evacuation are shown in the **Table**. Results of a physical examination, including neurologic assessment, were normal. Results of laboratory work were unremarkable. Colonoscopy and barium enema studies showed normal findings. Outlet-obstruction constipation was excluded from the normal results of anal manometry, defecography, and electromyography of both the external anal sphincter and the puborectalis muscle. The technique of Hinton and Lennard-Jones[33] was used for measuring the colonic transit time. The patients discontinued the use of laxatives 48 hours prior to the investigation as well as during the investigation. Twenty opaque markers were given before breakfast on the first day. On day 4 and day 6, plain radiograms were taken, and the number of markers on each film was counted. Day 6 revealed the full number of markers distributed throughout the colon from the cecum to the rectum in all 9 patients, indicating colonic inertia. During the course of the disease, this test was performed at least twice in each subject, with similar results. Our faculty review board and ethics committee approved the study.

APPLICATION OF THE ELECTRODES

The subjects fasted 8 hours and underwent bowel evacuation by saline enema. We introduced 28-gauge cardiac pacing electrodes (A&E Medical, Farmingdale, NJ) into the colon endoscopically through the anus under videoscopic and fluoroscopic control and without sedation. One electrode was hooked to the colonic mucosa overlying the potential site of the pacemaker and acted as the pacing (stimulating) electrode. Temporary recording electrodes were hooked to the colonic mucosa and distally to the pacing electrode (**Figure 1**) to register and examine the electric waves evoked on pacing; they were then removed.

For the cecal pacemaker, the pacing electrode was hooked to the cecal pole, and the 2 recording electrodes were hooked to the cecum 2 cm apart and 2 cm distal to the pacing electrode (Figure 1). The pacing electrode for the pacemaker of the ascending colon and the right half of the transverse colon was hooked to the ascending colon just distal to the cecocolonic junction. Three recording electrodes were applied, 2 of these to the ascending colon, 5 cm apart and 5 cm distal to the pacing electrode. The third recording electrode was hooked to the middle of the right half of the transverse colon (Figure 1). The pacing electrode for the transverse colon pacemaker was applied to the mid–transverse colon, and 3 recording electrodes were applied to the left half of the transverse colon and the descending colon in a fashion similar to that used for the ascending colon pacemaker. For the sigmoid colon pacemaker, the pacing electrode was hooked to the sigmoid colon just distal to the colosigmoid junction, and the 2 recording electrodes were hooked to the sigmoid colon 5 cm apart and 5 cm distal to the pacing electrode (Figure 1). The electrode hook penetrated the mucosa and muscularis externa of the gut wall.

Temporary colonic pacing was performed 20 minutes after application of the electrodes to allow the gut to adapt to the applied electrodes. A 60-minute pacing was performed with the 4 pacing electrodes, and the electric signals were recorded. The electrodes located at the potential pacemaker sites were stimulated using an electrical stimulator (model A 310; World Precision Instruments Inc, Sarasota, Fla). The stimulator delivered a series of constant electric current with an amplitude of 5 mA and a pulse width of 200 milliseconds. These parameters had been determined in a recent study.[32] The latency, which is the time lapse from the onset of pacing to the onset of response, was determined.

Waves registered from the recording electrodes were amplified using an alternating current amplifier with a frequency response of within 3 dB from 0.016 Hz to 1 kHz and were displayed on an ultraviolet recorder at a sensitivity of 1 mV/cm.

SUBCUTANEOUS IMPLANTATION OF THE STIMULATOR

When the effect of experimental colonic pacing on the colonic myoelectric activity had been determined and colonic pacing had proved to produce colonic electric activity, all of the recording electrodes were removed, leaving in place only the 4 pacing electrodes at the sites of the potential pacemaker. A stimulator was implanted subcutaneously. The rectum was emptied with a saline enema. The stimulator (Prevail; Medtronic, Minneapolis, Minn) was placed in a subcutaneous pocket in the inguinal area. Four leads were passed subcutaneously from this area to the anal orifice and then to the anal submucosa to be connected with the 4 leads of the electrodes hooked at the 4 potential colonic pacemaker sites.

©2004 American Medical Association. All rights reserved.
Downloaded From: http://archsurg.jamanetwork.com/ on 05/01/2017

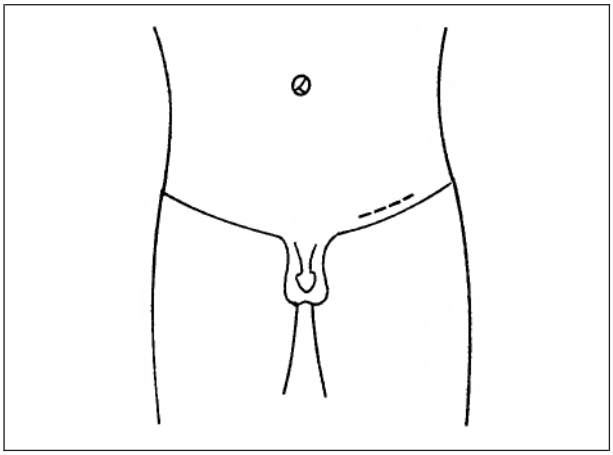

Figure 2. Site of stimulator implantation in the inguinal area.

Under general anesthesia, a 4-cm incision was made 2 cm above and parallel to the middle third of the inguinal ligament (**Figure 2**). A dissection was made in the subcutaneous space to form a pocket for the stimulator. A subcutaneous tunnel was then created by means of a dissecting forceps that passed subcutaneously from the pocket and alongside the scrotum or labium majus to the anal orifice, where a 1-cm incision was made at the mucocutaneous junction (Figure 2). A long artery forceps was passed subcutaneously from this incision until it appeared in the pocket, where the tip of the lead was grasped by the forceps and pulled subcutaneously to come out of the anal incision. The lead then was passed through the subcutaneous space of the anal canal, came out through the lower rectal mucosa, and was connected to the leads of the pacing electrodes. The patient left the hospital after 24 hours and was given analgesics for 1 day and a quinolone antibiotic for 2 days.

HOME PACING

The patients were trained to use colonic pacing at home and were supported by written instructions about its use. They were also asked to submit a daily defecation score form throughout the study period. They were instructed to perform colonic pacing 30 to 60 minutes after breakfast and after lunch and to record the daily number of induced and spontaneous bowel evacuations, as well as the need for resorting to laxatives or enemas. The patients were followed up at twice-monthly intervals to assess the daily recordings and to examine the stimulator and leads.

The results were analyzed statistically using the analysis of variance, and values were given as the mean±SD. Differences assumed significance at $P<.05$.

RESULTS

All the subjects were evaluated. The only adverse effect we encountered was the displacement of some electrodes, which were, however, relocated in their original places with the aid of colonoscopy under fluoroscopic control. The displacement had occurred in the first 3 patients only and were avoided in the following 6 patients of the series.

The electric activity of the colon before colonic pacing showed a silent electrocologram; no electric waves were recorded (**Figures 3**, **4**, **5**, and **6**). On colonic pacing, electric waves in the form of PPs and APs were registered (Figures 3-6). Pacesetter potentials occurred as monopolar, negatively deflected waves. They appeared after a mean latency of 66.2±11.3 seconds (range, 45-90 seconds), and they recorded a mean frequency of 2.8±1.1 cycle/min (range, 2.2-3.4 cycle/min), amplitude of 0.53±0.2 mV (range, 0.2-0.82 mV), and a conduction velocity of 3.2±1.2 milliseconds (range, 2.8-4.6 milliseconds). The PPs had an irregular rhythm (Figures 3-6). They were followed by bursts of APs represented by negative deflections, which occurred randomly and did not follow each PP; in some cases, they were superimposed on the PPs. The wave variables were

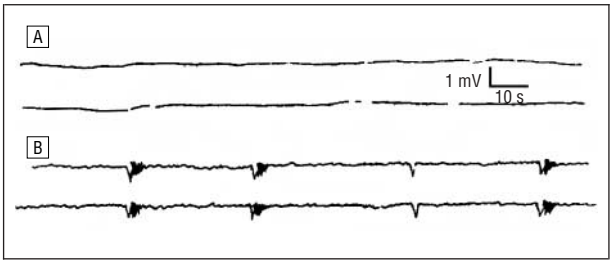

Figure 3. Electric activity of the cecum of a patient with colonic inertia. A, Before pacing, showing no electric activity. B, After pacing, showing pacesetter and action potentials.



Figure 4. Electric activity of the ascending colon of the same patient of Figure 3. A, Before pacing, showing no electric activity. B, After pacing, showing pacesetter and action potentials.

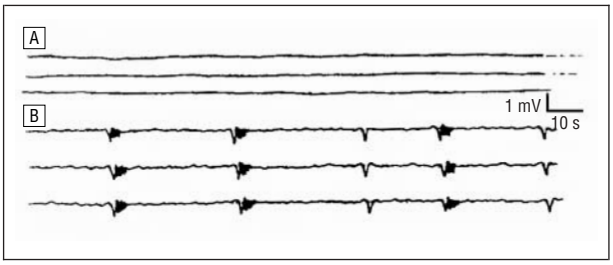

Figure 5. Electric activity of the descending colon of the same patient of Figure 3. A, Before pacing, showing no electric activity. B, After pacing, showing pacesetter and action potentials.

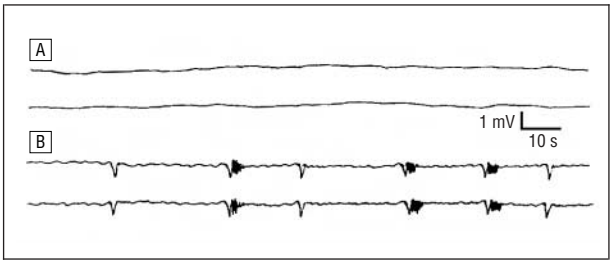

Figure 6. Electric activity of the sigmoid colon of the same patient of Figure 3. A, Before pacing, showing no electric activity. B, After pacing, showing pacesetter and action potentials.

©2004 American Medical Association. All rights reserved.
Downloaded From: http://archsurg.jamanetwork.com/ on 05/01/2017

similar to those from the recording electrodes applied at each of the 4 pacemaker sites, but they differed from one section of the colon to the next (Figures 3-6). When the colonic pacing ceased, the waves disappeared. However, the waves continued discharging for 10 to 20 seconds (mean, 14.6±3.3 seconds) after pacing cessation. The aforementioned wave variables were reproducible from the electrodes of the same subject.

The technique was accepted and well tolerated by the patients. No infection of the electrodes or the stimulators was encountered. Rectal pacing induced rectal evacuation in 6 of the 9 patients with colonic inertia constipation. In 2 of the 6 patients, defecation occurred on the first colonic pacing and on each pacing thereafter. The remaining 4 patients experienced rectal evacuation after 2, 4, 4, and 5 days, respectively, of daily colonic pacing sessions. The frequency of induced defecation per week varied from 6 to 10 (mean, 7.2±1.3). Pacing was performed after breakfast and after lunch. Defecation occurred usually after breakfast pacing and rarely after each pacing. In 3 of the 6 patients, spontaneous defecation without colonic pacing was achieved after pacing periods of 2, 2½, and 4 months. When spontaneous evacuation was achieved, colonic pacing was rarely needed. However, we waited for 3 months after the spontaneous defecation occurred before removing the electrodes and the stimulator. The 3 patients with spontaneous defecation have normal bowel movements to date (9, 13, and 16 months after removal of their pacemakers). The mean defecation frequency per week is 4.2±1.1 (range, 3-6). The other 3 patients who are still applying the colonic pacing (7, 9, and 14 months after application of the pacemaker) are also doing well.

Three patients did not show significant improvement on colonic pacing. The frequency of defecation per week with daily pacing varied from 0 to 1. When we reviewed the history and electric recordings of these 3 patients, we found that they had the longest duration of constipation and the lowest defecation frequency among the 9 patients. Also, the waves recorded upon pacing had a lower frequency, amplitude, and conduction velocity than those of the other 6 patients. The 3 patients asked for removal of the electrodes and stimulators 2½ months after their application.

COMMENT

Total colonic inertia is manifested as constipation and is difficult to treat. The results of medical and surgical treatment are not satisfactory, and the need for other therapeutic modalities is warranted. The current study may shed some light on the treatment of colonic inertia with colonic pacing.

Colonic motility is a function of electric activity. Previous studies[8-10] have associated constipation with impaired colonic motility and abnormal myoelectric activity. In colonic inertia, the absence of electric waves is presumably responsible for the loss of colonic motility and for constipation. We can localize the site of pacemakers, which supposedly evoke the colonic electric waves,[31] but it seems that in colonic inertia, these pacemakers are inactive, and this probably explains the absence of electric activity in colonic inertia.

In the current study, we successfully activated these apparently nonfunctioning pacemakers by stimulation. On stimulation, the electric waves were recorded in all the patients. The improvement of colonic evacuation is presumably related to the improvement of colonic electric activity on colonic pacing. However, the frequency, amplitude, and conduction velocity differed from one patient to the next. For this reason, rectal evacuation was achieved in only 66.6% of the patients. The frequency of defecation matched that reported from the normal volunteers in our laboratory. Although electric activity was initiated after each pacing session and the evoked electric waves were approximately the same, not every pacing succeeded in inducing rectal evacuation. What then could be the cause of the difference in evacuation response to colonic pacing? It is likely that pacing failed to effect rectal evacuation owing to the colon's being empty or containing too little residue. Furthermore, the electric waves evoked by pacing may occasionally be insufficient to produce the rectal motility that effects evacuation.

A constant, diminished electric activity was evident in 3 patients in whom pacing failed to produce rectal evacuation. The cause of this failure is unknown. It might be related to the longer duration of colonic inertia, as reported above, or to the functional pacemaker activity. The latter may be so weakened that the waves evoked by pacing may be unable to induce colonic contraction and evacuation. After prolonged pacing attempts in these patients failed to achieve rectal evacuation, the electrodes and stimulators were removed.

Of the 6 patients who defecated after colonic pacing, 3 reported spontaneous defecation after a few months of colonic pacing and had their pacemakers removed. Repeated stimulation has apparently succeeded in activating the colonic pacemakers to the normal level and in returning them to spontaneous action without stimulation. Furthermore, repeated colonic pacing and the resulting electric activity and colonic contractions probably acted to exercise the colonic musculature and increase its contractile activity. To date, these patients are experiencing spontaneous defecation. Also, the integrity of the colonic wall possibly plays a role in regaining spontaneous defecation. In chronic constipation, colonic muscle inflammation and ulcerations may occur,[34] which could interfere with the spontaneity of defecation after cessation of colonic pacing.

The patients had no difficulty practicing home colonic pacing and had no complications. In the early cases, we encountered the displacement of some electrodes, which could, however, easily be replaced endoscopically; no other complications were encountered. The patients who showed improvement with colonic pacing achieved a substantially better quality of life, especially as they abandoned the use of anticonstipation drugs and enemas.

In conclusion, colonic pacing succeeded in evoking electric waves and inducing rectal evacuation in 6 of 9 patients with total colonic inertia. The pacemaker was removed in 6 patients: 3 after failures and 3 after occurrence of spontaneous defecation. Three patients still have

©2004 American Medical Association. All rights reserved.
Downloaded From: http://archsurg.jamanetwork.com/ on 05/01/2017

their pacemakers functioning and effecting rectal evacuation. Colonic pacing seems to be a promising therapeutic option in the treatment of total colonic inertia. Although the number of studied patients is small, the results warrant attention.

Accepted for publication December 10, 2003.

Margot Yehia and Waltraut Reichelt assisted in preparing the manuscript.

Correspondence: Ahmed Shafik, MD, PhD, Department of Surgery and Experimental Research, Cairo University, 2 Talaat Harb St, Cairo 11121, Egypt (shafik @ahmed-shafik.org).

REFERENCES

1. Krishnamurthy S, Schuffler MD, Rohrmann CA, Pope CE. Severe idiopathic constipation is associated with a distinctive abnormality of the colonic myenteric plexus. *Gastroenterology*. 1985;88:26-34.
2. Park HJ, Kamm MA, Abbasi AM, Talbot IC. Immunohistochemical study of the colonic muscle and innervation in idiopathic chronic constipation. *Dis Colon Rectum*. 1995;38:509-513.
3. Shouten WR, ten Kate FJ, de Graaf EJ, Gilberts EC, Simons JL. Visceral neuropathy in slow transit constipation: an immunohistochemical investigation with monoclonal antibodies against neurofilament. *Dis Colon Rectum*. 1993;36:1112-1117.
4. Porter AJ, Wattchow DA, Hunter A, Costa M. Abnormalities of nerve fibers in the circular muscle of patients with slow-transit constipation. *Int J Colorectal Dis*. 1998;13:208-216.
5. Lincoln J, Growe R, Kamm MA, Burnstock G, Lennard-Jones JE. Serotonin and 5-hydroxyindolocetic acid are increased in the sigmoid colon in severe idiopathic constipation. *Gastroenterology*. 1990;98:1219-1225.
6. Zhao R, Baig MK, Wexner SD, et al. Enterochromaffun and serotonin cells are abnormal for patients with colonic inertia. *Dis Colon Rectum*. 2000;43:858-863.
7. Koch TR, Carney JA, Go L, Go VLW. Idiopathic chronic constipation is associated with decreased colonic vasoactive intestinal peptide. *Gastroenterology*. 1988; 94:300-310.
8. Martelli H, Devroede G, Arhan P, et al. Mechanisms of idiopathic constipation: outlet obstruction. *Gastroenterology*. 1978;75:623-631.
9. Shafik A. Constipation: some provocative thoughts. *J Clin Gastroenterol*. 1991; 13:259-267.
10. Shafik A. Constipation: pathogenesis and management. *Drugs*. 1993;45:528-540.
11. Schang JC, Devroede G. Fasting and postprandial myoelectric spiking in the human sigmoid colon. *Gastroenterology*. 1983;85:1048-1053.
12. Dapoigny M, Trolese JF, Bommerlae G, Tournut R. Myoelectric spiking activity of right colon, left colon and rectosigmoid of healthy humans. *Dig Dis Sci*. 1988; 33:1007-1012.
13. Frexinos J, Bueno L, Fioramonti J. Diurnal changes in myoelectric spiking activity of the human colon. *Gastroenterology*. 1985;88:1104-1110.
14. Garcia D, Hita G, Mompean B, et al. Colonic motility: electric and manometric description of mass movement. *Dis Colon Rectum*. 1991;34:577-584.
15. Bassotti G, Morelli A, Whitehead WE. Abnormal rectosigmoid myoelectric response to eating in patients with severe idiopathic constipation (slow transit type). *Dis Colon Rectum*. 1992;35:753-756.
16. Shafik A. Transcutaneous electrosigmoidography: study of the myoelectric activity of sigmoid colon by surface electrodes. *Front Biosci*. 1996;1:b1-4.
17. Shafik A. Electrosigmoidogram in the various pathologic conditions of the sigmoid colon. *Front Biosci*. 1998;3:b11-14.
18. Shafik A. Electrosigmoidogram, electrorectogram and their relation. *Front Biosci*. 1997;2:b12-16.
19. Shafik A. A study of the origin of the electric activity of the rectum: is it neurogenic or myogenic? *Spinal Cord*. 1998;36:548-553.
20. Shafik A. Origin of rectal electric waves: further study. *Dis Colon Rectum*. 1999; 42:1626-1631.
21. Shafik A, Shafik AA, El-Sibai O, Mostafa RM. Electric activity of the colon in subjects with constipation due to total colonic inertia: an electrophysiologic study. *Arch Surg*. 2003;138:1007-1011.
22. Heine JA, Wong WD, Goldberg SM. Surgical treatment for constipation. *Surg Gynecol Obstet*. 1993;176:403-410.
23. Lubowski DZ, Chen FC, Kennedy ML, King DW. Results of colectomy for severe slow-transit constipation. *Dis Colon Rectum*. 1996;39:23-27.
24. Pemberton JH, Rath DM, Ilstrup DM. Evaluation and surgical treatment of severe chronic constipation. *Ann Surg*. 1991;214:403-413.
25. Piccirillo MF, Reissman P, Wexner SD. Colectomy as treatment for constipation in selected patients. *Br J Surg*. 1995;82:898-901.
26. Pluta H, Bowes KL, Jewell LD. Long-term results of total abdominal colectomy for chronic idiopathic constipation: value of preoperative assessment. *Dis Colon Rectum*. 1996;39:160-163.
27. Preston DM, Hawley PR, Lennard-Jones JE, Todd IP. Results of colectomy for severe idiopathic constipation in women (Arbuthnot Lane's disease). *Br J Surg*. 1984;71:547-552.
28. Beck DE, Jagelman DG, Fazio VW. The surgery of idiopathic constipation. *Gastroenterol Clin North Am*. 1987;16:143-147.
29. Todd IP. Constipation: results of treatment. *Br J Surg*. 1985;72(suppl):S12-S13.
30. Yoshioka K, Keighley MRB. Clinical results of colectomy for severe constipation. *Br J Surg*. 1989;76:600-604.
31. Shafik A, El-Sibai O, Shafik AA. Electrophysiologic identification of the location of the colonic pacemakers: a human study. *Front Biosci*. 2002;7:b1-5.
32. Shafik A, Shafik AA, El-Sibai O, Ahmed I. Colonic pacing in patients with constipation due to colonic inertia. *Med Sci Monit*. 2003;9:CR191-196.
33. Hinton JM, Lennard-Jones JE. Constipation: definition and classification. *Postgrad Med J*. 1968;44:720-733.
34. Corman ML. Disorders of defecation. In: Corman ML, ed. *Colon & Rectal Surgery*. Philadelphia, Pa: Lippincott-Raven;1998:368-400.

©2004 American Medical Association. All rights reserved.
Downloaded From: http://archsurg.jamanetwork.com/ on 05/01/2017