ORIGINAL ARTICLE

Clinicopathologic and Radiopharmacokinetic Factors Affecting Gamma Probe–Guided Parathyroidectomy

Omer Ugur, MD; Murat F. Bozkurt, MD; Erhan Hamaloglu, MD; Cenk Sokmensuer, MD; Ilker Etikan, PhD; Yesim Ugur, MD; Iskender Sayek, MD; Seza A. Gulec, MD

Hypothesis: The kinetics of technetium Tc 99m sestamibi (MIBI) in primary hyperparathyroidism are variable and affected by the cellular size of the abnormal glands, the parathyroid hormone levels, and the functional expression of P-glycoprotein (Pgp). The success of gamma probe–guided parathyroidectomy is closely related to the parathyroid-to-thyroid activity ratio at the time of surgery. Preoperative determination of maximum uptake ratio may improve the surgical outcome.

Design: Thirty-one patients with primary hyperparathyroidism attributed to a solitary parathyroid adenoma (27 patients) or multiglandular hyperplasia (4 patients) underwent dynamic MIBI imaging preoperatively. Maximum MIBI activity and activity elimination half-life in the abnormal parathyroid glands and thyroid glands were measured, and the maximum uptake ratio was calculated. After a second MIBI injection on the day of surgery, all patients underwent gamma probe–guided parathyroidectomy and cervical exploration. Timing of surgery after MIBI injection was individualized according to the optimal time to surgery (time to maximum uptake ratio), which was determined by preoperative scintigraphy. During surgery, the gamma probe was used to measure ex vivo counts of excised lesions and adjacent postexcision normal tissue (background). Image characteristics, MIBI kinetics, and gamma probe findings were correlated with gland volume, oxyphil cell content, Pgp expression, and serum parathyroid hormone levels.

Results: Probe localization of abnormal glands at maximum uptake ratio was successful in all patients. The volume of the parathyroid lesion ranged from 0.03 to 9.8 mL (median, 0.7 mL). Parathyroid maximum MIBI activity correlated with the volume of the gland ($r=0.54$, $P=.002$) and serum parathyroid hormone level ($r=0.58$, $P=.001$). No correlation between maximum MIBI activity and oxyphil cell content or Pgp expression could be demonstrated. Elimination half-life of MIBI from parathyroid inversely correlated with Pgp ($r=-0.36$, $P=.05$). The ex vivo lesion-background count ratio positively correlated with volume of the gland ($r=0.66$, $P=.001$) and parathyroid hormone level ($r=0.48$, $P=.006$). Ex vivo lesion counts and Pgp expression were negatively correlated ($r=-0.37$, $P=.04$).

Conclusions: A strong relationship between volume of the parathyroid gland, serum parathyroid hormone levels, and MIBI uptake exists in primary hyperparathyroidism. Gamma probe–guided localization of abnormal gland(s) can be more successful if surgery is undertaken at maximum uptake ratio. High Pgp expression increases MIBI parathyroid clearance rate, decreases gamma probe counts, and may significantly alter the optimal time to surgery.

Arch Surg. 2004;139:1175-1179

Author Affiliations: Hacettepe University Medical Center, Ankara, Turkey (Drs Omer Ugur, Bozkurt, Hamaloglu, Sokmensuer, Etikan, Yesim Ugur, and Sayek); Department of Surgical Oncology, Goshen Center for Cancer Care, Goshen, Ind (Dr Gulec).

Technetium Tc 99m sestamibi (MIBI) parathyroid imaging and the use of an intraoperative gamma probe have significantly changed the surgical management of patients with primary hyperparathyroidism.[1-5] Gamma probe–guided, minimally invasive parathyroidectomy is being successfully performed as an alternative to traditional bilateral neck exploration because of its advantages, such as shorter operative time and hospital stay and increased cost-effectiveness.[6-8]

Technetium Tc 99m sestamibi is concentrated in thyroid and parathyroid tissue. The basis of MIBI parathyroid imaging is the differential biologic elimination rate of the tracer from parathyroid and thyroid tissues. The exact mechanism(s) for the uptake and washout of MIBI from abnormal and hyperfunctioning parathyroid tissue, however, is unclear.

This study evaluated the correlations between gland size, serum parathyroid hormone (PTH) level, parathyroid gland oxyphil cell content, expression of P-glycoprotein (Pgp) in the parathyroid glands, and MIBI kinetics as well as the impact of these factors on the success of parathyroid imaging and gamma probe–guided parathyroidectomy.

©2004 American Medical Association. All rights reserved.
Downloaded From: http://archsurg.jamanetwork.com/ on 01/16/2017

METHODS

Thirty-one consecutive patients who were referred for surgical treatment of primary hyperparathyroidism between October 2001 and October 2002 (22 women, 9 men; mean age, 50.5 years) were studied. All patients were recruited at the Hacettepe University Medical Center, Ankara, Turkey, with the prior approval of the institutional review board. All patients had elevated levels of intact PTH (mean, 315 pg/mL; range, 75.6-2200 pg/mL; normal range, 10-65 pg/mL). Ultrasonography detected multinodular goitre in 15 patients, and 8 of 31 patients had undergone prior surgery for parathyroid adenoma or nodular thyroid disease.

MIBI PARATHYROID IMAGING PROTOCOL

All patients underwent double-phase MIBI parathyroid scintigraphy preoperatively. The scintigraphy protocol consisted of a dynamic imaging phase and early and delayed static image acquisitions. Dynamic imaging was performed in anterior projection for 30 minutes immediately after intravenous injection of 20 mCi of MIBI (1 frame/min, 30 frames). Early static images then were obtained (300 000 counts/view, anterior and 45° right-and-left anterior oblique neck projections as well as anterior mediastinal images). The preset time needed to achieve sufficient count density for early images was applied for delayed-phase imaging of the same projection of planar images. Single-photon emission computed tomographic imaging was performed with a dual-head gamma camera (64 [32 × 2] frames, 30 seconds each using a matrix of 128 × 128 with a circular orbit of 360°).

IMAGE INTERPRETATION

Technetium Tc 99m sestamibi scans were interpreted by 2 nuclear medicine physicians blinded to the clinical information; consensus was reached by discussion when there was an initial disagreement. Interpretations were reported as negative when there was no focal uptake in dynamic or early images and complete washout of radioactivity from the thyroid, with no focal retention in the neck or the mediastinum. Interpretations were probably positive when focal uptake in dynamic or early images equaled or exceeded thyroid uptake, with an equivalent rate of clearance. Interpretations were definitely positive when focal uptake in dynamic or early images equaled or exceeded thyroid uptake, with a slower rate of clearance on delayed images, or when there was extrathyroidal focal uptake in the neck or the mediastinum. Probably positive and definitely positive readings were accepted as positive results in a sensitivity analysis.

QUANTITATIVE IMAGE ANALYSIS AND DETERMINATION OF KINETIC INDICES

Quantitative analysis was performed by drawing regions of interest over the suspected parathyroid lesion and contralateral normal thyroid tissue. For patients who had negative scintigraphic results, regions of interest were drawn retrospectively by using intraoperative lesion localization findings. Time-activity curves were generated for thyroid and parathyroid uptake and clearance. Maximum MIBI activity, maximum parathyroid-thyroid MIBI uptake ratio (UR_{max}), and activity elimination half-life in the abnormal parathyroid glands and thyroid glands were measured. Clearance from the parathyroid and thyroid glands was measured for 180 minutes and included the 30-minute dynamic imaging. An exponential line of best fit was obtained by regression analysis, and half-life was calculated from the slope of the line using the formula $N = N_0^{e\text{-}kt}$ (where N_0 is the initial uptake, N is the uptake at time t, k is the slope, and e = 2.71828183). The interval between MIBI injection and UR_{max} was defined as the optimal time to surgery.

GAMMA PROBE–GUIDED PARATHYROIDECTOMY

On the day of surgery, the patients received the same dose of MIBI and were taken to the operating room at UR_{max}, determined by preoperative scintigraphy. Prior to skin incision, counts over 4 quadrants in the neck as well as over the mediastinum were obtained using a gamma probe (Neoprobe 2000; Neoprobe Corp, Dublin, Ohio). A standard collar incision was made, and a bilateral cervical exploration was performed using the gamma probe. All suspected tissues/lesions with 20% higher in vivo gamma probe counts relative to contralateral thyroid were excised. Intraoperative ex vivo gamma probe counts from parathyroid lesions were compared with postexcision background counts of the adjacent normal tissue. Histopathological confirmation of a successful parathyroidectomy was obtained intraoperatively by frozen section. Exploration of the neck was terminated after a postresection gamma probe survey.

PATHOLOGIC EVALUATION AND IMMUNOHISTOCHEMISTRY

Histopathological examination revealed solitary parathyroid adenoma in 27 patients (87%) and hyperplasia in 4 patients (13%). There were 3 ectopic parathyroid lesions (1 pretracheal, 2 intrathymic). One patient had synchronous papillary thyroid carcinoma and parathyroid adenoma. All frozen section results were in concordance with permanent section diagnosis. Volume of the parathyroid lesions was calculated using a spheroid volume formula ($V = \pi/6$ height width depth) and expressed as milliliters as previously described.[9]

Specimens were reviewed using standard hematoxylin-eosin technique. The relative abundance of oxyphil cells was expressed as a percentage of total cells. Selected paraffin blocks were used for additional immunohistochemical studies for Pgp (clone JSB1, NCL-JSB1; Novocastra Laboratories, Newcastle upon Tyne, England). Positive reaction for Pgp was determined by cell membrane and cytoplasmic staining. Immunohistochemical results were interpreted by an expert pathologist blinded to clinical information and were reported using a scoring scale described by Beck et al.[10]

STATISTICAL ANALYSIS

The Spearman ρ correlation coefficient for nonparametric variables and the Pearson correlation coefficient were used to determine the relationship of semiquantitative data. Analysis was performed using the Kruskal-Wallis test. Pairwise comparisons were performed with the Mann-Whitney *U* test. Differences between Pgp expression in patients with positive and negative scintigraphic interpretations were assessed by the Fisher exact test or the χ^2 test. Results were considered statistically significant with P values $< .05$. All calculations were obtained using SPSS for Windows, version 10.0 (SPSS Inc, Chicago, Ill).

RESULTS

Preoperative scintigraphy localized parathyroid pathologic features in 26 (87%) of 31 patients. Twenty-three of 26 patients with positive scintigraphic results had solitary adenoma, whereas 3 of 26 had hyperplastic glands. Six (31%) of these 26 patients were reoperative cases. Four

©2004 American Medical Association. All rights reserved.
Downloaded From: http://archsurg.jamanetwork.com/ on 01/16/2017

Table. Technetium Tc 99m Sestamibi (MIBI) Kinetics and Clinicopathologic Correlates

	Parathyroid Maximum MIBI Activity		Parathyroid Half-life		Maximum Uptake Ratio	
	r	*P* Value	*r*	*P* Value	*r*	*P* Value
Lesion size	0.54	.002	0.14	.44	0.56	.001
Parathyroid hormone level	0.58	.001	0.30	.10	0.42	.02
Oxyphil cell content	–0.12	.52	0.15	.44	0.08	.68
P-glycoprotein expression	–0.08	.67	–0.36	.048	–0.04	.84

of 5 patients with negative scintigraphic results had adenomas; the fifth had hyperplasia. Intraoperative probe localization of abnormal glands at UR_{max} was successful in all patients. The mean postoperative serum intact PTH and calcium levels were 48.2 pg/mL and 8.7 mg/dL, respectively. Scintigraphic quantitation correlated well with gamma probe measurements. Mean ± SD surgery time for excision of parathyroid pathologic features (including frozen section) was 78.5 ± 47.8 minutes (median, 60 minutes; range, 15-175 minutes).

IMAGE CHARACTERISTICS AND CLINICOPATHOLOGIC CORRELATES

Lesion volume in patients with probably positive and definitely positive scintigraphic results ranged from 0.03 to 1.55 mL (mean, 0.45 mL) and from 0.13 to 9.8 mL (mean, 1.50 mL), respectively. In patients with false-negative scintigraphic results, lesion volume ranged from 0.11 to 1.3 mL (mean, 0.48 mL). There was no statistically significant difference in lesion volume between positive and negative groups ($z=-1.34$, $P=.20$, Mann-Whitney *U* test). However, nonparametric analysis revealed a weak positive correlation between positive reading and lesion volume ($r=0.45$, $P=.01$). Scintigraphic interpretation strongly correlated with ex vivo parathyroid counts ($r=0.56$, $P=.001$) and with ex vivo parathyroid-background count ratio ($r=0.55$, $P=.001$).

In patients with positive results, the mean PTH level was 351 pg/mL (range, 75-2200 pg/mL). The mean PTH levels for probably positive and definitely positive results were 133 pg/mL (range, 91-211 pg/mL) and 403 pg/mL (range, 75-2200 pg/mL), respectively. In patients with false-negative results, the mean PTH level was 170 pg/mL (range, 101-298 pg/mL). Parathyroid hormone levels were not significantly different between positive and negative groups ($z=-0.38$, $P=.74$).

The mean oxyphil cell content was 19.5% (range, 0%-90%) for positive results, 34.4% (range, 0.1%-70%) for probably positive results, 15.9% (range, 0%-90%) for definitely positive results, and 2% (range, 0.1%-5%) for false-negative results. Oxyphil cell content was highly variable between positive and negative groups, and the difference was not significant ($z=-0.98$, $P=.36$).

In patients with positive and negative results, Pgp expression was also highly variable and not correlated with scintigraphic interpretation (χ^2 test, $P=.46$). Ten patients with positive results had grade 4 (highest staining) Pgp expression, whereas 5 had no Pgp expression (grade 0). Three patients with false-negative results had weak Pgp expression (2 grade 1 and 1 grade 2), and the other 2 had high Pgp expression (grade 4).

MIBI PHARMACOKINETICS AND CLINICOPATHOLOGIC CORRELATES

As shown in the **Table**, maximum MIBI activity strongly correlated with gland volume and serum PTH level but not with oxyphil cell content or Pgp. There was an inverse correlation between half-life and Pgp. Maximum uptake ratio showed a strong positive correlation with maximum MIBI activity ($r=0.69$, $P=.001$) and hence with gland size and serum PTH level. Maximum uptake ratio ranged from 30 minutes to 180 minutes (mean ± SD, 125 ± 35 minutes). In 5 cases (16%), UR_{max} was less than half of the mean. In 1 case, high Pgp expression was associated with a UR_{max} of 30 minutes. **Figure 1** demonstrates representative time-activity curves for parathyroid and thyroid uptake and determination of optimal time to surgery. **Figure 2** shows a strongly positive Pgp immunostain.

INTRAOPERATIVE GAMMA PROBE FINDINGS

The ex vivo parathyroid-background count ratios correlated closely with the preoperatively calculated UR_{max} ($r=0.59$, $P=.001$). Both measurements correlated with gland size ($r=0.66$, $P=.001$) and positive scintigraphic interpretation ($r=0.55$, $P=.001$) as well as with PTH ($r=0.48$, $P=.006$) and maximum MIBI activity ($r=0.47$, $P=.008$). Ex vivo parathyroid counts showed a correlation with scintigraphic interpretation ($r=0.56$, $P=.001$) and gland size ($r=0.38$, $P=.04$). Oxyphil cell content showed no correlation with any of the indices. There was weak inverse correlation between ex vivo parathyroid counts and Pgp expression ($r=-0.37$, $P=.04$).

COMMENT

Minimally invasive parathyroidectomy after preoperative MIBI scintigraphy has replaced traditional 4-gland exploration as the procedure of choice in many institutions, with comparable cure rates.[1,11-15] Intraoperative use of a gamma probe allows a focused exploration through a smaller incision, potentially while the patient is under local anesthesia.[16]

Technetium Tc 99m sestamibi accumulates in thyroid and in parathyroid tissue within minutes after intravenous administration. However, what makes this tracer es-

©2004 American Medical Association. All rights reserved.
Downloaded From: http://archsurg.jamanetwork.com/ on 01/16/2017

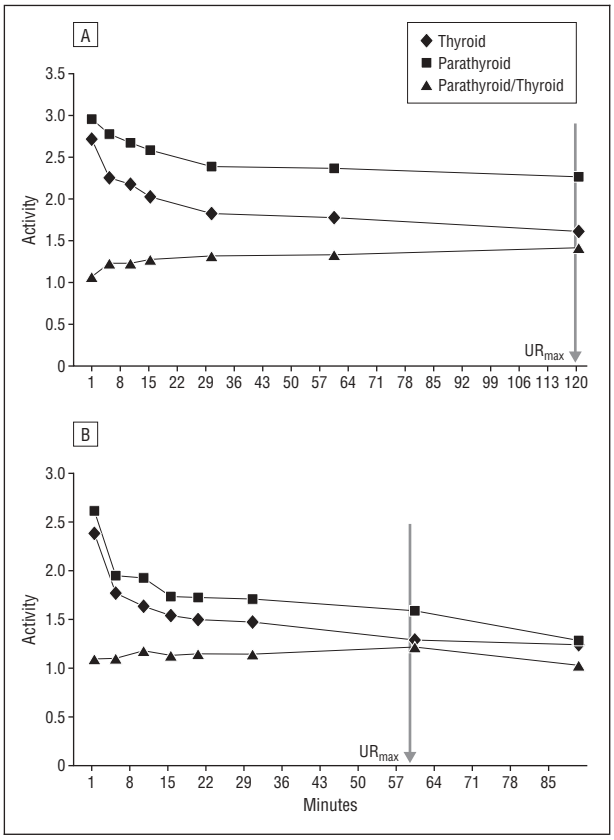

Figure 1. Time-activity curves for parathyroid and thyroid uptake. Note the difference between the maximum uptake ratio in A (120 minutes) and B (60 minutes). Arrow: Time to maximum uptake ratio (UR_{max}).

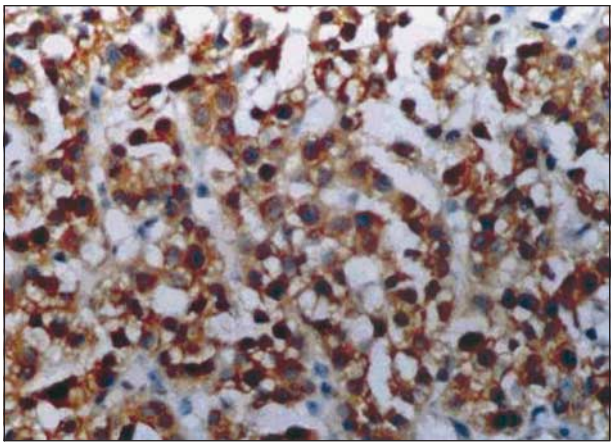

Figure 2. Positive P-glycoprotein immunostaining using immunoperoxidase, background hematoxylin-eosin original magnification × 460.

pecially useful for parathyroid imaging is its much faster release from thyroid than from parathyroid tissue. The uptake and clearance mechanisms of MIBI in abnormal parathyroid tissue are still largely unknown. The localization of MIBI in parathyroid tissue is partly due to blood flow and gland size. This mechanism alone, however, fails to explain the nonvisualization of some large adenomas and occasional detection of very small adenomas or hyperplastic glands.[17-19]

A second mechanism proposed for MIBI localization is related to the cellular mitochondrial content. Hetrakul et al[20] showed that 92% of MIBI retention in human parathyroid adenomas and hyperplastic glands was in the mitochondria and that MIBI retention in the cells was a function of mitochondrial activity. Melloul et al[9] found a high correlation between MIBI uptake ratio of parathyroid lesions and their content of oxyphil cells, which are known to be rich in mitochondria. However, this suggestion could not be substantiated in other studies.[17,21,22] Recent in vitro and in vivo tumor studies have indicated that MIBI, which is a lipophilic cationic agent, is a suitable transport substrate for Pgp.[23,24] P-glycoprotein belongs to a superfamily of adenosine triphosphate–binding transporters; recently a new member of this family called multidrug resistance–associated protein has been cloned. If Pgp mediates drug transport, there should be a connection between Pgp expression and enhanced washout of MIBI from the parathyroid tissue. Reports in the literature regarding the association of Pgp and MIBI uptake/clearance have been conflicting.[17,19,25-27] The discrepancy between these studies may reflect different methodology used in the interpretation of the images and the histopathological findings. Most studies lack quantitative data for uptake and clearance of MIBI. Other studies offer quantitative information based solely on gamma camera imaging. Image-based quantitation alone might be problematic in the presence of nodular thyroid disease. The unique aspect of our study is that the analysis of all major biological factors held responsible in MIBI parathyroid kinetics (both uptake and washout components) used quantitative data from dynamic scintigraphy as well as intraoperative gamma probe measurements. The immunohistochemical technique for evaluation of Pgp expression included the JSB-1 antibody, which has specificity for an internal epitope of Pgp, and a standardized semiquantitative scoring system.[10]

We found no significant correlation between MIBI uptake in parathyroid glands and oxyphil cell content or Pgp expression, but we found a high correlation with gland size and PTH levels. The dynamic image analysis revealed a significant correlation between the rate of MIBI washout from abnormal parathyroid glands and Pgp expression. This relation might be due to an up-regulation of the Pgp system, which normally acts as an out-flux carrier molecule for MIBI in the parathyroid tissue.[18] We have previously shown that an optimal lesion-background ratio is essential for the success of gamma probe–guided parathyroidectomy, and this ratio is highly variable among patients.[28] In the present study, a case with high Pgp expression rapid MIBI washout was associated with a very short (30-minute) optimal time to surgery (time to UR_{max}), which ultimately will affect the success of gamma probe–guided parathyroidectomy. The functional state of the Pgp system might affect the optimal timing of surgery after MIBI injection.

Most clinical protocols for gamma probe–guided, minimally invasive parathyroidectomy require same-day imaging. However, preoperative imaging must be scheduled around the operative procedure, and the unpredictable kinetics of sestamibi hamper the success of gamma probe localization. Repeat injection on the day of surgery without imaging is a potential solution toward optimizing the gamma probe–guided parathyroidectomy technique. This technique can also be applied using a frac-

©2004 American Medical Association. All rights reserved.
Downloaded From: http://archsurg.jamanetwork.com/ on 01/16/2017

tion of standard sestamibi dose, the cost of which may not be a limiting factor.

Norman and Cheda[4] use a single-day protocol in which patients are administered a full imaging dose of MIBI in the nuclear medicine department and undergo parathyroid scintigraphy. Approximately 3 hours after tracer injection, patients undergo gamma probe–guided parathyroidectomy. This protocol offers the advantage of performing both parathyroid scintigraphy and surgery on the same day. On the other hand, it implies that the parathyroid adenoma has already been identified and somewhat localized preoperatively with a prior parathyroid scintigraphy and/or some other imaging modality. However, the parathyroid-to-thyroid ratio might not be optimal at the time of surgery. Casara et al[29] propose the use of a separate-day protocol for parathyroid MIBI scintigraphy. The patients are given a low-dose MIBI on the day of surgery and undergo gamma probe-guided parathyroidectomy within 60 minutes of injection. The advantages of this protocol are a preoperative diagnosis and, thus, a solid surgical plan and avoidance of schedule conflicts with nuclear medicine imaging. However, as with the prior protocol, the parathyroid-to-thyroid ratio might not be optimal at the time of surgery. The major challenge in probe-guided surgery is the target-to-background ratio, which can be optimized by determining the kinetics of the radiopharmaceutical. Our previous study demonstrated that the gamma probe localization success was improved if surgery could be performed when the parathyroid-thyroid uptake ratio was maximal. Also, the average operative time for gamma probe–assisted 4-gland exploration was shorter than the historical control of formal exploration.[28] Therefore, it is expected that the technical performance will be improved with a truly minimally invasive approach.

We conclude that a strong relationship between volume of the parathyroid gland, serum PTH levels, and MIBI uptake exists in primary hyperparathyroidism. Gamma probe–guided localization of abnormal gland(s) can be more successful if surgery is undertaken at UR_{max}. High Pgp expression increases MIBI parathyroid clearance rate, decreases gamma probe counts, and may significantly alter the optimal time to surgery.

Accepted for Publication: April 15, 2004.
Correspondence: Seza A. Gulec, MD, Department of Surgical Oncology, Goshen Center for Cancer Care, 200 High Park Ave, Goshen, IN 46526 (sgulec@goshenhealth.com).
Funding/Support: This study was supported by grant SBAG-AYD-418 from the Scientific and Technical Research Council of Turkey, Ankara, Turkey, and grant 02-T05-101-002 from the Hacettepe University Research Fund, Ankara.

REFERENCES

1. Mariani G, Gulec SA, Rubello D, et al. Preoperative localization and radioguided parathyroid surgery. *J Nucl Med*. 2003;44:1443-1458.
2. Sackett WR, Barraclough B, Reeve TS, Delbridge LW. Worldwide trends in the surgical treatment of primary hyperparathyroidism in the era of minimally invasive parathyroidectomy. *Arch Surg*. 2002;137:1055-1059.
3. Sofferman RA, Nathan MH, Fairbank JT, Foster RS Jr, Krag DN. Preoperative technetium 99m sestamibi imaging: paving the way to minimal-access parathyroid surgery. *Arch Otolaryngol Head Neck Surg*. 1996;122:369-374.
4. Norman J, Cheda H. Minimally invasive radioguided parathyroidectomy facilitated by intraoperative nuclear mapping. *Surgery*. 1997;122:998-1004.
5. Rubello D, Pelizzo MR, Casara D. Nuclear medicine and minimally invasive surgery of parathyroid adenomas: a fair marriage [editorial]. *Eur J Nucl Med Mol Imaging*. 2003;30:189-192.
6. Denham DW, Norman J. Cost-effectiveness of preoperative sestamibi scan for primary hyperparathyroidism is dependent solely upon the surgeon's choice of operative procedure. *J Am Coll Surg*. 1998;186:293-305.
7. Perrier ND, Ituarte PHG, Morita E, et al. Parathyroid surgery: separating promise from reality. *J Clin Endocrinol Metab*. 2002;87:1024-1028.
8. Fahy BN, Bold RJ, Beckett L, Schneider PD. Modern parathyroid surgery: a cost-benefit analysis of localizing strategies. *Arch Surg*. 2002;137:917-922.
9. Melloul M, Paz A, Koren R, et al. Tc-99m-MIBI scintigraphy of parathyroid adenomas and its relation to tumor size and oxyphil cell abundance. *Eur J Nucl Med*. 2001;28:209-213.
10. Beck WT, Grogan TM, Willman CL, et al. Methods to detect P-glycoprotein-associated multidrug resistance in patients' tumors: consensus recommendations. *Cancer Res*. 1996;56:3010-3020.
11. Coakley AJ. Symposium on parathyroid localization. *Nucl Med Commun*. 2003;24:111-113.
12. Norman J, Chheda H, Farrell C. Minimally invasive parathyroidectomy for primary hyperparathyroidism: decreasing operative time and complications while improving cosmetic results. *Am Surg*. 1998;64:391-395.
13. Goss JC, Landerholm R. A changing experience with primary hyperparathyroidism at Group Health Cooperative, Seattle. *Am J Surg*. 2001;181:445-449.
14. Udelsman R. Six hundred fifty six consecutive explorations for primary hyperparathyroidism. *Ann Surg*. 2002;235:665-672.
15. Casara D, Rubello D, Pelizzo MR, Shapiro B. Clinical role of 99mTcO4/MIBI scan, ultrasound and intra-operative gamma probe in the performance of unilateral and minimally invasive surgery in primary hyperparathyroidism. *Eur J Nucl Med*. 2001;28:1351-1359.
16. Chapuis Y, Icard P, Fulla Y, et al. Parathyroid adenomectomy under local anesthesia with intra-operative monitoring of UcAMP and/or 1-84 PTH. *World J Surg*. 1992;16:570-575.
17. Bhatnagar A, Vezza PR, Bryan JA, Atkins FB, Ziessman HA. Technetium-99m-sestaMIBI parathyroid scintigraphy: effect of P-glycoprotein, histology and tumor size on detectability. *J Nucl Med*. 1998;39:1617-1620.
18. Pons F, Torregrosa JV, Fuster D. Symposium on parathyroid localization: biological factors influencing parathyroid localization. *Nucl Med Commun*. 2003;24:121-124.
19. Yamaguchi S, Yachiku S, Hashimato H, et al. Relation between technetium 99m-methoxyisobutylisonitrile accumulation and multidrug resistance protein in the parathyroid glands. *World J Surg*. 2002;26:29-34.
20. Hetrakul N, Civelek AC, Stagg CA, Udelsman R. In vitro accumulation of technetium-99m-sestaMIBI in human parathyroid mitochondria. *Surgery*. 2001;130:1011-1018.
21. Staudenherz A, Abela C, Niederle B, et al. Comparison and histopathological correlation of three parathyroid imaging methods in a population with a high prevalence of concomitant thyroid diseases. *Eur J Nucl Med*. 1997;24:143-149.
22. Ishibashi M, Nishida H, Okuda S, Suekane S, Hayabuchi N. Localization of parathyroid glands in hemodialysis patients using Tc-99m sestaMIBI imaging. *Nephron*. 1998;78:48-53.
23. Rao VV, Chiu ML, Kronauge JF, Piwnica-Worms D. Expression of recombinant human multidrug resistance P-glycoprotein in insect cells confers decreased accumulation of technetium-99m-sestaMIBI. *J Nucl Med*. 1994;35:510-515.
24. Kostakoglu L, Elahi N, Kiratli P, et al. Clinical validation of the influence of P-glycoprotein on technetium-99m-sestaMIBI uptake in malignant tumors. *J Nucl Med*. 1997;38:1003-1008.
25. Sun SS, Shiau YC, Lin CC, Kao A, Lee CC. Correlation between P-glycoprotein (P-gp) expression in parathyroid and Tc-99m MIBI parathyroid image findings. *Nucl Med Biol*. 2001;28:929-933.
26. Mitchell BK, Cornelius EA, Zoghbi S, et al. Mechanism of technetium 99m sestaMIBI parathyroid imaging and the possible role of P-glycoprotein. *Surgery*. 1996;120:1039-1045.
27. Kao A, Shiau YC, Tsai SC, Wang JJ, Ho ST. Technetium-99m methoxyisobutylisonitrile imaging for parathyroid adenoma: relationship to P-glycoprotein or multidrug resistance-related protein expression. *Eur J Nucl Med Mol Imaging*. 2002;29:1012-1015.
28. Bozkurt MF, Ugur O, Hamaloglu E, Sayek I, Gulec S. Optimization of the gamma probe-guided parathyroidectomy. *Am Surg*. 2003;69:720-725.
29. Casara D, Rubello D, Piotto A, Pelizzo MR. 99mTc-MIBI radio-guided minimally invasive parathyroid surgery planned on the basis of a preoperative combined 99mTc-pertechnetate/99mTc-MIBI and ultrasound imaging protocol. *Eur J Nucl Med*. 2000;27:1300-1304.

©2004 American Medical Association. All rights reserved.
Downloaded From: http://archsurg.jamanetwork.com/ on 01/16/2017