

# Preventing Parastomal Hernia With a Prosthetic Mesh

## A Randomized Study

Arthur Jänes, MD; Yucel Cengiz, MD, PhD; Leif A. Israelsson, MD, PhD

**Hypothesis:** Parastomal hernia is a common complication following colostomy. The lowest recurrence rate has been produced when repair is with a prosthetic mesh. This study evaluated the effect on stoma complications of using a mesh during the primary operation.

**Design:** Randomized clinical study.

**Methods:** Patients undergoing permanent colostomy were randomized to have either a conventional stoma or the addition of a mesh placed in a sublay position. The mesh used was a large-pore lightweight mesh with a reduced polypropylene content and a high proportion of absorbable material.

**Results:** Twenty-seven patients had a conventional stoma, and in 27 patients the mesh was used. No infection, fistula formation, or pain occurred (observation time, 12-38 months). At the 12-month follow-up, parastomal hernia was present in 13 of 26 patients without a mesh and in 1 of 21 patients in whom the mesh was used.

**Conclusions:** A lightweight mesh with a reduced polypropylene content and a high proportion of absorbable material placed in a sublay position at the stoma site is not associated with complications and significantly reduces the rate of parastomal hernia.

*Arch Surg.* 2004;139:1356-1358

**A** PARASTOMAL HERNIA MAY be regarded as an incisional hernia related to an abdominal wall stoma.<sup>1</sup> After the construction of a stoma, parastomal hernia has been reported to occur in up to 50% of patients, no matter what modification of the surgical technique is used.<sup>2-17</sup> In 2 studies, a lower rate has been reported with the stoma brought out through the rectus abdominis muscle, although other studies have not confirmed this.<sup>11,17,18</sup>

One third of parastomal hernias require surgical intervention, but even if there are many surgical options available, the results are very disappointing.<sup>17</sup> Thus, recurrence rates of between 30% and 76% have been reported after local aponeurotic repair or stoma relocation.<sup>3,11,17,19-23</sup> Better results have been produced with prosthetic mesh repair.<sup>21-25</sup>

It has been suggested that placing a mesh during the primary operation may reduce the rate of parastomal hernia,<sup>26,27</sup> but there is only 1 nonrandomized study reported.<sup>28</sup> A large-pore lightweight mesh with a reduced polypropylene content and a high proportion of absorbable material, associated with a low degree of inflamma-

tion, is currently available.<sup>23,29</sup> This study evaluated stoma complications in patients randomized to have either a conventional stoma or the same procedure with the addition of the lightweight mesh placed in a sublay position. Early results from this study have previously been reported.<sup>30</sup> Late results from the 12-month follow-up are presented here.

## METHODS

Between January 10, 2001, and March 20, 2003, patients scheduled to have permanent colostomy entered the study. Patients who had a loop enterostoma and those with a very short life expectancy were not included. Patients were randomized to either a conventional stoma through the rectus abdominis muscle or to the same procedure with the addition of a mesh. Randomization was performed by opening consecutively numbered sealed envelopes.

Access to the abdominal cavity was through a midline incision. When a prosthetic mesh was used, it was placed dorsal to the rectus abdominis muscle and anterior to the posterior rectus sheath. The Vypro (Ethicon, Norderstedt, Germany) mesh was cut to 10 × 10 cm in size, and the bowel was brought out through a cross cut in its center. An absorbable stitch fixed the lateral corners of the mesh to the posterior rec-

**Author Affiliations:**  
Department of Surgery, Sundsvalls sjukhus, Sundsvall (Drs Jänes and Cengiz), and Department of Surgery and Perioperative Science, Umeå University, Umeå (Dr Israelsson), Sweden.

tus sheath. The medial corners of the mesh were grasped with a stitch of the running suture closing the midline incision. To prevent the mesh from coming into contact with abdominal contents, peritoneum on the side of the stoma was along the mesh included with the running suture.

Patient age, sex, and body mass index (the weight in kilograms divided by the height in meters squared) were recorded. Whether the operation was an emergency and whether it was for a malignant tumor, diverticulitis of the sigmoid colon or inflammatory bowel disease was recorded. Wound infection and infection associated with the mesh were recorded continually. Patients were examined, straining in both an erect and a supine position, after 1 and 12 months for the presence of a parastomal hernia. A protrusion in the vicinity of the stoma was considered to be a hernia. Pain in the area of the stoma and signs of fistula formation were recorded.

The study was approved by the regional ethics committee. Statistical analysis was performed with SPSS software (SPSS Inc, Chicago, Ill). Mean values and 95% confidence intervals were calculated. The Fisher exact test and the Mann-Whitney *U* test were used to determine statistical significance;  $P < .05$  was considered to be significant. Data were analyzed on an intention-to-treat basis. With a difference of 30% in rates of parastomal hernia and a test power of 80% ( $\alpha = .05$ ), it was determined that each group would require 38 patients.

## RESULTS

Fifty-four patients were included in the study. Twenty-seven patients were randomized to receive the mesh, but in 1 patient a mesh was not used because the posterior rectus sheath could not be dissected free from the muscle because of severe scarring after previous surgery (Figure). Patient and operative characteristics were similar in the 2 groups of patients (Table 1).

No instance of wound infection, infection associated with the mesh, fistula formation, or pain associated with the stoma was recorded in any patient during the observation period of 12 to 38 months (mean, 24 months; 95% confidence interval, 22-27). Within the first year, 7 patients died of malignant disease. Twenty-six patients who had a conventional stoma and 21 with the mesh attended the 12-month follow-up examination. Parastomal hernia was present in 13 patients without a mesh and in 1 of those in whom the mesh was used (Table 2).

## COMMENT

No complication associated with the bowel being brought out through the mesh was recorded, and in particular no infection was encountered. Thus, it seems to be a safe procedure to place a lightweight mesh with a reduced polypropylene content in a sublay position in the vicinity of the bowel. The high rate of parastomal hernia noted in the group of patients who had a conventional stoma is in congruence with previous reports. A very low rate of parastomal hernia was present in the group of patients in whom a mesh was used. Thus, a mesh placed during the primary operation seems to be a safe way to reduce the rate of parastomal hernia.

A parastomal hernia may be regarded as an incisional hernia related to an abdominal wall stoma.<sup>1</sup> It could also

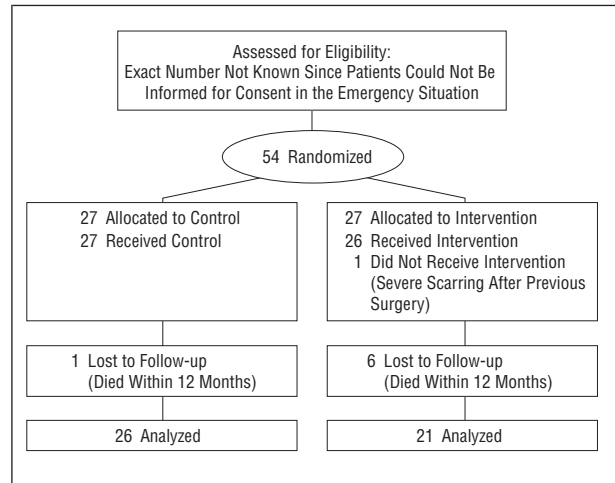


Figure. Checklist for randomized controlled trials.

Table 1. Patient and Operative Characteristics Related to Enterostoma With or Without a Prosthetic Mesh

	No Mesh (n = 27)	Mesh (n = 27)	P Value
Age, y, mean (95% confidence interval)	71 (67-76)	70 (64-75)	.80
Women, No.	11	12	1.0
Body mass index,* mean (95% confidence interval)	27 (25-29)	26 (24-28)	.56
Emergency laparotomy	4	1	.35
Reason for operation			
Malignant tumor	22	25	.42
Diverticulitis of sigmoid colon	3	1	.61
Inflammatory bowel disease	1	1	1.0
Other	1	0	1.0

\*Calculated as the weight in kilograms divided by the height in meters squared.

Table 2. Parastomal Hernia at 12-Month Follow-up

	No Mesh (n = 27)	Mesh (n = 27)	P Value
Died before 12-mo follow-up	1	6	.10
Parastomal hernia	13	1	.00

be claimed that constructing a stoma actually denotes creating an incisional hernia, since it is characterized by abdominal contents protruding through a defect in the abdominal wall. Then a mesh placed during the primary operation when constructing a stoma is in congruence with the repair of an incisional hernia with a mesh.<sup>31,32</sup>

That the mesh was placed outside the abdominal cavity was probably important in terms of the low complication rate, as the only intestine in contact with the mesh is the bowel passing through the abdominal wall. It is technically a very easy and swift procedure to place a mesh in a sublay position. It is a procedure that can be performed in almost all patients. In only 1 patient with se-

vere scarring after previous surgery in the area of the abdominal wall considered appropriate for the colostomy, a mesh could not be used. Because the bowel was always opened, all laparotomies were contaminated. However, because of the difficulty of obtaining informed consent from patients for inclusion in the study in an emergency situation, few laparotomies were severely contaminated.

To assess the long-term rate of complications, these patients will be observed for 5 years. The possibility of late-appearing infection, fistula formation, or the development of strictures can then be evaluated. There is no guidance available from any previous long-term study regarding the appropriate definition of parastomal hernia used at the 12-month follow-up examination. In accordance with the experience with incisional hernia, a wide definition was used in the present study.<sup>33</sup> With a similar definition of incisional hernia used, such hernias are generally detected at the 12-month follow-up, and very few appear later.<sup>33</sup> We do not know if this is also the case with parastomal hernia, but a long term follow-up may provide the answer to this question.

This study had to be stopped because it was determined to be unethical to continue with the randomized study when it became evident that use of the mesh involved a dramatically lower rate of parastomal hernia.<sup>30</sup> We now use a prosthetic mesh for all colostomies, including emergencies, and intend to monitor these patients for 5 years as well. It will then become evident if a low rate of infection is also encountered in patients with gross contamination.

In the mesh used in this study, the absorbable material is a multifilament. In a new mesh now available in Europe and the United States (Ultrapro; Ethicon, Nordstedt, Germany), both materials are monofilaments, which may offer advantages concerning the risk of infection.

We conclude that a lightweight mesh with a reduced polypropylene content and a high proportion of absorbable material placed in a sublay position at the stoma site is not associated with complications and significantly reduces the rate of parastomal hernia.

Accepted for Publication: June 21, 2004.

Correspondence: Arthur Jänes, MD, Kirurgkliniken, Sundsvalls sjukhus, SE-851 86 Sundsvall, Sweden (arthur.janes@lvn.se).

## REFERENCES

- Pearl RK. Parastomal hernias. *World J Surg.* 1989;13:569-572.
- Birnbaum W, Ferrier P. Complications of abdominal colostomy. *Am J Surg.* 1952; 83:64-67.
- Burns FJ. Complications of colostomy. *Dis Colon Rectum.* 1970;13:448-450.
- Abrams BL, Alsikafi FH, Waterman NG. Colostomy: a new look at morbidity and mortality. *Am Surg.* 1979;45:462-464.
- Burgess P, Matthew VV, Devlin HB. A review of terminal colostomy complications following abdominoperineal resection for carcinoma. *Br J Surg.* 1984; 71:1004.
- Cevese PG, D'Amico DF, Biasiato R, et al. Peristomal hernia following end-colostomy: a conservative approach. *Ital J Surg Sci.* 1984;14:207-209.
- Cheung MT. Complications of an abdominal stoma: an analysis of 322 stomas. *Aust N Z J Surg.* 1995;65:808-811.
- Londono-Schimmer EE, Leong AP, Phillips RK. Life table analysis of stomal complications following colostomy. *Dis Colon Rectum.* 1994;37:916-920.
- Ortiz H, Sara MJ, Armendariz P, de Miguel M, Marti J, Chocarro C. Does the frequency of paracolostomy hernias depend on the position of the colostomy in the abdominal wall? *Int J Colorectal Dis.* 1994;9:65-67.
- Pearl RK, Prasad ML, Orsay CP, Abcarian H, Tan AB, Melzl MT. Early local complications from intestinal stomas. *Arch Surg.* 1985;120:1145-1147.
- Sjodahl R, Anderberg B, Bolin T. Parastomal hernia in relation to site of the abdominal stoma. *Br J Surg.* 1988;75:339-341.
- Balslev A. Kolostomitiivaerelse. *Ugeskr Laeger.* 1973;135:2799-2804.
- Stelzner S, Hellmich G, Ludvid K. Die versorgung der Parakolostomiehernie nach Sugarbaker. *Zentralblatt für Chirurgie.* 1999;124(suppl 2):13-17.
- Makela JT, Turko PH, Laitinen ST. Analysis of late stomal complications following ostomy surgery. *Ann Chir Gynaecol.* 1997;86:305-310.
- Everingham L. The parastomal hernia dilemma. *World Counc Enterostomal Therapists J.* 1998;18:32-34.
- Tretbar L. Kirurgi vid stomikomplicationer. *Stomijournalen: Nordisk Tidskrift För Stomi Vård.* 1988;2:10-11.
- Carne PW, Robertson GM, Frizelle FA. Parastomal hernia. *Br J Surg.* 2003;90:784-793.
- Eldrup J, Wied U, Bishoff N, Moller-Pedersen V. Parakolostomihernier: incidens og relation till stomiens placering. *Ugeskr Laeger.* 1982;144:3742-3743.
- Williams JG, Etherington R, Hayward MW, Hughes LE. Paraileostomy hernia: a clinical and radiological study. *Br J Surg.* 1990;77:1355-1357.
- Kronborg O, Kramhøft J, Backer O, Sprechler M. Late complications following operations for cancer of the rectum and anus. *Dis Colon Rectum.* 1974;17: 750-753.
- Martin L, Foster G. Parastomal hernia. *Ann R Coll Surg Engl.* 1996;78:81-84.
- Rubin MS, Schoetz DJ Jr, Matthews JB. Parastomal hernia: is stoma relocation superior to fascial repair? *Arch Surg.* 1994;129:413-418.
- Kasperk R, Klinge U, Schumpelick V. The repair of large parastomal hernias using a midline approach and a prosthetic mesh in the sublay position. *Am J Surg.* 2000;179:186-188.
- Stephenson BM, Phillips RK. Parastomal hernia: local resiting and mesh repair. *Br J Surg.* 1995;82:1395-1396.
- Amin SN, Armitage NC, Abercrombie JF, Scholefield JH. Lateral repair of parastomal hernia. *Ann R Coll Surg Engl.* 2001;83:206-208.
- Rosin JD, Bonardi RA. Paracolostomy hernia repair with Marlex mesh: a new technique. *Dis Colon Rectum.* 1977;20:299-302.
- Light HG. A secure end colostomy technique. *Surg Gynecol Obstet.* 1992;174:67-68.
- Bayer I, Kyzer S, Chaimoff C. A new approach to primary strengthening of colostomy with Marlex mesh to prevent paracolostomy hernia. *Surg Gynecol Obstet.* 1986;163:579-580.
- Schumpelick V, Klosterhafen B, Müller M, Klinge U. Minimized polypropylene meshes for preperitoneal mesh plasty in incisional hernia. *Chirurg.* 1999;70: 422-430.
- Jänes A, Cengiz Y, Israelsson LA. Randomized clinical trial of the use of a prosthetic mesh to prevent parastomal hernia. *Br J Surg.* 2004;91:280-282.
- Luijendijk RW, Hop WCJ, van den Tol MP. A comparison of suture repair with mesh repair for incisional hernia. *N Engl J Med.* 2000;343:392-398.
- Israelsson LA, Jönsson L, Wimo A. Cost analysis of incisional hernia repair by suture or mesh. *Hernia.* 2003;7:114-117.
- Cengiz Y, Israelsson LA. Incisional hernias in midline incisions: an eight-year follow up. *Hernia.* 1998;2:175-177.