ORIGINAL ARTICLE

Laparoscopic Ventral Hernia Repair in Obese Patients

A New Standard of Care

Yuri W. Novitsky, MD; William S. Cobb, MD; Kent W. Kercher, MD; Brent D. Matthews, MD; Ronald F. Sing, DO; B. Todd Heniford, MD

Hypothesis: Ventral abdominal hernias represent a frequent and often formidable clinical problem, especially in obese patients. Because laparoscopic ventral hernia repair (LVHR) results in few complications and a low recurrence rate, the use of minimally invasive techniques in this subgroup of patients may minimize perioperative complications and failure rates.

Design: Retrospective review of prospectively collected data.

Setting: Tertiary care hospital.

Patients: One hundred sixty-three obese patients (body mass index [calculated as weight in kilograms divided by the square of height in meters], ≥30) who underwent LVHR at our institution between July 1, 1998, and December 31, 2003.

Intervention: Laparoscopic ventral hernia repair with an expanded polytetrafluoroethylene mesh.

Main Outcome Measures: Patient age, sex, body mass index, size of fascial defect and mesh, operating time, operative blood loss, length of hospitalization, complications, and hernia recurrences.

Results: Ninety-eight women and 65 men, with a mean body mass index of 38, underwent LVHR. Twenty patients (12.3%) had 21 postoperative complications. There was no perioperative mortality. The mean length of hospital stay was 2.6 days. The recurrence rate was 5.5% at a mean follow-up of 25 months (range, 1-73 months).

Conclusions: A low rate of conversion to laparotomy, minimal perioperative morbidity, and the absence of perioperative mortality in this series indicate the safety of LVHR in obese patients with complex hernias. In addition, a success rate of more than 94.5% suggests improved efficacy of LVHR compared with the historical rates among control subjects undergoing open surgery. In experienced hands, LVHR may be the approach of choice for most patients with a body mass index of 30 or more.

Arch Surg. 2006;141:57-61

Ventral abdominal hernias, both primary and incisional, represent a frequent and often formidable clinical problem. Surgical approaches to ventral herniorrhaphy have been a subject of research and technical modifications for many years. Early reports of primary suture repair were discouraging, with failure rates ranging between 25% and 52%.[1-4] Some authors have called for the abandonment of the suture repair because of frequent recurrences.[3] With the development and popularization of tension-free repairs using prosthetic meshes, the recurrence rates have decreased to less than 20%.[5,6] However, large abdominal incisions and wide tissue dissection with the creation of large flaps often lead to a high incidence of postoperative morbidity and wound complications.[7,8] Recently, open ventral herniorrhaphy has been challenged by reports of successful implementation of minimally invasive techniques. The benefits of laparoscopic ventral hernia repair (LVHR) include a faster convalescence, fewer complications, and, most important, a low recurrence rate.[9-14]

Obesity has long been considered a risk factor for the development of primary and incisional ventral hernias.[15-21] The considerable rates of systemic and wound complications associated with large abdominal incisions in obese patients[17,22-24] are inherent to open herniorrhaphies in this subgroup as well.[7,8,25-28] In addition, ventral hernia repair in the obese population has been marked by a recurrence rate of up to 50%.[2] The use of minimally invasive techniques may minimize perioperative complications and improve failure rates of hernia repair in the obese population. In fact, the efficacy of the laparo-

Author Affiliations: Carolinas Laparoscopic and Advanced Surgery Program, Department of General Surgery, Carolinas Medical Center, Charlotte, NC.

©2006 American Medical Association. All rights reserved.
Downloaded From: http://archsurg.jamanetwork.com/ on 01/20/2017

scopic technique for obese patients undergoing ventral herniorrhaphy has been reported in small series with short follow-up.[29,30] Herein, we report the outcomes and long-term follow-up of a large series of obese patients who underwent LVHR at a tertiary care hospital.

METHODS

At our institution, 278 patients underwent LVHR between July 1, 1998, and December 31, 2003. For each patient, the demographic, perioperative, and postoperative data were collected prospectively and entered into an institutional review board–approved database. The following variables were included: age, sex, body mass index (BMI [calculated as weight in kilograms divided by the square of height in meters]), number of previous abdominal operations and hernia repairs, American Society of Anesthesiologists' (ASA) score, size of fascial defect, size of mesh, operating time, operative blood loss, length of hospitalization, complications, hernia recurrences, and duration of follow-up.

Our surgical technique was described in detail previously.[12] Briefly, a first-generation cephalosporin was given before surgery and was repeated if the operation lasted longer than 2 hours. Pneumoperitoneum was most often created using a cut-down technique in the left subcostal area or with a Veress needle. Three trocars were placed under direct vision laterally along the anterior to midaxillary line. At times, a fourth port was placed contralaterally to facilitate intra-abdominal mesh introduction and fixation. Adhesiolysis was performed sharply, with limited use of electrosurgery or ultrasonic coagulators. Reduction of the hernia contents was performed using blunt graspers and sharp dissection from the inside and manual compression from the outside. The hernia sac was left in situ. The borders of the abdominal wall defect were delineated by means of laparoscopic vision, external palpation, and placement of spinal needles transabdominally at the edges of the hernia defect. A ruler was placed through a 5-mm port, and the dimensions of the hernia defect were measured directly, without pneumoperitoneum reduction. The edges of the hernia were then marked externally. Expanded polytetrafluoroethylene Gore DualMesh Biomaterial; W. L. Gore & Associates, Inc, Flagstaff, Ariz) was then tailored to achieve at least a 4- to 5-cm overlap. Four size-0 permanent sutures were placed at the midpoint of each side of the mesh before it was introduced into the abdominal cavity through a 10-mm trocar site.[31] Once intraperitoneal placement was achieved, the mesh was unrolled, oriented, and secured to the abdominal wall with previously placed sutures. Metal tacks were used circumferentially at approximately 1-cm intervals to prevent intestinal herniation. Additional full-thickness, nonabsorbable sutures were placed every 4 to 6 cm around the circumference of the mesh, tied, and buried subcutaneously. Ten-millimeter trocar sites were closed under direct vision using a suture passer. Drains were not used. Perioperative deep vein thrombosis prophylaxis includes placement of compression stockings and sequential compression devices on both lower extremities. We add a low-molecular-weight heparin treatment for patients with a history of deep vein thrombosis. All patients are aggressively mobilized to ambulate on the day of surgery or the first postoperative day. Routine follow-up evaluation of herniorrhaphy is performed by an attending surgeon at 1 to 2 weeks, 3 months, 6 months, and yearly thereafter.

RESULTS

The 163 patients who met the World Health Organization classification for obesity (BMI, ≥30) underwent LVHR. Patient demographics included the following: mean age, 49 years (age range, 22-71 years); female-male ratio, 98 (60.1%) to 65 (40.0%); and mean ASA score, 2.2. The mean ± SD BMI was 38 ± 7 (range, 30-67). The distribution of patients according to BMI was as follows: 30 to 34.9 (54 patients), 35 to 39 (57 patients), 40 to 49 (44 patients), 50 to 59 (4 patients), and 60 or higher (4 patients). Sixty-seven percent of the patients were morbidly obese (BMI, ≥35).

Most hernias were located at the midline. The locations included the following: center or periumbilical (60 patients), upper midline (56 patients), lower midline (44 patients), right upper quadrant (20 patients), right lower quadrant (18 patients), left upper quadrant (7 patients), left lower quadrant (14 patients), and other (2 patients). Some patients had multiple defects, and Swiss cheese–type defects were described by the location of the predominant defect. The mean defect size was 148 cm^2 (range, 4-880 cm^2). Eighty-nine patients (54.6%) had LVHR following at least 1 previously failed open hernia repair. The patients with recurrent hernias had undergone a mean of 1.9 (range, 1-6) previously failed repairs. The mean mesh size was 424 cm^2 (range, 150-1500 cm^2), for a mean mesh-defect ratio of 2.9:1.

Ninety-seven percent of the herniorrhaphies were completed laparoscopically. Five patients (3.1%) required conversion to laparotomy because of severe adhesions (2 patients), a small-bowel enterotomy (1 patient), inability to reduce incarcerated omentum or bowel (1 patient), and a fistula in previously implanted mesh (1 patient). The mean overall operative time was 178 minutes (range, 33-562 minutes), and the mean estimated blood loss was 55 mL (range, 10-300 mL).

Twenty patients (12.3%) had 21 postoperative complications. These included the following: persistent abdominal discomfort longer than 6 months (6 patients [3.7%]), urinary retention or urinary tract infection (4 patients [2.5%]), pulmonary complications (4 patients [2.5%], mesh infection and trocar site cellulitis (2 patients [1.2%] for each), as well as trocar site hernia, cardiac arrhythmias, and *Clostridium difficile* infection (1 patient [0.6%] for each).

There was no perioperative mortality. Almost all patients developed early postoperative seromas. All were treated conservatively, and each resolved without intervention. The mesh infections in 2 patients necessitated removal of the prosthetic mesh. There were no cases of intestinal fistula formation. Six patients (3.7%) had persistent abdominal discomfort, typically at the site of transabdominal stitches. Each of these patients was treated with a standard subfascial injection of 0.25% bupivacaine hydrochloride, with good results. Two patients had minor wound infections treated with antibiotics.

The mean ± SD length of hospital stay was 2.6 ± 1.6 days (range, 0-10 days). Sixty-one patients (37.4%) were discharged home within 24 hours of surgery (**Figure**). During a mean follow-up of 25 months (range, 1-73 months), recurrent hernias developed in 9 patients (5.5%). The 2 patients whose infected mesh was removed had early recurrences. The mean time to recurrence in our series was 12 months (range, 3-36 months). Only 1 (1.4%) of 74 patients without a previous failed repair had a recurrence. The recurrence rate (94.5%) in the patients with

©2006 American Medical Association. All rights reserved.
Downloaded From: http://archsurg.jamanetwork.com/ on 01/20/2017

previous failed open herniorrhaphies was significantly greater ($P = .04$, Fisher exact test).

COMMENT

The laparoscopic approach to ventral hernia repair has previously been shown to be safe and effective.[10,12,13] Fast functional recovery, combined with low perioperative morbidity and a low recurrence rate, has resulted in widespread adoption of LVHR.[9-13] The procedure has been successfully applied to primary and recurrent hernias, defects in the suprapubic and lumbar areas, and paracolostomy defects.

Obesity is a known risk factor for the development of incisional hernias.[32,33] Impaired visualization, reduced working space, and instrument limitations may predispose obese patients to intraoperative difficulties and conversions to laparatomy.[33-35] Defects in tissue structure and healing,[36] as well as medical comorbidities, are likely contributors to the development of postoperative incisional hernias in obese patients. Fascial closure is also technically more difficult in this population, which may result in suboptimal tissue approximation. The incidence of wound infections, an important risk factor for incisional hernia formation, is also higher in the obese population.[20,24] As a result, general surgeons are seeing a growing number of obese patients with the challenging problem of primary and incisional ventral hernias.

In the past, obesity was considered a relative contraindication to laparoscopy.[30] However, recent studies have found laparoscopy to be superior to open procedures in obese patients undergoing appendectomy,[36] cholecystectomy,[37] gastric bypass,[17] and gastric banding.[38] The use of minimal access techniques for these procedures has resulted in shorter hospital stays and decreased postoperative complications.

The laparoscopic approach to ventral hernia repair may provide obese patients with similar benefits. Raftopoulos et al[30] reported a series of 26 obese patients undergoing LVHR and noted a 20% rate of minor complications and a 4% rate of major complication. Similarly, Birgisson et al[29] reported a 17% rate of minor complications and a 2% rate of major complications in 41 patients with BMI higher than 30. In our series, complications were uncommon, mostly minor in nature, and, more important, self-limiting.

Many patients undergoing ventral herniorrhaphy develop seromas.[7] Regardless of whether a laparoscopic or open approach is used, dissection with or without excision of the hernia sac results in a potential space that is filled with serous fluid in the postoperative period. Such seromas are common and rarely require intervention.[14] In the past, seromas that persisted beyond 6 to 8 weeks after LVHR were considered a complication.[11,14] However, given their common occurrence, self-limiting nature, and the fact that seromas were essentially never reported in the literature describing open ventral hernia repair, we no longer consider seromas as complications unless they require an intervention. Expectant management is our preferred approach to all asymptomatic seromas. We reserve the aspiration of fluid for patients with significant symptoms or for those with seromas that persist for many months. No patients in our series required an intervention for postoperative seroma.

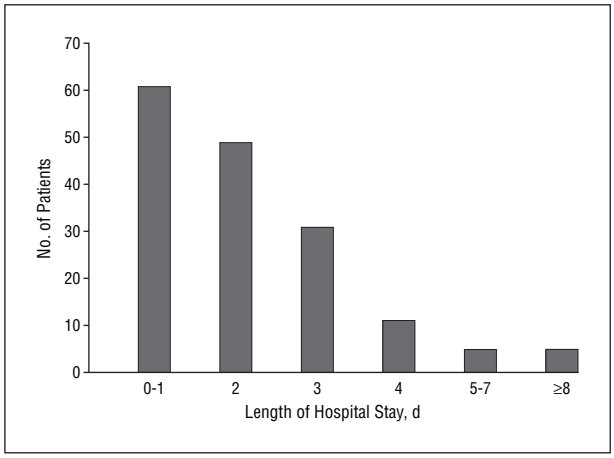

Figure. Length of hospital stay. Only 11.0% of the patients in our series remained in the hospital beyond postoperative day 3.

Persistent discomfort, frequently occurring at the sites of full-thickness transfascial sutures, can most often be effectively treated by an in-office subfascial injection of a long-acting local anesthetic.[39] Few patients report this problem in the long term, and rates following LVHR vary from 2% to 4%.[11-13] Prolonged discomfort is often seen after an open hernia repair,[40,41] but postoperative pain has rarely been included as a complication. It appears that, with the advent of minimal access techniques and heightened patient expectations, surgeons have paid greater attention to even minor incisional discomfort and ways to prevent and treat it.

Bowel injuries during adhesiolysis can be catastrophic, especially if they are missed. One patient in our series had an enterotomy during an extensive adhesiolysis, which was recognized promptly. This patient's operation was completed via a laparotomy, with a good outcome. Enterotomy has been reported in all large series of LVHR, at a rate of 1% to 6% of patients.[12,42-44] Given the complexity of the hernias in the patients in our series, our enterotomy rate of 0.6% appears to be acceptable. Nearly one fifth of open adhesiolysis operations may result in an inadvertent enterotomy.[45] Extensive lysis of adhesions during an open incisional hernia repair also can result in enterotomy.[13] Prompt recognition of a bowel injury is crucial to avoid serious morbidity and death. Management of a recognized intraoperative enterotomy varies according to the type of the injured intestine, extent of the injury, degree of contamination, ability of the surgeon to suture intracorporeally, and type of mesh available.[12,46-48] A small-bowel enterotomy is generally managed via one of the following 3 approaches. In the event of an injury with significant contamination, conversion to laparotomy without mesh placement may be warranted. Another option is primary repair of the injured bowel, completion of adhesiolysis, followed by a delayed (3-6 days) herniorrhaphy. In cases in which a small-bowel enterotomy is promptly recognized and there is minimal contamination, completion of LVHR is undertaken.[12]

The same factors that predispose obese patients to hernia development likely contribute to recurrences. In fact, repair of ventral and incisional hernias in the obese population has traditionally been marked by high failure rates.[16,49,50] Sugerman et al[16] reported obesity to be the greatest risk factor for hernia recurrence. Similarly, Sauerland et al[49] dem-

©2006 American Medical Association. All rights reserved.
Downloaded From: http://archsurg.jamanetwork.com/ on 01/20/2017

onstrated a strong correlation between obesity and recurrences after open incisional hernia repair. Multivariate analysis of their data, although somewhat limited, excluded other factors, such as demographics, comorbidities, hernia size, hernia location, and postoperative complications, as significant contributors to repair failures.

Reports of the efficacy of laparoscopic repairs in obese patients have been mixed. Primary repair without a mesh results in a 22% recurrence rate[51] and should probably be abandoned. Rosen et al[52] reported a 20% recurrence rate in 44 obese patients following LVHR with mesh. Several other investigators reported more successful use of laparoscopy in obese patients. Birgisson et al[29] had 1 recurrence in 46 patients with BMI of 30 or higher, but their follow-up was less than 1 year. Bower et al[53] reported a 4% recurrence in a short-term follow-up of 47 obese and morbidly obese patients. One recurrence was also observed in the small series by Raftopoulos et al[30] after removal of an infected mesh. Unfortunately, the length of follow-up was not reported by that group of investigators. Therefore, the true recurrence rates may have been underestimated by these reports. In our series, the overall recurrence rate (5.5%) was low. Our patients were seen with recurrent hernias as early as 3 months after surgery; 1 recurrence was noted 3 years after surgery. Two of the early recurrences resulted from the removal of infected mesh. Eight of 9 patients who required conversion to laparotomy had recurrences from failed previous open repairs, and 4 of these patients had 3 or more failed open attempts. Our series also confirmed a previously observed greater rate of recurrences in patients who have a history of failed repair attempts.[12,52] In our series, the recurrence rate was only 1.4% in patients undergoing their first hernia repair. Therefore, the laparoscopic approach may be especially advantageous in obese patients with an initial recurrent hernia. This may avoid multiple failures of open herniorrhaphies, which are prone to recurrences even if subsequently approached laparoscopically.

We attribute our low complication and recurrence rates to paying particular attention to several key steps of the operation. First, safe access to the abdominal cavity following previous surgery may be difficult. We used a Veress needle or an open cut-down technique, typically just below the tip of the eleventh rib. Second, extensive adhesiolysis is often required. This is usually accomplished sharply, minimizing the use of electrosurgery or ultrasonic coagulators. Visible vessels are typically controlled with clips. The goal is to eliminate delayed bowel injuries due to the undesired thermal spread from these energy sources. Third, the placement of an adequate prosthesis that allows for an extensive overlap of the abdominal wall defects is mandatory. In this series, we were often required to suture several pieces of mesh together to ensure adequate coverage. As a result, we frequently use meshes of 600 to 800 cm^2 and as large as 1500 cm^2 in this set of patients. Given the mesh-defect ratio of 2.9, we had nearly 3 times as much mesh on the intact abdominal wall as that spanning the defect. We believe that this practice aids in stabilization of the prosthesis and provides a large area for tissue ingrowth into the mesh. Fourth, in addition to 4 nonabsorbable stitches placed at the halfway point of each side of the mesh, we mandate placement of the additional full-thickness abdominal wall stitches circumferentially every 4 to 6 cm. Although these stitches may add to the operating time and provide a source of postoperative discomfort, their use aids in ensuring adequate mesh fixation and reducing mesh migration. If the mesh stays where it is placed during an adequate repair, the recurrence rate should be 0%.

Weight loss may reduce the risk of hernia recurrence in obese patients. Therefore, alternative approaches to the timing of ventral herniorrhaphy have been proposed. First, preoperative behavioral modifications, with resultant weight loss, may reduce the effect of obesity.[54] Second, bariatric surgery may become an important adjunct to the management of some morbidly obese patients. Eid et al[51] reported no recurrences in a small group of patients who underwent laparoscopic gastric bypass with concurrent hernia repair with a biomaterial, but their follow-up was short. More important, deferment of the herniorrhaphy resulted in bowel incarceration in 5 (37.5%) of 14 patients in their series. This has not been the case in our experience. In a group of 24 obese patients with failed hernia repairs, we performed gastric bypass without repair of 1 or more hernias (B.T.H., unpublished data, June 2004). This was because of our fears of contamination of the prosthetic mesh. A planned ventral hernia repair with panniculectomy was performed or planned to be performed 12 to 18 months later, once significant weight loss had occurred. No patient has developed bowel incarceration while awaiting a hernia repair. Although Eid et al recommended hernia repair using a biological mesh at the time of gastric bypass,[51] the lack of use of a permanent prosthesis may predispose to unacceptably high failure rates.[55]

The absence of gastrointestinal tract violation during gastric banding, on the other hand, would allow for the use of a prosthetic mesh. However, the role of adjustable gastric banding in the algorithm of ventral herniorrhaphy has not been investigated beyond an anecdotal report.[56] Hughes et al[57] suggested simultaneous panniculectomy and ventral hernia repair. Although half of their patients developed local wound complications, the hernia recurrence rate was excellent at 3.6% with 1 year of follow-up. A recent report showed a 10% failure of ventral hernia repair performed at the time of abdominoplasty at a mean follow-up of 25 months.[58] Overall, larger series with longer follow-ups are necessary to establish the durability of herniorrhaphy combined with bariatric procedures and abdominoplasties.

CONCLUSIONS

To our knowledge, this article presents outcomes of the largest reported series of obese patients who have undergone LVHR performed by experienced laparoscopic surgeons. Our low rate of conversion to laparotomy, minimal perioperative morbidity, and absence of perioperative mortality indicate the safety of the laparoscopic approach in obese patients with complex hernias. In addition, our success rate of more than 94.5% suggests superior efficacy of the minimally invasive technique compared with the historical rates among control subjects undergoing open surgery. Therefore, we believe that in ex-

©2006 American Medical Association. All rights reserved.
Downloaded From: http://archsurg.jamanetwork.com/ on 01/20/2017

perienced hands LVHR may be the approach of choice for most patients with a BMI of 30 or higher.

Accepted for Publication: April 26, 2005.
Correspondence: B. Todd Heniford, MD, Carolinas Laparoscopic and Advanced Surgery Program, Department of General Surgery, Carolinas Medical Center, PO Box 32861, Charlotte, NC 28232 (Todd.Heniford@carolinashealthcare.org).

REFERENCES

1. Luijendijk RW, Hop WC, van den Tol MP, et al. A comparison of suture repair with mesh repair for incisional hernia. *N Engl J Med*. 2000;343:392-398.
2. Hesselink VJ, Luijendijk RW, de Wilt JH, et al. An evaluation of risk factors in incisional hernia recurrence. *Surg Gynecol Obstet*. 1993;176:228-234.
3. van der Linden FT, van Vroonhoven TJ. Long-term results after surgical correction of incisional hernia. *Neth J Surg*. 1988;40:127-129.
4. Anthony T, Bergen PC, Kim LT, et al. Factors affecting recurrence following incisional herniorrhaphy. *World J Surg*. 2000;24:95-100.
5. Stoppa RE. The treatment of complicated groin and incisional hernias. *World J Surg*. 1989;13:545-554.
6. Rives J, Pire JC, Flament JB, et al. Treatment of large eventrations: new therapeutic indications apropos of 322 cases [in French]. *Chirurgie*. 1985;111:215-225.
7. White TJ, Santos MC, Thompson JS. Factors affecting wound complications in repair of ventral hernias. *Am Surg*. 1998;64:276-280.
8. Leber GE, Garb JL, Alexander AI, Reed WP. Long-term complications associated with prosthetic repair of incisional hernias. *Arch Surg*. 1998;133:378-382.
9. DeMaria EJ, Moss JM, Sugerman HJ. Laparoscopic intraperitoneal polytetrafluoroethylene (PTFE) prosthetic patch repair of ventral hernia. *Surg Endosc*. 2000;14:326-329.
10. Park A, Birch DW, Lovrics P. Laparoscopic and open incisional hernia repair: a comparison study. *Surgery*. 1998;124:816-821.
11. Ramshaw BJ, Esartia P, Schwab J, et al. Comparison of laparoscopic and open ventral herniorrhaphy. *Am Surg*. 1999;65:827-831.
12. Heniford BT, Park A, Ramshaw BJ, Voeller G. Laparoscopic repair of ventral hernias: nine years' experience with 850 consecutive hernias. *Ann Surg*. 2003;238:391-399.
13. Carbajo MA, Martin del Olmo JC, Blanco JI, et al. Laparoscopic treatment vs open surgery in the solution of major incisional and abdominal wall hernias with mesh. *Surg Endosc*. 1999;13:250-252.
14. Heniford BT, Park A, Ramshaw BJ, Voeller G. Laparoscopic ventral and incisional hernia repair in 407 patients. *J Am Coll Surg*. 2000;190:645-650.
15. Regnard JF, Hay JM, Rea S, et al. Ventral incisional hernias: incidence, date of recurrence, localization and risk factors. *Ital J Surg Sci*. 1988;18:259-265.
16. Sugerman HJ, Kellum JM Jr, Reines HD, et al. Greater risk of incisional hernia with morbidly obese than steroid-dependent patients and low recurrence with prefascial polypropylene mesh. *Am J Surg*. 1996;171:80-84.
17. Lujan JA, Frutos MD, Hernandez Q, et al. Laparoscopic versus open gastric bypass in the treatment of morbid obesity: a randomized prospective study. *Ann Surg*. 2004;239:433-437.
18. Pitkin RM. Abdominal hysterectomy in obese women. *Surg Gynecol Obstet*. 1976;142:532-536.
19. Cleveland RD, Zitsch RP III, Laws HL. Incisional closure in morbidly obese patients. *Am Surg*. 1989;55:61-63.
20. Israelsson LA, Jonsson T. Overweight and healing of midline incisions: the importance of suture technique. *Eur J Surg*. 1997;163:175-180.
21. Pans A, Elen P, Dewe W, Desaive C. Long-term results of polyglactin mesh for the prevention of incisional hernias in obese patients. *World J Surg*. 1998;22:479-482.
22. Shenkman Z, Shir Y, Brodsky JB. Perioperative management of the obese patient. *Br J Anaesth*. 1993;70:349-359.
23. Flancbaum L, Choban PS. Surgical implications of obesity. *Annu Rev Med*. 1998;49:215-234.
24. Smith RL, Bohl JK, McElearney ST, et al. Wound infection after elective colorectal resection. *Ann Surg*. 2004;239:599-605.
25. Houck JP, Rypins EB, Sarfeh IJ, et al. Repair of incisional hernia. *Surg Gynecol Obstet*. 1989;169:397-399.
26. Rios A, Rodriguez JM, Munitiz V, et al. Factors that affect recurrence after incisional herniorrhaphy with prosthetic material. *Eur J Surg*. 2001;167:855-859.
27. Rios A, Rodriguez JM, Munitiz V, et al. Antibiotic prophylaxis in incisional hernia repair using a prosthesis. *Hernia*. 2001;5:148-152.
28. Robbins SB, Pofahl WE, Gonzalez RP. Laparoscopic ventral hernia repair reduces wound complications. *Am Surg*. 2001;67:896-900.
29. Birgisson G, Park AE, Mastrangelo MJ Jr, et al. Obesity and laparoscopic repair of ventral hernias. *Surg Endosc*. 2001;15:1419-1422.
30. Raftopoulos I, Vanuno D, Khorsand J, et al. Outcome of laparoscopic ventral hernia repair in correlation with obesity, type of hernia, and hernia size. *J Laparoendosc Adv Surg Tech A*. 2002;12:425-429.
31. Carbonell AM, Matthews BD, Kercher KW, Heniford BT. Technique for introducing large composite mesh while performing laparoscopic incisional hernioplasty [letter]. *Surg Endosc*. 2003;17:1506.
32. Gill IS, Clayman RV, Albala DM, et al. Retroperitoneal and pelvic extraperitoneal laparoscopy: an international perspective. *Urology*. 1998;52:566-571.
33. Mendoza D, Newman RC, Albala D, et al. Laparoscopic complications in markedly obese urologic patients (a multi-institutional review). *Urology*. 1996;48:562-567.
34. Pikarsky AJ, Saida Y, Yamaguchi T, et al. Is obesity a high-risk factor for laparoscopic colorectal surgery? *Surg Endosc*. 2002;16:855-858.
35. Robinson SP, Hirtle M, Imbrie JZ, Moore MM. The mechanics underlying laparoscopic intra-abdominal surgery for obese patients. *J Laparoendosc Adv Surg Tech A*. 1998;8:11-18.
36. Memon MA. Review: laparoscopic appendicectomy: current status. *Ann R Coll Surg Engl*. 1997;79:393-402.
37. Miles RH, Carballo RE, Prinz RA, et al. Laparoscopy: the preferred method of cholecystectomy in the morbidly obese. *Surgery*. 1992;112:818-822.
38. de Wit LT, Mathus-Vliegen L, Hey C, et al. Open versus laparoscopic adjustable silicone gastric banding. *Ann Surg*. 1999;230:800-805.
39. Carbonell AM, Harold KL, Mahmutovic AJ, et al. Local injection for the treatment of suture site pain after laparoscopic ventral hernia repair. *Am Surg*. 2003;69:688-691.
40. Korenkov M, Sauerland S, Arndt M, et al. Randomized clinical trial of suture repair, polypropylene mesh or autodermal hernioplasty for incisional hernia. *Br J Surg*. 2002;89:50-56.
41. Machairas A, Misiakos EP, Liakakos T, Karatzas G. Incisional hernioplasty with extraperitoneal onlay polyester mesh. *Am Surg*. 2004;70:726-729.
42. LeBlanc KA, Booth WV, Whitaker JM, Bellanger DE. Laparoscopic incisional and ventral herniorrhaphy in 100 patients. *Am J Surg*. 2000;180:193-197.
43. Ben-Haim M, Kuriansky J, Tal R, et al. Pitfalls and complications with laparoscopic intraperitoneal expanded polytetrafluoroethylene patch repair of postoperative ventral hernia. *Surg Endosc*. 2002;16:785-788.
44. Egea DA, Martinez JA, Cuenca GM, et al. Mortality following laparoscopic ventral hernia repair: lessons from 90 consecutive cases and bibliographical analysis. *Hernia*. 2004;8:208-212.
45. Van Der Krabben AA, Dijkstra FR, Nieuwenhuijzen M, et al. Morbidity and mortality of inadvertent enterotomy during adhesiotomy. *Br J Surg*. 2000;87:467-471.
46. Franklin ME Jr, Gonzalez JJ Jr, Glass JL. Use of porcine small intestinal submucosa as a prosthetic device for laparoscopic repair of hernias in contaminated fields: 2-year follow-up. *Hernia*. 2004;8:186-189.
47. Ueno T, Pickett LC, de la Fuente SG, et al. Clinical application of porcine small intestinal submucosa in the management of infected or potentially contaminated abdominal defects. *J Gastrointest Surg*. 2004;8:109-112.
48. Carbonell AM, Matthews BD, Dreau D, et al. The susceptibility of prosthetic biomaterials to infection. *Surg Endosc*. 2005;19:430-435.
49. Sauerland S, Korenkov M, Kleinen T, et al. Obesity is a risk factor for recurrence after incisional hernia repair. *Hernia*. 2004;8:42-46.
50. Manninen MJ, Lavonius M, Perhoniemi VJ. Results of incisional hernia repair: a retrospective study of 172 unselected hernioplasties. *Eur J Surg*. 1991;157:29-31.
51. Eid GM, Mattar SG, Hamad G, et al. Repair of ventral hernias in morbidly obese patients undergoing laparoscopic gastric bypass should not be deferred. *Surg Endosc*. 2004;18:207-210.
52. Rosen M, Brody F, Ponsky J, et al. Recurrence after laparoscopic ventral hernia repair. *Surg Endosc*. 2003;17:123-128.
53. Bower CE, Reade CC, Kirby LW, Roth JS. Complications of laparoscopic incisional-ventral hernia repair: experience of a single institution. *Surg Endosc*. 2004;18:672-675.
54. Sugerman H, Windsor A, Bessos M, Wolfe L. Intra-abdominal pressure, sagittal abdominal diameter and obesity comorbidity. *J Intern Med*. 1997;241:71-79.
55. Dayton MT, Buchele BA, Shirazi SS, Hunt LB. Use of an absorbable mesh to repair contaminated abdominal-wall defects. *Arch Surg*. 1986;121:954-960.
56. Bonatti H, Hoeller E, Kirchmayr W, et al. Ventral hernia repair in bariatric surgery. *Obes Surg*. 2004;14:655-658.
57. Hughes KC, Weider L, Fischer J, et al. Ventral hernia repair with simultaneous panniculectomy. *Am Surg*. 1996;62:678-681.
58. Robertson JD, de la Torre JI, Gardner PM, et al. Abdominoplasty repair for abdominal wall hernias. *Ann Plast Surg*. 2003;51:10-16.

©2006 American Medical Association. All rights reserved.
Downloaded From: http://archsurg.jamanetwork.com/ on 01/20/2017