

Image of the Month

C. Clay Cothren, MD; Waleed L. Lutfiyya, MD; Fernando J. Kim, MD; David J. Ciesla, MD

A 30-YEAR-OLD WOMAN PRESENTED TO THE emergency department complaining of left flank pain. She denied associated symptoms and had no previous episodes. Her medical history was remarkable for obesity, non-insulin dependent diabetes mellitus, and a laparoscopic cholecystectomy. Laboratory results were all within normal limits. Computed tomography revealed no acute inflammatory process or renal

stones but did demonstrate a left retroperitoneal mass located separate from but medial to the kidney and below the left renal vein; the mass was solid and well circumscribed, measuring 4.5×3.8 cm (**Figure 1**). Her abdominal pain subsequently resolved and results of workup for a functional endocrine tumor were negative.

What Is the Diagnosis?

- A. Retroperitoneal sarcoma
- B. Lymphoma
- C. Schwannoma
- D. Neurofibroma

Author Affiliations: Department of Surgery, Denver Health Medical Center, and the University of Colorado Health Sciences Center (Drs Cothren, Kim, and Ciesla) and Department of Surgery, Exempla Saint Joseph Hospital (Dr Lutfiyya), Denver.

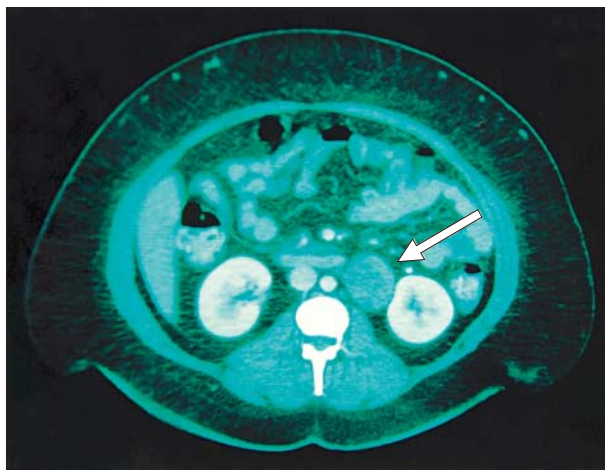


Figure 1. Computed tomographic scan demonstrating a 4.5×3.8 -cm, solid mass (arrow) just below the level of the left renal vein, separate from the kidney and collecting system.