ORIGINAL ARTICLE

Occurrence of Prolonged Injection Site Mass With Methylene Blue but Not Isosulfan Blue After the Sentinel Node Procedure

Gina R. Shirah, MD; Marcia E. Bouton, PA-C; Ian K. Komenaka, MD

Hypothesis: Methylene blue and isosulfan blue perform similarly in the sentinel node procedure.

Design: Retrospective medical record review.

Setting: County hospital with surgical residency.

Patients: A total of 194 patients underwent the sentinel node procedure.

Intervention: Sentinel node procedure with methylene blue or isosulfan blue.

Main Outcome Measures: The identification rate, number of sentinel nodes identified, clinicopathologic variables, adverse effects, and complications were compared between the 2 groups.

Results: The sentinel node identification rate was similar between the 2 groups (99.1% with methylene blue and 100.0% with isosulfan blue). Slightly more sentinel nodes were identified using methylene blue (mean, 2.7 vs 2.1; $P = .03$). No allergic reactions were seen. Significantly more patients experienced a change in pulse oximetry readings, a wider range of pulse oximetry reduction, and a greater mean decrease in pulse oximetry readings with isosulfan blue than with methylene blue. No skin complications were seen in either group. A palpable mass occurred at the site of methylene blue injection in 8.2% of patients.

Conclusions: The sentinel node identification rate was similar with methylene blue and with isosulfan blue. Methylene blue has significant advantages with respect to product cost, absence of anaphylactic reactions, and lack of interference with pulse oximetry. However, awareness is necessary of the possibility of injection site mass after methylene blue injection.

Arch Surg. 2011;146(2):137-141

THE SENTINEL NODE PROCEDURE has become standard practice and has largely replaced axillary dissection as the initial procedure to evaluate lymph nodes in patients with breast cancer. The sentinel node procedure greatly reduces morbidity and cost of lymph node evaluation and allows for more directed histologic analysis of the first-draining lymph nodes.[1,2] Although proponents exist for using the blue dye alone and for using the radioactive isotope alone, a combination technique of using both facilitates mastery of the procedure and has the highest sentinel node identification rates and the lowest false-negative rates.[3-5]

See Invited Critique at end of article

Isosulfan blue was the dye used in initial studies[1,6] of the sentinel node procedure in patients with melanoma and in patients with breast cancer. As a result, isosulfan blue has been used by most surgeons when performing the procedure and was the dye used in prospective clinical trials.[3,7,8] However, isosulfan blue is not without potential complications, as allergic reactions occur in approximately 1% of patients,[5,9] interferes with pulse oximetry readings,[10] and is expensive. As a result, some surgeons have recommended the use of radioactive sulfur colloid alone to circumvent these issues once a surgeon has sufficient experience with the procedure.[4,5,11] Fewer studies[12-19] have reported successful use of methylene blue for the sentinel node procedure. Methylene blue has a significant cost benefit compared with isosulfan blue. In addition, no allergic reactions to methylene blue in the

Author Affiliations:
Department of Surgery, Maricopa Medical Center, Phoenix, Arizona.

©2011 American Medical Association. All rights reserved.
Downloaded From: http://archsurg.jamanetwork.com/ on 04/29/2017

Table 1. Sociodemographics of Patients Undergoing the Sentinel Node Procedure

Variable	Isosulfan Blue Group (n=84)	Methylene Blue Group (n=110)	*P* Value[a]
Age at diagnosis, y			
Mean (SD)	54 (14.0)	51 (11.6)	
<50	34 (40.5)	56 (50.9)	.11
≥50	50 (59.5)	54 (49.1)	
Weight, mean, kg	73.3	74.9	.53
Body mass index, mean (SD)[b]	28.6 (6.9)	30.0 (6.8)	.16
Race/ethnicity, No. (%)			
Non-Hispanic white	45 (53.6)	25 (22.7)	
African American	4 (4.8)	7 (6.4)	<.001
Hispanic	33 (39.3)	74 (67.3)	
Other	2 (2.4)	4 (3.6)	
Employed, No. (%)	14 (16.7)	43 (39.1)	<.001
Insurance, No. (%)			
Commercial	1 (1.2)	3 (2.7)	
Medicare	21 (25.0)	8 (7.3)	.63
AHCCCS, Medicaid	39 (46.4)	42 (38.2)	
None	23 (27.4)	57 (51.8)	
Screening mammogram within 2 y of presentation among those aged ≥40 y, No. (%)	(n=72)	(n=91)	
Yes	28 (38.9)	31 (34.1)	.63
No	44 (61.1)	60 (65.9)	

Abbreviation: AHCCCS, Arizona Health Care Cost Containment System.
[a] Fisher exact test for categorical variables and 2-sample *t* test for continuous variables.
[b] Calculated as weight in kilograms divided by height in meters squared.

sentinel node procedure have been reported to date.[20] However, methylene blue is associated with several risks, particularly skin complications.[5,12,19,20] The present study was performed to evaluate differences in outcomes and complications of the sentinel node procedure using methylene blue vs isosulfan blue.

METHODS

STUDY DESIGN

Institutional review board approval was obtained before the start of the study. A retrospective medical record review was performed of all sentinel node procedures between January 2002 and April 2009 at a single institution. Only patients with operable breast cancer were included in the study. Patients with locally advanced or inflammatory breast cancer (T4) or patients with fixed matted lymph nodes (N2) did not undergo a sentinel node procedure. The procedure was performed using the combination technique with radioactive isotope and blue dye injection. In all patients, the radioactive sulfur colloid injection was performed in the nuclear medicine suite approximately 1 to 7 hours before the sentinel node procedure. Thirty-seven megabecquerels (to convert to millicuries, divide by 37) was diluted in 0.4 mL of normal saline and was injected in divided aliquots at the 12-, 3-, 6-, and 9-o'clock positions in an intradermal periareolar fashion. Between January 1, 2002, and June 30, 2006, patients underwent intraparenchymal injection with isosulfan blue, 1%. Between July 1, 2006, and April 30, 2009, patients underwent intraparenchymal injection with methylene blue, 1%. One patient before July 1, 2006, underwent the procedure with methylene blue and was included in the methylene blue group. Isosulfan blue was not used after June 30, 2006. Three to five milliliters of the blue dye was injected in the operating room after anesthesia had been administered. All nodes that were identified as blue stained, radioactively the hottest, and any node with a radioactive count within 10% of the hottest node were considered sentinel nodes. In addition, any node that was palpably abnormal was considered a sentinel node. A level 1 and level 2 axillary dissection was performed if the sentinel node procedure revealed a positive lymph node. If a micrometastasis (<2 mm) was identified, a complete axillary dissection was preformed at the discretion of the attending surgeon after discussion with the patient. Axillary dissection was not routinely performed if the sentinel node revealed no evidence of carcinoma.

A strict protocol regarding the method of intraoperative analysis of sentinel nodes was not used during the period reviewed. The use of touch imprint or frozen section technique was at the discretion of the attending pathologist. All patients had touch imprint, frozen section, or both techniques performed. Sentinel nodes were routinely bisected along the long axis. For touch imprint preparation, both cut surfaces had touch imprints performed. For frozen section analysis, a section of tissue approximately 2 mm thick from one of the halves was subjected to analysis. The remainder of the tissue was placed in buffered formalin, 10%, and was processed after 12 to 36 hours of fixation. Sentinel nodes were then serially sectioned at a thickness of approximately 2 mm. All sections were embedded in paraffin and stained with hematoxylin-eosin. Immunohistochemical staining for cytokeratins was used in some cases, again at the discretion of the attending pathologist. Tumor foci measuring less than 2 mm were considered micrometastases. If more than 1 area of tumor was identified in a lymph node, this was not considered a micrometastasis regardless of the foci size.

STATISTICAL ANALYSIS

The study population was categorized according to whether the patient underwent the sentinel node procedure with methylene blue or isosulfan blue. Differences in sociodemographic characteristics, clinical measures, and sentinel node procedure results were evaluated. Fisher exact test was used to determine whether differences in categorical variables between the 2 study populations were statistically significant. For continuous variables (eg, age and body mass index), the mean (SD) was reported. A 2-sample *t* test was performed to determine whether differences in continuous variables between the 2 study populations were significant. All significance levels were set at 5%.

RESULTS

Between January 1, 2002, and June 30, 2006, a total of 84 patients underwent the sentinel node procedure using isosulfan blue. Between July 1, 2006, and April 30, 2009, a total of 110 patients underwent the sentinel node procedure using methylene blue. The patients were of comparable age at diagnosis and had similar stage at presentation (**Table 1** and **Table 2**). The pathologic features of the cancers were similar in both groups with respect to histologic type, hormone receptor status, ERBB2 status, and triple-negative cancers (Table 2).

Results of the sentinel node procedure are given in **Table 3**. The sentinel node identification rate was 100.0% in the isosulfan blue group and 99.1% in the methylene blue group ($P>.99$). More sentinel nodes were identified using methylene blue vs isosulfan blue (mean, 2.7

©2011 American Medical Association. All rights reserved.
Downloaded From: http://archsurg.jamanetwork.com/ on 04/29/2017

Table 2. Clinical Characteristics of Patients Undergoing the Sentinel Node Procedure

Variable	No. (%) Isosulfan Blue Group (n=84)	No. (%) Methylene Blue Group (n=110)	*P* Value[a]
Stage at presentation			
0	8 (9.5)	10 (9.1)	.75
I	25 (29.8)	30 (27.3)	
II	49 (58.3)	64 (58.2)	
III	2 (2.4)	6 (5.5)	
Operation			
Lumpectomy	49 (58.3)	81 (73.6)	.03
Mastectomy	35 (41.7)	29 (26.4)	
Predominant histologic type			
Invasive ductal	74 (88.1)	96 (87.3)	>.99
Invasive lobular	1 (1.1)	7 (6.4)	
Ductal carcinoma in situ	5 (6.0)	5 (4.5)	
Other	4 (4.8)	2 (1.8)	
Estrogen receptor status[b]	(n=82)	(n=109)	
Positive	58 (70.7)	76 (69.7)	>.99
Negative	24 (29.3)	33 (30.0)	
Progesterone receptor status[b]	(n=82)	(n=109)	
Positive	47 (57.3)	69 (63.3)	.37
Negative	35 (42.7)	40 (36.7)	
ERBB2 status[c]	(n=76)	(n=105)	
Yes	10 (13.2)	15 (14.3)	>.99
No	66 (86.8)	90 (85.7)	
Triple-negative cancer	14/79 (17.7)	21/105 (20.0)	.85

[a] Fisher exact test.
[b] Two patients in the isosulfan blue group and 1 patient in the methylene blue group did not have hormone receptor status measured.
[c] Formerly HER2/neu. Overexpressed on immunohistochemical analysis or amplified on fluorescence in situ hybridization.

vs 2.1; $P=.03$). The overall rates of positive nodes were 33.3% in the isosulfan blue group and 40.0% in the methylene blue group ($P=.37$).

No allergic reactions after injection in the operating room were seen in either group. In the isosulfan blue group, 88.1% of patients experienced a drop in pulse oximetry readings (Table 3). The mean change was 4%, with a maximum change of 9%. Interference with pulse oximetry occurred in only 50.0% of patients in the methylene blue group ($P<.001$). The mean change in pulse oximetry readings was 1%, with a maximum change of 6% ($P<.001$).

The rates of postoperative infection in the breast and of hematoma were 1.2% in the isosulfan blue group and 1.8% in the methylene blue group (Table 3). Authors of previous studies[12,20] reported skin manifestations of necrosis, ulceration, tattooing, erythema, rash, and telangiectasia or vascular change at the site of methylene blue injection. These were not seen among any patients in this study. However, in 9 of 110 patients (8.2%) in the methylene blue group, a local inflammatory reaction occurred that resulted in no superficial skin changes but caused a palpable mass at the site of injection. No injection site reactions were noted in the isosulfan blue group. In the methylene blue group, the masses were approximately 2 cm, were clearly more prominent than the surrounding breast tissue, and were

Table 3. Results of the Sentinel Node Procedures

Variable	Isosulfan Blue Group (n=84)	Methylene Blue Group (n=110)	*P* Value[a]
Sentinel node identification rate, No. (%)	84 (100.0)	109 (99.1)	>.99
Sentinel nodes identified, mean (SD), No.	2.1 (1.9)	2.7 (2.1)	.03
Positive nodes, No. (%)	28 (33.3)	44 (40.0)	.37
Pulse oximetry			
Patients with change, No. (%)	74 (88.1)	55 (50.0)	<.001
Change in saturated oxygen, mean (range), %	4 (0-9)	1 (0-6)	<.001
Complications, No. (%)			
Infection	1 (1.2)	2 (1.8)	>.99
Hematoma	1 (1.2)	2 (1.8)	>.99
Allergic reaction	0	0	. . .
Tattooing	0	0	. . .
Skin necrosis, ulceration, etc	0	0	. . .
Palpable mass	0	9 (8.2)	.01

[a] Fisher exact test for categorical variables and 2-sample *t* test for continuous variables.

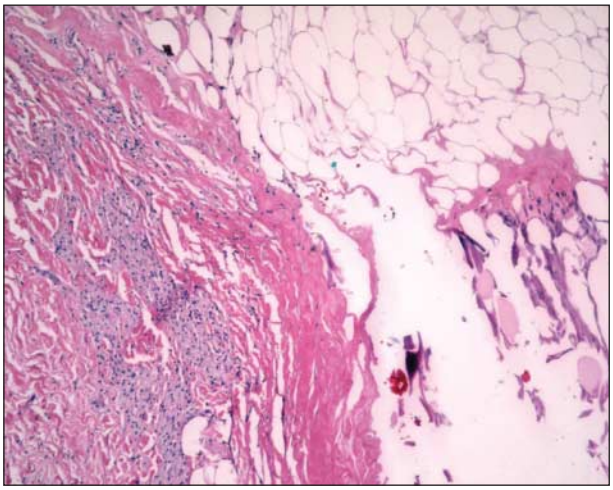

Figure. Fat necrosis at the site of methylene blue injection. A palpable mass following the sentinel node procedure did not resolve after 12 months and was excised, revealing fat necrosis and fibrosis (hematoxylin-eosin, original magnification ×100).

identified at the 1-week postoperative checkup (in 4 patients) or at the first 6-month follow-up visit (in 5 patients). All injection site masses were remote from the location of the cancer. Ultrasonography of the masses was performed in the first 3 patients. The ultrasonogram in 1 patient revealed a hypoechoic mass. Core-needle biopsy specimens were obtained in 3 patients and revealed inflammation and nonatypical hyperplasia in 2 patients. The core-needle biopsy specimen of 1 patient revealed atypical hyperplasia. After 12 months of observation, the mass had not resolved. The patient underwent excisional biopsy in the operating room, and the final pathologic report revealed only fat necrosis and fibrosis (**Figure**). Among the remaining patients, 1 mass resolved after 18 months, and all other masses resolved by 1 year.

©2011 American Medical Association. All rights reserved.
Downloaded From: http://archsurg.jamanetwork.com/ on 04/29/2017

COMMENT

There was no difference in sentinel node identification rates with the use of the 2 dyes, and more sentinel nodes were identified with methylene blue. The main differences in adverse effects were that isosulfan blue interfered with pulse oximetry, whereas methylene blue caused a local reaction that resulted in a palpable mass in a few patients.

Sentinel node evaluation for breast cancer has been successfully performed using isosulfan blue and methylene blue.[10,12,14-17,19,20] Initial studies showed sentinel node identification rates that steadily increased with experience, and more contemporary studies demonstrated identification rates exceeding 95%, with no differences between the 2 dyes.[1-3,12,14,20] Fewer data exist on the use of isosulfan blue and methylene blue in the same study or at the same institution. However, Blessing et al[15] found similar sentinel node identification rates with the 2 dyes; identification rates of 99.1% for methylene blue and 100.0% for isosulfan blue in the present study are consistent with their study. In a review of 24 published studies using isosulfan blue vs methylene blue, sentinel node identification rates (94% vs 93%) were not significantly different between the 2 dyes.[20]

Although sentinel node identification rates were similar in the 2 study groups herein, significantly more sentinel nodes were identified using methylene blue vs isosulfan blue (2.7 vs 2.1, $P = .03$). The reason was unclear. Previous studies[15,18] demonstrated no significant difference in the number of sentinel nodes identified with the 2 dyes. Because the 2 series were performed sequentially in our study, the increased nodes identified with methylene blue may be related to greater surgeon experience with the procedure. Furthermore, the sentinel node procedure has been one of evolution, and other series have identified more nodes over time and with improvement of their technique.[1,21-23]

Specific complications related to blue dye injection have been reported in the sentinel node procedure. Most notably, allergic reactions to isosulfan blue injections occur in approximately 1% of patients.[4,9,24] No allergic reactions occurred among the patients who underwent isosulfan blue injection in our study. This may be explained by the fact that there were fewer patients in the study group. The use of isosulfan blue also interferes with pulse oximetry; the amount of interference is generally predictable.[10] However, this is important because a perceived drop in pulse oximetry may alarm the anesthesia team. Previous series on methylene blue have not documented any change in pulse oximetry readings. The present study is the first to examine changes related to the use of methylene blue and isosulfan blue in the same population. Significantly more patients experienced a change in pulse oximetry readings, a wider range of pulse oximetry reduction, and a greater mean decrease in pulse oximetry readings with isosulfan blue than with methylene blue.

Methylene blue has been in widespread use since the early 1930s and has a broad spectrum of uses.[12,15,19,20] The most common adverse effects after injection for sentinel node identification are skin reactions. Described lesions range from superficial ulceration, temporary tattooing of breast, erythema at the dye injection site, painful inflammatory induration, and flap-site necrosis.[5,12,19,20] Skin reactions typically respond to topical treatment, without the need for surgical intervention. Modifications of injection techniques have lessened these occurrences. Current recommendations suggest deeper nondermal injections to avoid these reactions.[17,18] As described in the "Methods" section herein, all blue dye injections in the present study were performed in an intraparenchymal fashion. As a result, there was no evidence of tattooing or other skin reactions from either dye.

However, in 9 of 110 patients injected with methylene blue, a mass at the injection site was noted after surgery. A mass was considered the result of methylene blue injection because the subareolar intraparenchymal injection site was remote from the site of the cancer and because the mass appeared after surgery. To our knowledge, this finding of an injection site mass has not been previously reported. The known local inflammatory properties of methylene blue that result in skin reactions could explain the occurrence of a mass when the dye is injected into the breast parenchyma. The observation of these masses prompted the performance of core-needle biopsies in the first 3 patients, all of whom had benign findings of inflammation and fat necrosis. One patient had atypical hyperplasia in her core-needle biopsy specimen. She eventually underwent an excision 24 months after her cancer operation because of persistence of the mass. Final pathologic results revealed fat necrosis and fibrosis and no evidence of atypical hyperplasia. These findings support the hypothesis that methylene blue can cause local inflammation. Consistent with dermal injection causing skin reactions, biopsy specimen pathologic findings and excision revealed a similar reaction in the subcutaneous tissue at the injection site. In all but 1 of the other patients with an injection site mass, the masses resolved by 12 months after injection. Although breast density was not recorded in this retrospective study, the mean age of patients in whom an injection site mass occurred was similar to that of the rest of the patients in the methylene blue group (51.6 vs 51.3 years). Two characteristics in this county hospital population that likely differed from previously reported series of methylene blue use were that 67.3% of our patients were Hispanic and 33.6% underwent neoadjuvant chemotherapy. Of 9 patients who developed a palpable mass after injection, 8 were Hispanic and 5 had received neoadjuvant chemotherapy. The finding of a new mass in patients with breast cancer always warrants thorough evaluation. The fact that the masses herein occurred at the documented site of injection provides reassurance of their association with methylene blue injection. Any question as to the location of the injection site or the characterization of the mass necessitates further evaluation via core-needle biopsy and excision if resolution or improvement does not occur. In 2004, the cost of isosulfan blue was $99 for sentinel node mapping.[25] The current cost to our county hospital is $479 for isosulfan blue com-

©2011 American Medical Association. All rights reserved.
Downloaded From: http://archsurg.jamanetwork.com/ on 04/29/2017

pared with $6 for methylene blue. Therefore, isosulfan blue is 80 times more expensive than methylene blue. However, the anxiety related to a persistent injection site mass and the workup cost of a new breast mass must also be factored into the expense.

Limitations of the study include the retrospective nature of the review. In addition, the 2 groups of patients were sequential rather than concurrent, which could explain the different numbers of sentinel nodes identified. Another potential limitation is that the injections were performed at a single institution. Our county hospital population was predominantly Hispanic, which differs from many other patient populations. The technique of sentinel node procedure used at our institution is in accord with what is well described in the literature and was unlikely to be a confounding factor.

In the present study, methylene blue was a satisfactory replacement for isosulfan blue in the identification of sentinel nodes in breast cancer. Because of the significant economic advantage, the absence of anaphylactic reactions, and the lack of interference with pulse oximetry, methylene blue has become the product of choice at our county institution. However, occurrence of an injection site mass after methylene blue injection warrants observation. If the site of injection is unclear or if complete resolution does not occur, further workup is recommended as for any new mass in a patient with breast cancer.

Accepted for Publication: November 20, 2009.
Correspondence: Ian K. Komenaka, MD, Department of Surgery, Maricopa Medical Center, Hogan Bldg, Second Floor, 2601 E Roosevelt St, Phoenix, AZ 85008 (Komenaka@hotmail.com).
Author Contributions: Dr Komenaka had full access to all the data in the study and takes responsibility for the integrity of the data and the accuracy of the data analysis. *Study concept and design:* Bouton and Komenaka. *Acquisition of data:* Komenaka. *Analysis and interpretation of data:* Shirah, Bouton, and Komenaka. *Drafting of the manuscript:* Shirah and Komenaka. *Critical revision of the manuscript for important intellectual content:* Shirah, Bouton, and Komenaka. *Statistical analysis:* Komenaka. *Administrative, technical, and material support:* Shirah, Bouton, and Komenaka. *Study supervision:* Komenaka.
Financial Disclosure: None reported.
Previous Presentation: This study was presented at the 32nd Annual San Antonio Breast Cancer Symposium; December 11, 2009; San Antonio, Texas.

REFERENCES

1. Giuliano AE, Kirgan DM, Guenther JM, Morton DL. Lymphatic mapping and sentinel lymphadenectomy for breast cancer. *Ann Surg*. 1994;220(3):391-401.
2. Veronesi U, Paganelli G, Viale G, et al. A randomized comparison of sentinel-node biopsy with routine axillary dissection in breast cancer. *N Engl J Med*. 2003;349(6):546-553.
3. McMasters KM, Wong SL, Chao C, et al; University of Louisville Breast Cancer Study Group. Defining the optimal surgeon experience for breast cancer sentinel lymph node biopsy: a model for implementation of new surgical techniques. *Ann Surg*. 2001;234(3):292-300.
4. Derossis AM, Fey J, Yeung H, et al. A trend analysis of the relative value of blue dye and isotope localization in 2,000 consecutive cases of sentinel node biopsy for breast cancer. *J Am Coll Surg*. 2001;193(5):473-478.
5. Newman LA. Lymphatic mapping and sentinel lymph node biopsy in breast cancer patients: a comprehensive review of variations in performance and technique. *J Am Coll Surg*. 2004;199(5):804-816.
6. Morton DL, Wen DR, Wong JH, et al. Technical details of intraoperative lymphatic mapping for early stage melanoma. *Arch Surg*. 1992;127(4):392-399.
7. Harlow SP, Krag DN, Julian TB, et al. Prerandomization surgical training for the National Surgical Adjuvant Breast and Bowel Project (NSABP) B-32 trial: a randomized phase III clinical trial to compare sentinel node resection to conventional axillary dissection in clinically node-negative breast cancer. *Ann Surg*. 2005;241(1):48-54.
8. Posther KE, McCall LM, Blumencranz PW, et al. Sentinel node skills verification and surgeon performance: data from a multicenter clinical trial for early-stage breast cancer. *Ann Surg*. 2005;242(4):593-602.
9. Komenaka IK, Bauer VP, Schnabel FR, et al. Allergic reactions to isosulfan blue in sentinel lymph node mapping. *Breast J*. 2005;11(1):70-72.
10. El-Tamer M, Komenaka IK, Curry S, Troxel AB, Ditkoff BA, Schnabel FR. Pulse oximeter changes with sentinel lymph node biopsy in breast cancer. *Arch Surg*. 2003;138(11):1257-1260.
11. Veronesi U, Paganelli G, Viale G, et al. Sentinel-lymph-node biopsy as a staging procedure in breast cancer: update of a randomised controlled study. *Lancet Oncol*. 2006;7(12):983-990.
12. Zakaria S, Hoskin TL, Degnim AC. Safety and technical success of methylene blue dye for lymphatic mapping in breast cancer. *Am J Surg*. 2008;196(2):228-233.
13. Simmons RM, Smith SM, Osborne MP. Methylene blue dye as an alternative to isosulfan blue dye for sentinel lymph node localization. *Breast J*. 2001;7(3):181-183.
14. Simmons R, Thevarajah S, Brennan MB, Christos P, Osborne M. Methylene blue dye as an alternative to isosulfan blue dye for sentinel lymph node localization. *Ann Surg Oncol*. 2003;10(3):242-247.
15. Blessing WD, Stolier AJ, Teng SC, Bolton JS, Fuhrman GM. A comparison of methylene blue and Lymphazurin in breast cancer sentinel node mapping. *Am J Surg*. 2002;184(4):341-345.
16. Nour A. Efficacy of methylene blue dye in localization of sentinel lymph node in breast cancer patients. *Breast J*. 2004;10(5):388-391.
17. Golshan M, Nakhlis F. Can methylene blue only be used in sentinel lymph node biopsy for breast cancer? *Breast J*. 2006;12(5):428-430.
18. Eldrageely K, Vargas MP, Khalkhali I, et al. Sentinel lymph node mapping of breast cancer: a case-control study of methylene blue tracer compared to isosulfan blue. *Am Surg*. 2004;70(10):872-875.
19. Varghese P, Abdel-Rahman AT, Akberali S, Mostafa A, Gattuso JM, Carpenter R. Methylene blue dye: a safe and effective alternative for sentinel lymph node localization. *Breast J*. 2008;14(1):61-67.
20. Thevarajah S, Huston TL, Simmons RM. A comparison of the adverse reactions associated with isosulfan blue versus methylene blue dye in sentinel lymph node biopsy for breast cancer. *Am J Surg*. 2005;189(2):236-239.
21. Hansen NM, Grube B, Ye X, et al. Impact of micrometastases in the sentinel node of patients with invasive breast cancer. *J Clin Oncol*. 2009;27(28):4679-4684.
22. Martin RC, Derossis AM, Fey J, et al. Intradermal isotope injection is superior to intramammary in sentinel node biopsy for breast cancer. *Surgery*. 2001;130(3):432-438.
23. Naik AM, Fey J, Gemignani M, et al. The risk of axillary relapse after sentinel lymph node biopsy for breast cancer is comparable with that of axillary lymph node dissection: a follow-up study of 4008 procedures. *Ann Surg*. 2004;240(3):462-471.
24. Albo D, Wayne JD, Hunt KK, et al. Anaphylactic reactions to isosulfan blue dye during sentinel lymph node biopsy for breast cancer. *Am J Surg*. 2001;182(4):393-398.
25. Dan AG, Saha S, Monson KM, et al. 1% Lymphazurin vs 10% fluorescein for sentinel node mapping in colorectal tumors. *Arch Surg*. 2004;139(11):1180-1184.

©2011 American Medical Association. All rights reserved.
Downloaded From: http://archsurg.jamanetwork.com/ on 04/29/2017