Answer

Isolated Common Hepatic Duct Injury with Anomalous Right Hepatic Duct Anatomy

Subsequent operative exploration of the common bile duct in this patient demonstrated an anomalous right posterior sectoral hepatic duct that inserted inferior to the cystic duct. Multiple laparoscopic surgical clips occluded the common hepatic duct at the level of the junction between the left hepatic and right anterior sectoral ducts. During operation, choledochoscopy (**Figure 3**) was performed to confirm the biliary anatomy. Operative repair involved excision of the extrahepatic bile ducts, cholangioplasty of the right posterior and common hepatic ducts, and reconstruction of biliary continuity with a Roux-en-Y hepaticojejunostomy.

Although concurrent diagnoses (anxiety, depression, and chronic back pain) complicated the clinical picture, our patient's chronic symptomatic biliary stricture resulted from a bile duct injury during laparoscopic cholecystectomy more than 1 year prior. The expected rate of bile duct injury following this procedure approximates 0.4%.[1] This represents a 2- to 4-fold increased risk over open cholecystectomy.[1] Although few injuries (less than one-third) are identified during the initial operation, most are detected within either 30 days or 1 year.[2] Patients with delayed diagnoses are typically readmitted to the hospital with mild symptoms of nausea, vomiting, and low-grade abdominal pain. Injuries are most frequently (97%) the direct result of visual perception illusions by the surgeon.[3]

Thorough preoperative cholangiography that completely defines all bile duct anatomy is essential for a successful reconstruction following major bile duct injuries.[4] Patients also frequently have poor quality of life until the injury is repaired.[5] Even after successful reconstruction, however, patient scores remain lower in psychological domains (but not social or physical domains) compared with healthy controls. Our case displays a typically underappreciated pattern of major bile duct injury. This patient benefited from an anomalous right posterior sectoral hepatic duct that inserted inferior to the common hepatic duct injury.

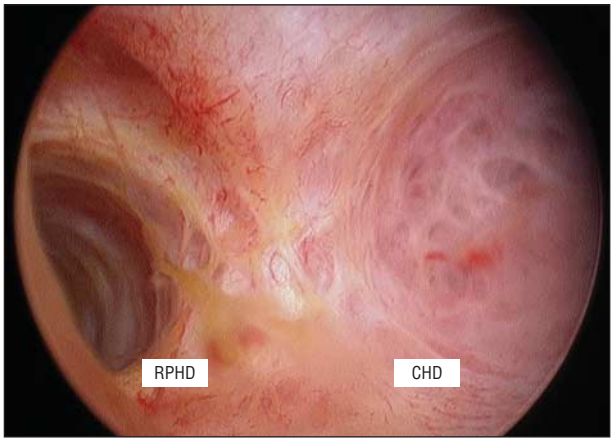

Figure 3. Occlusion of the common hepatic duct (CHD) with a patent anomalous right posterior sectoral hepatic duct (RPHD) during intraoperative choledochoscopy.

Accepted for Publication: April 29, 2010.
Correspondence: Chad G. Ball, MD, 545 Barnhill Dr, Emerson Hall 203, Indianapolis, IN 46202 (ball.chad@gmail.com).
Author Contributions: *Study concept and design:* Ball, House, and Lillemoe. *Acquisition of data:* Ball, House, and Lillemoe. *Analysis and interpretation of data:* Ball, House, and Lillemoe. *Drafting of the manuscript:* Ball, House, and Lillemoe. *Critical revision of the manuscript for important intellectual content:* Ball, House, and Lillemoe. *Statistical analysis:* Ball and Lillemoe. *Obtained funding:* Ball and Lillemoe. *Administrative, technical, and material support:* Ball, House, and Lillemoe. *Study supervision:* Ball, House, and Lillemoe.
Financial Disclosure: None reported.

REFERENCES

1. Lillemoe KD. Current management of bile duct injury. *Br J Surg.* 2008;95(4):403-405.
2. Lillemoe KD, Martin SA, Cameron JL, et al. Major bile duct injuries during laparoscopic cholecystectomy: follow-up after combined surgical and radiologic management. *Ann Surg.* 1997;225(5):459-471.
3. Way LW, Stewart L, Gantert W, et al. Causes and prevention of laparoscopic bile duct injuries: analysis of 252 cases from a human factors and cognitive psychology perspective. *Ann Surg.* 2003;237(4):460-469.
4. Stewart L, Way LW. Bile duct injuries during laparoscopic cholecystectomy: factors that influence the results of treatment. *Arch Surg.* 1995;130(10):1123-1129.
5. Melton GB, Lillemoe KD, Cameron JL, Sauter PA, Coleman J, Yeo CJ. Major bile duct injuries associated with laparoscopic cholecystectomy: effect of surgical repair on quality of life. *Ann Surg.* 2002;235(6):888-895.

Submissions

The Editor welcomes contributions to the Image of the Month. Manuscripts should be submitted via our online manuscript submission and review system (http://manuscripts.archsurg.com). Articles and photographs accepted will bear the contributor's name. Manuscript criteria and information are per the Instructions for Authors for Archives of Surgery (http://archsurg.ama-assn.org/misc/ifora.dtl). No abstract is needed, and the manuscript should be no more than 3 typewritten pages. There should be a brief introduction, 1 multiple-choice question with 4 possible answers, and the main text. No more than 2 photographs should be submitted. There is no charge for reproduction and printing of color illustrations.

©2011 American Medical Association. All rights reserved.
Downloaded From: http://archsurg.jamanetwork.com/ on 01/17/2017