Answer

Adrenal Myelolipoma

The mass (**Figure 3**) was macroscopically of variegated appearance with dark red hemorrhagic and yellow fatty areas. Microscopically, it consisted of nodular fatty soft tissue mainly in the lobules, with necrotic fat tissue and scattered islets of hematopoietic tissue consistent with myelolipoma. The lesion also contained more typical adrenal tissue with replacement by adipocytes and similar hematopoietic cells.

Myelolipomas are benign neoplasms composed of mature adipose tissue and hematopoietic elements. The incidence is 0.06% to 0.2%[1] at autopsy. Most myelolipomas arise from adrenal glands; however, they can arise extra-adrenally from presacral tissue, retroperitoneum, muscle fascia, mediastinum, stomach, and liver. Most myelolipomas are discovered incidentally and are small, solitary, and asymptomatic. They are usually unilateral but occur equally on each side. Occasionally, they can be bilateral and multifocal or can grow to giant proportions such as this one. The tumors are circumscribed but not encapsulated. The gross appearance varies from yellow to red-brown, depending on the proportion of myeloid cells. On microscopic examination, they are composed of mature adipose tissue and hematopoietic cells. Occasionally, foci of bony metaplasia, infarction, and hemorrhage can be seen.

Myelolipomas do not undergo malignant transformation; however, they can rupture, either spontaneously or with trauma, to produce retroperitoneal hemorrhage.[2] They can cause tumor necrosis symptoms, mechanical compression, and hematuria. Large lesions may require adrenalectomy to prevent the risk of rupture. Cases of adrenal myelolipomas causing adrenocortical hypersecretion have also been reported in association with Cushing syndrome,[3] Conn syndrome, and congenital adrenal hyperplasia.

A widely accepted explanation of their cause is that myelolipomas occur in the adrenals as metaplasia of the reticuloendothelial cells of blood capillaries in response to stress.[4] Abnormal stimulation by the pituitary-adrenal axis may also have a role in their pathogenesis.

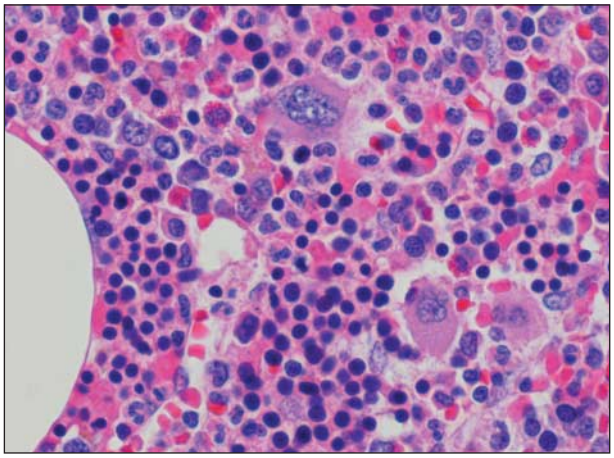

Figure 3. Adrenal myelolipoma with hematopoietic tissue, including megakaryocytes and erythroid and myeloid precursors (hematoxylin-eosin, original magnification ×400).

When an adrenal incidentaloma is discovered on imaging, it is imperative to discover whether it is malignant and functional. The imaging modality of choice for investigating adrenal lesions is CT[4]; however, in large lesions such as this, MRI can add information about the tissue planes, site of origin, and surgical strategy. Both CT and MRI, using criteria such as focal fatty density within the lesion, are accurate in predicting whether an adrenal lesion is benign.[5] If the Hounsfield units are less than 10, it is almost certainly a benign fatty lesion, which can be followed up with interval imaging. Occasionally, the percentage of fat in a myelolipoma will be lower with the more solid hemopoietic component, making diagnosis on imaging difficult and indicating surgical excision. Ultrasonography may discover these lesions but is not used routinely to classify adrenal lesions. Needle biopsy of adrenal lesions suggestive of disease is controversial because of the potential risk of seeding.

To test whether an adrenal lesion is functional, physicians should perform an overnight dexamethasone suppression test to detect subclinical Cushing syndrome; measurement of 24-hour urinary catecholamines and metanephrines can detect pheochromocytoma, and morning plasma aldosterone and renin activity tests can detect primary aldosteronism.[6]

If an adrenal lesion can comfortably be described as benign by the radiologists, then interval scanning at 6, 12, and 24 months is appropriate. However, if the lesion is functioning or suggestive of a malignant tumor, surgery should be considered.[6]

Accepted for Publication: April 18, 2011.
Correspondence: Dr Bradbury, Toowoomba Hospital, 18 Chesterfield Rd, Toowoomba, NS 0810, Queensland, Australia.
Author Contributions: *Study concept and design:* Bradbury and Lambrianides. *Acquisition of data:* Bradbury, O'Loughlin, and Manawwar. *Analysis and interpretation of data:* Bradbury. *Drafting of the manuscript:* Bradbury and Manawwar. *Critical revision of the manuscript for important intellectual content:* Lambrianides and O'Loughlin. *Administrative, technical, and material support:* Bradbury and Manawwar. *Study supervision:* Lambrianides and O'Loughlin.
Financial Disclosure: None reported.

REFERENCES

1. Lam KY, Lo CY. Adrenal lipomatous tumours: a 30 year clinicopathological experience at a single institution. *J Clin Pathol.* 2001;54(9):707-712.
2. Han M, Burnett AL, Fishman EK, Marshall FF. The natural history and treatment of adrenal myelolipoma. *J Urol.* 1997;157(4):1213-1216.
3. Lamas C, López LM, Lozano E, et al. Myelolipomatous adrenal masses causing Cushing's syndrome. *Exp Clin Endocrinol Diabetes.* 2009;117(8):440-445.
4. Meaglia JP, Schmidt JD. Natural history of an adrenal myelolipoma. *J Urol.* 1992;147(4):1089-1090.
5. Yip L, Tublin ME, Falcone JA, et al. The adrenal mass: correlation of histopathology with imaging. *Ann Surg Oncol.* 2010;17(3):846-852.
6. Young WF. The incidentally discovered adrenal mass. *N Engl J Med.* 2007;356(6):601-610.

©2011 American Medical Association. All rights reserved.
Downloaded From: http://archsurg.jamanetwork.com/ on 01/17/2017