

Residual Splenic Function After Laparoscopic Splenectomy

A Clinical Concern

Eduard M. Targarona, MD, PhD; Joan Josep Espert, MD; Carme Balagué, MD; Gemma Sugrañes, MD; Carme Ayuso, MD, PhD; Francesc Lomeña, MD, PhD; Francesc Bosch, MD, PhD; Manuel Trias, MD, PhD

Objective: To document the existence of residual splenic function after laparoscopic splenectomy in a series of 48 patients.

Design: A noncomparative descriptive case series.

Setting: A tertiary care center.

Patients: A series of 9 patients without clinical improvement after laparoscopic splenectomy of 48 consecutive patients undergoing laparoscopic splenectomy for several hematologic disorders after a mean follow-up of 16 months (range, 1-40 months).

Interventions: A computed tomographic scan and technetium Tc 99m sodium pertechnetate heat-damaged red blood cell scintigraphy were performed for patients with partial (platelet count $<100 \times 10^9/L$) or total (platelet count $<50 \times 10^9/L$) failure of improvement.

Main Outcome Measure: Evidence of residual splenic

tissue by image diagnosis.

Results: The condition of 9 of the 48 patients failed to improve after laparoscopic splenectomy. Six patients experienced a total failure of improvement and 3 experienced a partial failure of improvement (1 patient had human immunodeficiency virus–related thrombocytopenia and 8 had idiopathic thrombocytopenic purpura). Three patients had residual splenic function, which was revealed by scintigraphy. The results of a computed tomographic scan showed an accessory spleen in one patient and splenic implants in splenic fossa in another patient.

Conclusion: Laparoscopic splenectomy has a promising role in the management of hematologic diseases requiring splenectomy, but it requires exquisite care to avoid parenchymal rupture and cell spillage and to avoid leaving accessory spleens, which can lead to the failure of surgical treatment.

Arch Surg. 1998;133:56-60

From the Services of General and Digestive Surgery (Drs Targarona, Espert, Balagué, Sugrañes, and Trias), Radiology (Dr Ayuso), and Hematology (Dr Bosch), and the Laboratory of Nuclear Medicine (Dr Lomeña), Hospital Clinic, University of Barcelona, Barcelona, Spain.

LAPAROSCOPIC splenectomy (LS) has become a useful alternative to open splenectomy, offering the advantages (less pain and fewer scars) of laparoscopic surgery.^{1,2} However, there is no wide experience with this technically demanding operation; as with other laparoscopic procedures, new clinical situations appear after the application of laparoscopic techniques. Clinical success after splenectomy is related to the complete removal of splenic tissue. However, there are some theoretical risks during laparoscopy of inducing splenic tissue spillage or of leaving unidentified accessory spleens (ASs). It is well known that splenic tissue can implant and grow into the peritoneal cavity.³⁻⁵ However, manipulation and

retrieval of solid organs during laparoscopy can be difficult; also, the intra-abdominal bag can break during spleen morcellation, with a risk of splenic tissue spillage.⁶ Accessory spleens are present in more than 15% of the population; if they are left or not identified, they can induce relapsing disease.⁷⁻¹² Some previous reports have suggested a more difficult identification of ASs during LS.^{13,14} This article documents residual splenic function in 3 patients of a series of 48 patients in whom LS was performed.

RESULTS

Between February 1992 and October 1996, 48 LSs were performed. The demographic and operative variables can be

PATIENTS AND METHODS

Between February 1992 and October 1996, 48 consecutive patients with a wide range of hematologic diseases requiring splenectomy underwent a laparoscopic approach; the clinical data and technical details were prospectively recorded. Laparoscopic splenectomy was performed via an anterior approach in 13 patients and via a lateral approach in the remaining 35 patients. Both techniques have been previously described elsewhere.^{15,16} In all cases, ASs were sought routinely after opening the omental pouch. The spleen was retrieved in a bag or, in selected cases, through an accessory incision to obtain an intact organ or because of the size of the spleen. Early and late responses to splenectomy were assessed with clinical and analytic examinations. The conditions of patients in whom there was a late failure to improve after LS were reevaluated with technetium Tc 99m sodium pertechnetate heat-damaged red blood cell scintigraphy (LFOV 609 γ camera, high-resolution collimator, Elscint, Haifa, Israel) and computed tomographic (CT) scanning.

Early failure is defined as the inability to normalize the platelet count during the first week after LS. Late failure is defined as the decline of the platelet count below $100 \times 10^9/L$ (partial failure) or below $50 \times 10^9/L$ (complete failure) after a transient increase ($>200 \times 10^9/L$).

summarized as follows (all data are given as the number of patients unless otherwise specified):

Variable	No. of Patients
Total	48
Age, y*	36 \pm 15
Sex	18 M and 30 F
Hematologic diagnosis	
Thrombocytopenia	32†
Spherocytosis	7
Hemolytic autoimmune anemia	4
Other‡	7
Operative time, min*	177 \pm 64
Operative position	13 Anterior and 35 Lateral
Conversion, %	6
Accessory incision	7
Platelet count, $\times 10^9/L$ *	
Preoperative	76 \pm 78
Immediate postoperative	239 \pm 162
Long-term postoperative	214 \pm 114

*Data are given as the mean (\pm SD).

†Twenty-seven patients had idiopathic thrombocytopenic purpura, and 5 had human immunodeficiency virus-related thrombocytopenia.

‡Other indicates unknown origin splenomegaly, splenic tumor, myelofibrosis, chronic lymphatic leukemia, and refractory anemia.

The platelet count of the 32 patients in whom an LS was performed for the treatment of autoimmune thrombocytopenia ranged between $5 \times 10^9/L$ and $102 \times 10^9/L$.

Laparoscopic splenectomy was accomplished in 45 (94%) of the 48 patients. Conversion was required in 2

patients because of the difficulty in handling the spleen and because of diffuse oozing (in one patient with idiopathic thrombocytopenic purpura and in one patient with human immunodeficiency virus-related thrombocytopenia); conversion was required in a third patient with massive splenomegaly (>3500 g) because of the difficulties in controlling the splenic vein. Accessory spleens were found in 6 (12.5%) of the 48 patients. Five of them were easily located close to the inferior pole of the spleen or next to the great curvature; however, one, corresponding to one of the converted cases (massive splenomegaly for spherocytosis), was found in the mesocolon, only felt by palpation, and completely hidden from view.

The spleen was extracted through a bag in 38 patients, and a laparotomy was performed in 7 patients. Accidental perforation of the bag occurred in 4 cases, but all the spleen pieces were recovered.

The platelet count normalized within 48 hours of the operation in 29 of the 32 patients with a low platelet count.

After a mean follow-up of 18 months, the hematologic status of 39 (81%) of the 48 patients improved; however, 9 patients had a low platelet count (1 patient with human immunodeficiency virus-related thrombocytopenia and 8 patients with idiopathic thrombocytopenic purpura). There were 6 total failures and 3 partial failures. All 9 patients were assessed with scintigraphy and CT scanning. Scintigraphy showed residual splenic function in 3 patients with idiopathic thrombocytopenic purpura (**Figure 1** through **Figure 3** and **Table 1**). Two corresponded to a hot-spotted image that the CT scan confirmed as an AS. In one of these patients, another AS had been retrieved during a former LS. The residual spleen was located in a pararenal area. Scintigraphy showed multiple images in the splenic fossa in a third patient; a CT scan confirmed these images as implants. This patient was one of the patients converted to open surgery because of the difficulty in handling the spleen during LS. A previous rupture of the bag did not occur during spleen retrieval in any of these patients. The platelet counts in 2 of these patients were between $70 \times 10^9/L$ and $100 \times 10^9/L$ without associated treatment; an observation policy was established for these patients. The third patient refused further explorations or surgery.

COMMENT

Advances in laparoscopic surgical techniques have favored a laparoscopic approach for splenectomy.¹³⁻²⁶ However, surgical laparoscopy entails different features from open surgery. After the wide application of laparoscopy in other intra-abdominal surgical diseases, which include the treatment of known (colon) or unsuspected (gallbladder) tumors, a higher incidence of early recurrence has been observed at the site ports or at the site of abdominal dissemination.²⁷ Some recent experimental studies suggest that the pneumoperitoneum is able to disseminate free abdominal malignant cells.^{28,29} It is well known from experimental and clinical studies that spleen tissue possesses a great facility to

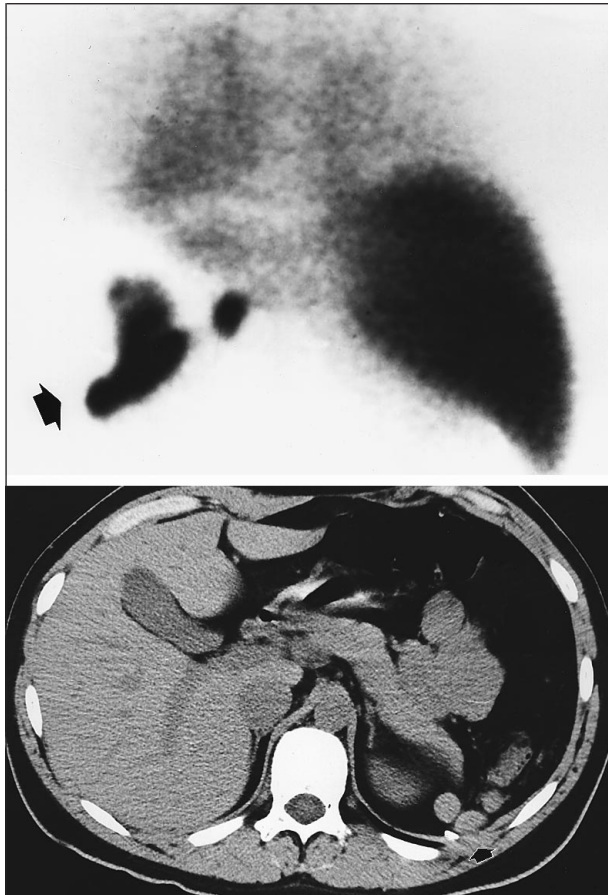


Figure 1. Case 2. A 16-year-old boy with idiopathic thrombocytopenic purpura converted to open surgery because of difficulty in handling the spleen. The spleen weighed 175 g, and the operative time was 240 minutes. The platelet count after 37 months of follow-up was $100 \times 10^9/L$. Top, Scintigraphy shows technetium Tc 99m sodium pertechnetate heat-damaged red blood cell uptake in several areas (arrow) of splenic fossa. Bottom, A computed tomographic scan showing multiple images compatible with residual splenic tissue.

implant, even when it is removed after trauma.³⁻⁵ Laparoscopic splenectomy is a technically demanding procedure associated with a notably longer operative time than open splenectomy. The spleen parenchyma is frail; during LS, the spleen is mobilized and tears or parenchymal bleeding can occur. There may be a theoretical high risk of splenosis. One of the patients (patient 2) described in this series had several implants in the splenic fossa. These implants may have been secondary to rupture of the spleen capsula, although the patient was converted to open surgery and major breaches were not observed. Another situation in which spleen tissue can be spilled is during morcellation and retrieval if the bag is broken; however, none of the 4 patients in whom the bag was broken had residual splenic tissue.

Accessory spleens are frequently observed (10%-30%), and the incidence in open series is higher than that reported in laparoscopic series (**Table 2**).⁷ Accessory spleens can be located in many sites (splenic hilum to scrotum) and are sometimes surrounded by fatty tissue that impairs their visualization. When left in situ, they can prevent the resolution of hematologic disease, mainly in patients with autoimmune thrombocytope-

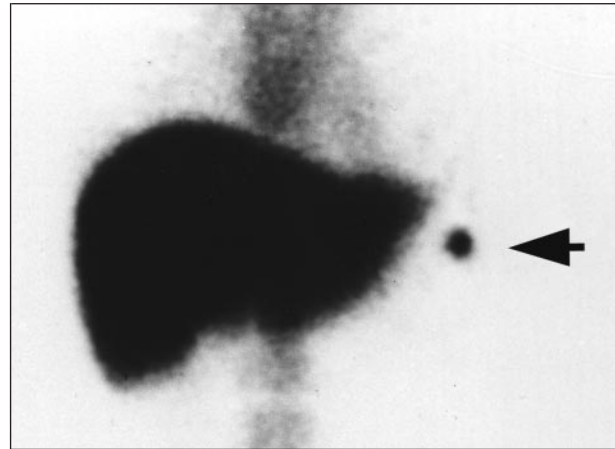


Figure 2. Case 6. A 19-year-old girl with idiopathic thrombocytopenic purpura. The laparoscopic splenectomy was uneventful. The spleen weighed 80 g, and the operative time was 240 minutes. The platelet count after 33 months of follow-up was $22 \times 10^9/L$. Scintigraphy shows an image of isotope pickup in the splenic fossa (arrow), close to the left hepatic lobe.

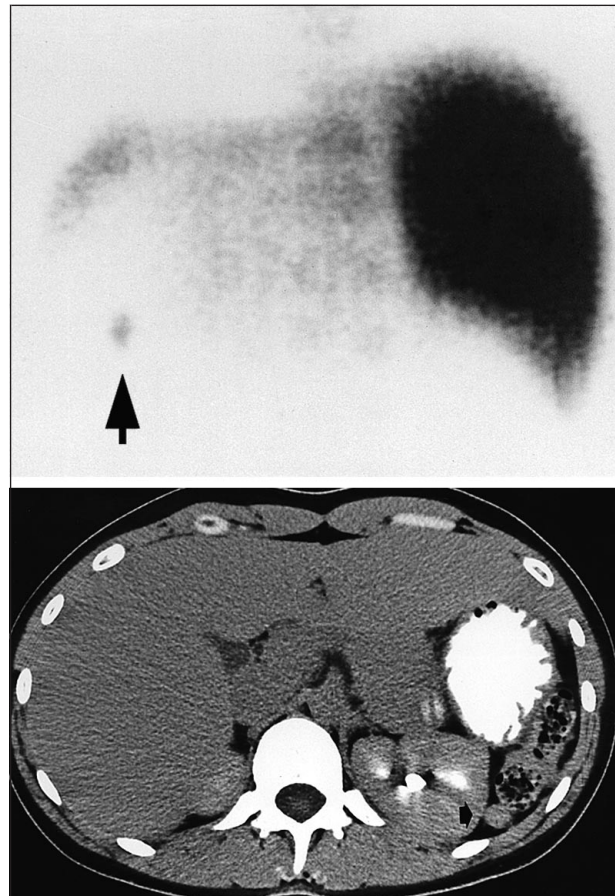


Figure 3. Case 13. A 28-year-old woman with idiopathic thrombocytopenic purpura. The laparoscopic splenectomy was uneventful. The spleen weighed 165 g, and the operative time was 240 minutes. The platelet count after 22 months of follow-up was $40 \times 10^9/L$. Top, Scintigraphy shows an image of isotope pickup (arrow) in the splenic fossa. Bottom, A computed tomographic scan shows an accessory spleen not excised during laparoscopy.

nia.⁹⁻¹² Gigot et al¹³ described the increased difficulty in locating such accessory organs after the impossibility of finding an AS previously demonstrated by CT scanning. The experience in our series shows that ASs were not iden-

Table 1. Demographic and Operative Features of Patients With Residual Splenic Function After Laparoscopic Splenectomy*

Age, y/Sex	Type of Approach	Conversion	Platelet Count, $\times 10^9/L$		
			Preoperative	Postoperative	Long-term
16/M	Anterior	Yes	7	<50	100
19/F	Anterior	No	100	179	22
28/F	Lateral	No	29	100	40

*The diagnosis for all patients was idiopathic thrombocytopenic purpura.

Table 2. Incidence of Accessory Spleens in Series With More Than 16 Laparoscopic Splenectomies

Source, y	No. of Laparoscopic Splenectomies	Conversion, %	Accessory Spleens, %*
Phillips et al, ¹⁸ 1994	16	19	...
Cadiere et al, ¹⁷ 1994	17	12	12.0
Yee et al, ²³ 1995	25	16	4.0
Emmerman et al, ²² 1995	27	19	...
Gigot et al, ¹⁹ 1995†	50	10	14.0
Delaitre et al, ¹⁹ 1995	19	16	10.0
Rhodes et al, ²⁰ 1995	24	8	...
Poulin et al, ²¹ 1995	23	9	30.0
Miles et al, ²⁴ 1996	25	8	0.0
Flowers et al, ¹⁴ 1996	43	19	9.0
Terrosu et al, ²⁵ 1996	17	6	...
Bové et al, ²⁶ 1996	18	11	0.0
Present study, 1996	48	6	12.5

*Ellipses indicate data not available.

†Multicenter series.

tified in 3 cases, although they were looked for. In one case, another AS had been removed previously during LS; in another case, the AS was found during conversion, totally surrounded by fatty tissue. It is difficult to say if ASs are more difficult to visualize by laparoscopy or open surgery, because comparative studies are lacking.

The laparoscopic technique for splenectomy should include, as an important step, the search for ASs. Because of the variable situations, an exploratory laparoscopy should be performed as an initial step. The splenic flexure of the colon and the omentum should be palpated to exclude the existence of ASs at this level. The next step is to explore the large curvature of the stomach. Then, the omental pouch should be opened and the medial face of the spleen and splenic hilum should be inspected. The technique that LS proposes with the initial mobilization of the posterior face of the spleen, which is then excised with several applications of the endostapler without opening the omental pouch, has the drawback that it does not permit the existence of ASs to be identified.²³ The use of perioperative laparoscopic ultrasonography has been proposed, but its real value is unknown. Another point from the practical point of view could be preoperative identification by a CT scan.

The excision of residual ASs is followed by a clinical response of 20% to 60%; laparoscopic identification and removal has been reported.³⁰ In our patients, be-

cause of the small size of the residual splenic tissue and the clinical improvement of 2 patients (platelet counts ranging between $70 \times 10^9/L$ and $100 \times 10^9/L$), an observation policy was followed. A third patient refused further surgery.

Laparoscopic splenectomy has a promising role in the management of hematologic diseases requiring splenectomy, but it requires exquisite care to avoid parenchymal rupture and cell spillage and to avoid leaving ASs, which can induce the failure of surgical treatment.

This study was supported by grant 97/760 from the Fondo de Investigaciones Sanitarias, Madrid, Spain.

Reprints: Manuel Trias, MD, Service of General and Digestive Surgery, Hospital de la Santa Creu i Sant Pau, Avda Pare Claret 167, 08025 Barcelona, Spain.

REFERENCES

- Trias M, Targarona EM, Benarroch G, Fernández-Cruz L. Laparoscopic surgery for treatment of splenic disorders: an update. *Eur J Gastroenterol Hepatol.* 1997; 9:750-755.
- Grossbard ML. Is laparoscopic splenectomy appropriate for the management of hematologic and oncologic diseases. *Surg Endosc.* 1996;10:387-388.
- Pisters PW, Pachter HL. Autologous splenic transplantation for splenic trauma. *Ann Surg.* 1994;219:225-235.
- Traub A, Gierink S, Smith C, et al. Splenic reticuloendothelial function after splenectomy, spleen repair, and spleen autotransplantation. *N Engl J Med.* 1987; 317:1559-1564.
- Moore FA, Moore EE, Moore GE, Erdoes L. Fivefold enlargement of implants in a splenic autotransplant recipient. *Surgery.* 1993;113:462-465.
- Legrand MJ, Honore P, Joris J, Jacquet N. Techniques of laparoscopic morcellation of the spleen. *Minim Invasive Ther.* 1996;5:143-146.
- Rudowski WJ. Accessory spleens: clinical significance with particular reference to the recurrence of idiopathic thrombocytopenic purpura. *World J Surg.* 1985; 9:422-430.
- George JN, Woolf SH, Raskob GE, et al. Idiopathic thrombocytopenic purpura: a practical guideline developed by explicit methods for the American Society of Hematology. *Blood.* 1996;88:3-40.
- Wallace D, Fromm D, Thomas D. Accessory splenectomy for ITP. *Surgery.* 1982; 91:134.
- Ambriz R, Muñoz R, Quintanar E, Sigler L, Aviles A, Pizzuto J. Accessory spleen compromising response to splenectomy for ITP. *Radiology.* 1985;155:793.
- Facon T, Caulier MT, Fenaux P, et al. Accessory spleen in recurrent chronic ITP. *Am J Hematol.* 1992;41:184.
- Verheyen CN, Beart RW, Clifton MD, Phykyl RL. Accessory splenectomy in the management of immune thrombocytopenic purpura. *Mayo Clin Proc.* 1978;53: 442.
- Gigot JF, Legrand M, Cadiere GB, et al. Is laparoscopic splenectomy a justified approach in hematologic disorders? preliminary results of a prospective multicenter study. *Int Surg.* 1995;80:299-303.
- Flowers JL, Lefor AT, Steers J, Heyman M, Graham SM, Imbembo AL. Laparoscopic splenectomy in patients with hematologic diseases. *Ann Surg.* 1996;224: 19-28.
- Trias M, Targarona EM, Moral A, Prados M. Laparoscopic splenectomy: technical aspects and preliminary results. *Endosc Surg Allied Technol.* 1994;2:288-292.

16. Trias M, Targarona EM, Balague C. Laparoscopic splenectomy: an evolving technique: a comparison between anterior or lateral approach. *Surg Endosc*. 1996; 10:389-392.
17. Cadiere GB, Verroken R, Himpens J, Bruyns J, Efra M, DeWitt S. Operative strategy in laparoscopic splenectomy. *J Am Coll Surg*. 1994;179:668-672.
18. Phillips E, Carroll BJ, Fallas MJ. Laparoscopic splenectomy. *Surg Endosc*. 1994; 8:931-933.
19. Delaitre B, Bonnichon PH, Barthes TH, Dousset B. Splenectomie coelioscopique: technique de suspension splénique: a propos de 19 cas. *Ann Chir*. 1995;49:471-476.
20. Rhodes M, Rudd M, O'Rourke N, Nathanson L, Fielding G. Laparoscopy splenectomy and lymph node biopsy for hematologic disorders. *Ann Surg*. 1995;22: 43-46.
21. Poulin E, Thibault C, Mamazza J. Laparoscopic splenectomy. *Surg Endosc*. 1995; 9:172-177.
22. Emmerman A, Zornig C, Peiper M, Weh HJ, Broelsch CE. Laparoscopic splenectomy: technique and results in a series of 27 cases. *Surg Endosc*. 1995;9:924-927.
23. Yee LF, Carvajal SH, Lorimier AL, Mulvihill SJ. Laparoscopic splenectomy: the initial experience at UCSF. *Arch Surg*. 1995;130:874-879.
24. Miles WFA, Greig JD, Wilson RG, Nixon SJ. Technique of laparoscopic splenectomy with a powered vascular linear stapler. *Br J Surg*. 1996;83:1212-1214.
25. Terrosu G, Donini A, Silvestri F, et al. Laparoscopic splenectomy in the management of hematological disease: surgical technique and outcome in 17 patients. *Surg Endosc*. 1996;10:441-444.
26. Bové T, Delvaux G, Eijkelenburg P, Backer A, Willems G. Laparoscopic-assisted surgery of the spleen: clinical experience in expanding indications. *J Laparoendosc Surg*. 1996;6:213-217.
27. Martinez J, Targarona EM, Balagué C, Pera MI, Trias M. Port-site metastasis: an unresolved problem in laparoscopic surgery. *Int Surg*. 1995;80:315-321.
28. Jones DB, Guo LW, Reinhard MK, et al. Impact of pneumoperitoneum on trocar site implantation of colon cancer in hamster model. *Dis Colon Rectum*. 1995; 38:1182-1188.
29. Mathew G, Watson DI, Rofe AM, Baigrie CF, Ellis T, Jamieson GG. Wound metastasis following laparoscopic and open surgery for abdominal cancer in a rat model. *Br J Surg*. 1996;83:1087-1090.
30. Mercan S, Seven R, Bozboru A. Laparoscopic treatment of accessory spleen left after open surgery for ITP. *Surg Endosc*. 1994;8:450.

IN OTHER AMA JOURNALS

JAMA

The Logistic Organ Dysfunction System: A New Way to Assess Organ Dysfunction in the Intensive Care Unit
Jean-Roger Le Gall, MD; Janelle Klar, MS; Stanley Lemeshow, PhD; Fabienne Saulnier, MD; Corinne Alberti, MD; Antonio Artigas, MD; Daniel Teres, MD; for the ICU Scoring Group

Objective.—To develop an objective method for assessing organ dysfunction among intensive care unit (ICU) patients on the first day of the ICU stay.

Design and Setting.—Physiological variables defined dysfunction in 6 organ systems. Logistic regression techniques were used to determine severity levels and relative weights for the Logistic Organ Dysfunction (LOD) score and for conversion of the LOD score to a probability of mortality.

Patients.—A total of 13 152 consecutive admissions to 137 adult medical/surgical ICUs in 12 countries from the European/North American Study of Severity Systems.

Outcome Measure.—Patient vital status at hospital discharge.

Results.—The LOD System identified from 1 to 3 levels of organ dysfunction for 6 organ systems: neurologic, cardiovascular, renal, pulmonary, hematologic, and hepatic. From 1 to 5 LOD points were assigned to the levels of severity, and the resulting LOD scores ranged from 0 to 22 points. Model calibration was very good in the developmental and validation samples ($P=.21$ and $P=.50$, respectively), as was model discrimination (area under the receiver operating characteristic curves of 0.843 and 0.850, respectively).

Conclusion.—The LOD System provides an objective tool for assessing severity levels for organ dysfunction in the ICU, a critical component in the conduct of clinical trials. Neurologic, cardiovascular, and renal dysfunction were the most severe organ dysfunctions, followed by pulmonary and hematologic dysfunction, with hepatic dysfunction the least severe. The LOD System takes into account both the relative severity among organ systems and the degree of severity within an organ system. *JAMA*. 1996;276:802-810

Reprints: Jean-Roger Le Gall, MD, Service de Réanimation Médicale, Hôpital Saint-Louis, 1 avenue Claude Vellefaux, 75475 Paris Cedex 10, France.