

Helical Computed Tomography in the Diagnosis of Portal Vein Invasion by Pancreatic Head Carcinoma

Usefulness for Selecting Surgical Procedures and Predicting the Outcome

Hiroyoshi Furukawa, MD; Tomoo Kosuge, MD; Kiyoshi Mukai, MD; Ryoko Iwata, MD; Yae Kanai, MD; Kazuaki Shimada, MD; Junji Yamamoto, MD; Kyosuke Ushio, MD

Objective: To evaluate the use of helical computed tomography (CT) in diagnosing portal vein (PV) invasion by pancreatic head carcinoma and its usefulness in predicting outcome.

Design: Validation cohort study.

Setting: Tertiary care public hospital.

Patients: Twenty-seven patients with carcinoma involving the pancreatic head were preoperatively studied with helical CT. All patients underwent resection.

Main Outcome Measure: By quantifying the contact between the tumor and PV on helical CT, the relationship between them was classified into 1 of 4 types: type 1, visible fat layer between PV and the tumor; type 2, with the total PV circumference defined as 360°, contact between the tumor and PV was considered to be 90° or less; type 3, contact ranged between 91° and 180°; and type 4, contact greater than 180°. Helical CT results were compared with

intraoperative observation, histological findings of the resected specimen, and postoperative course.

Results: When helical CT showed type 3 or 4, the case was diagnosed as positive for PV invasion. Sensitivity, specificity, and overall accuracy were 83%, 100%, and 89% when compared with the intraoperative assessment, and 92%, 79%, and 85% with the histological assessment, respectively. One- and 2-year survival rates were 86% and 69% for type 1, 100% and 75% for type 2, and 33% and 12% for type 3, respectively. The survival rates of patients with types 1 and 2 were significantly higher than that of those with type 3 ($P < .05$). All 3 patients with type 4 died within 9 months.

Conclusions: Helical CT facilitates detection of PV invasion by pancreatic head carcinoma. The extent of PV involvement reflected the outcome after pancreatectomy.

Arch Surg. 1998;133:61-65

THE PROGNOSIS of pancreatic carcinoma remains poor.^{1,2} Although surgical resection is the only curative treatment for this cancer, most patients present at an advanced stage. Even if distant metastases are not detected at the time of surgical exploration, we frequently observe that the pancreatic tumor extends into the retroperitoneal spaces and involves the superior mesenteric vein (SMV) or portal vein (PV). This venous invasion often prevents successful curative treatment. Thus, it is important to determine the existence and degree of tumor invasion of the PV/SMV before surgery.

Computed tomography (CT) and visceral angiography are common imaging modalities used for the diagnosis and staging of pancreatic carcinoma.³⁻⁶ Despite the use of these imaging modalities, subtle PV invasion by the tumor is

sometimes difficult to assess. Endoscopic ultrasonography and endovascular ultrasonography have also been applied to the diagnosis and staging of pancreatic cancer.^{7,8} These are excellent diagnostic methods, especially for diagnosing PV/SMV invasion by the pancreatic tumor. However, they require considerable operator skill and the scanning area is very limited for the evaluation of other factors such as distant lymph node or liver metastasis. Moreover, all these examinations are performed under anesthesia and endovascular ultrasonography is usually performed during surgery.

Helical (spiral) CT, a newly developed imaging technique, has made it possible to obtain volumetric acquisitions during a single breath-holding period with minimal invasiveness. This technique has the ability to allow scanning during the phase of maximal vascular enhancement and to acquire mul-

From the Departments of Diagnostic Radiology (Drs Furukawa, Iwata, and Ushio) and Surgery (Drs Shimada, Kosuge, and Yamamoto), National Cancer Center Hospital, Tokyo; Pathology Divisions, National Cancer Center Research Institute East, Kashiwa (Dr Mukai) and National Cancer Center Research Institute, Tokyo, Japan (Dr Kanai).

PATIENTS AND METHODS

PATIENTS

This study included 27 consecutive patients with histopathologically proven ductal adenocarcinoma of the pancreatic head. These patients were preoperatively examined by CT and subsequently underwent pancreatic resection between June 1993 and August 1995 at the National Cancer Center Hospital, Tokyo, Japan. Patients with carcinoma of the pancreatic body or tail, bile duct carcinoma, cystadenocarcinomas, intraductal papillary tumors, ampullary carcinomas, and endocrine tumors were excluded from this study. There were 16 women and 11 men, with a mean age of 62.8 years (range, 47-82 years).

The tumor was located in the head of the pancreas in 25 patients and in the whole pancreas in 2 patients. No distant metastasis was discovered in any patient during surgery. The mean size of the resected specimen was 4.2 cm (range, 1.5-9.5 cm). All helical CT scans were obtained within 30 days prior to surgery.

SURGERY

Among the 27 patients, 20 (74%) underwent a standard Whipple procedure removing the gastric antrum, duodenum, proximal jejunum, gallbladder, distal common bile duct, and head of the pancreas; 4 (15%) underwent total pancreatectomy; 2 (7.4%) underwent pylorus-preserving pancreatoduodenectomy; and 1 (3.7%) underwent an Appleby procedure (distal pancreatectomy combined with celiac trunk). Twenty-four patients received intraoperative radiotherapy and 20 had wide retroperitoneal dissection.

HELICAL CT

Helical CT scan was obtained with a 900S or X-Vigor scanner (Toshiba Medical Systems, Tokyo, Japan). Helical CT was performed in all 27 patients with 5-mm collimation and 5 mm/s table movement (scan time per section, 1 second; scan collimation, 5 mm; scan pitch, 1) with mechanical injection of 150 mL of iopamidol (300 mg/mL of

iodine) into the antecubital vein at a rate of 2 to 3 mL/s. Scanning began 40 to 60 seconds after the start of injection of the contrast medium. Transaxial images from the helical CT scan were reconstructed with 2- to 5-mm overlapping intervals.

LESION ANALYSIS

Helical CT examinations of all 27 patients were reviewed by 2 expert radiologists (H.F. and R.I.). Invasion of the PV/SMV by tumor on CT was evaluated according to the method proposed by Picus et al,¹⁴ who evaluated invasion of the aorta by esophageal cancer. Initially, the presence or absence of a visible layer of fat between the PV or SMV and adjacent tumor was noted. In those patients lacking a visible fat plane, the extent of direct contact between PV and tumor was quantitated (**Figure 1**). With the total PV circumference being 360°, the amount of contact between the tumor and PV was graded as 90° or less, between 91° and 180°, or greater than 180° (in which case the PV was almost obstructed and collateral vessels had usually developed). Thus, the relationship between the tumor and the PV/SMV was classified into 1 of the following 4 types: type 1, fat layer visible; type 2, direct contact of 90° or less; type 3, contact ranging between 91° and 180°; and type 4, contact greater than 180° (**Figure 2**).

HISTOPATHOLOGICAL EXAMINATION

The surgically resected specimens were examined according to the general rules for the Study of Pancreatic Cancer by the Japanese Pancreas Society.¹⁵ Resected specimens were immediately fixed in 10% buffered formalin, cut serially to 4-mm-thick sections, and processed routinely and embedded in paraffin. Paraffin sections were stained with hematoxylin-eosin.

POSTOPERATIVE SURVIVAL

This study was completed on October 31, 1996; the duration of follow-up ranged from 14 to 40 months. Survival rates were calculated by the Kaplan-Meier method with postoperative deaths included. Survival rates for patients were compared by log-rank test.

multiple thin sections through the area of interest.^{9,10} These advantages are helpful for evaluating the relationship between the PV/SMV and pancreatic tumor.¹¹ Thus, we used helical CT for diagnosing tumor invasion of the PV/SMV.

Although various approaches for detecting pancreatic cancer have been attempted, only a few reports have included data concerning the prognostic significance of these preoperative diagnostic procedures.^{12,13} It is also important to use preoperative imaging procedures to predict the clinical course of patients with pancreatic cancer and establish the mode of therapy. Our study was performed to evaluate the accuracy of helical CT in identifying PV/SMV invasion by pancreatic cancer and predicting survival after pancreatectomy.

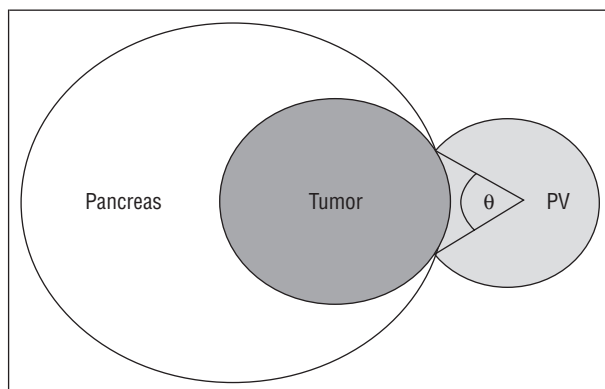


Figure 1. Schematic diagram showing the relationship between the tumor and portal vein (PV). With the total PV circumference as 360°, the amount of contact between the tumor and PV (θ) was graded.

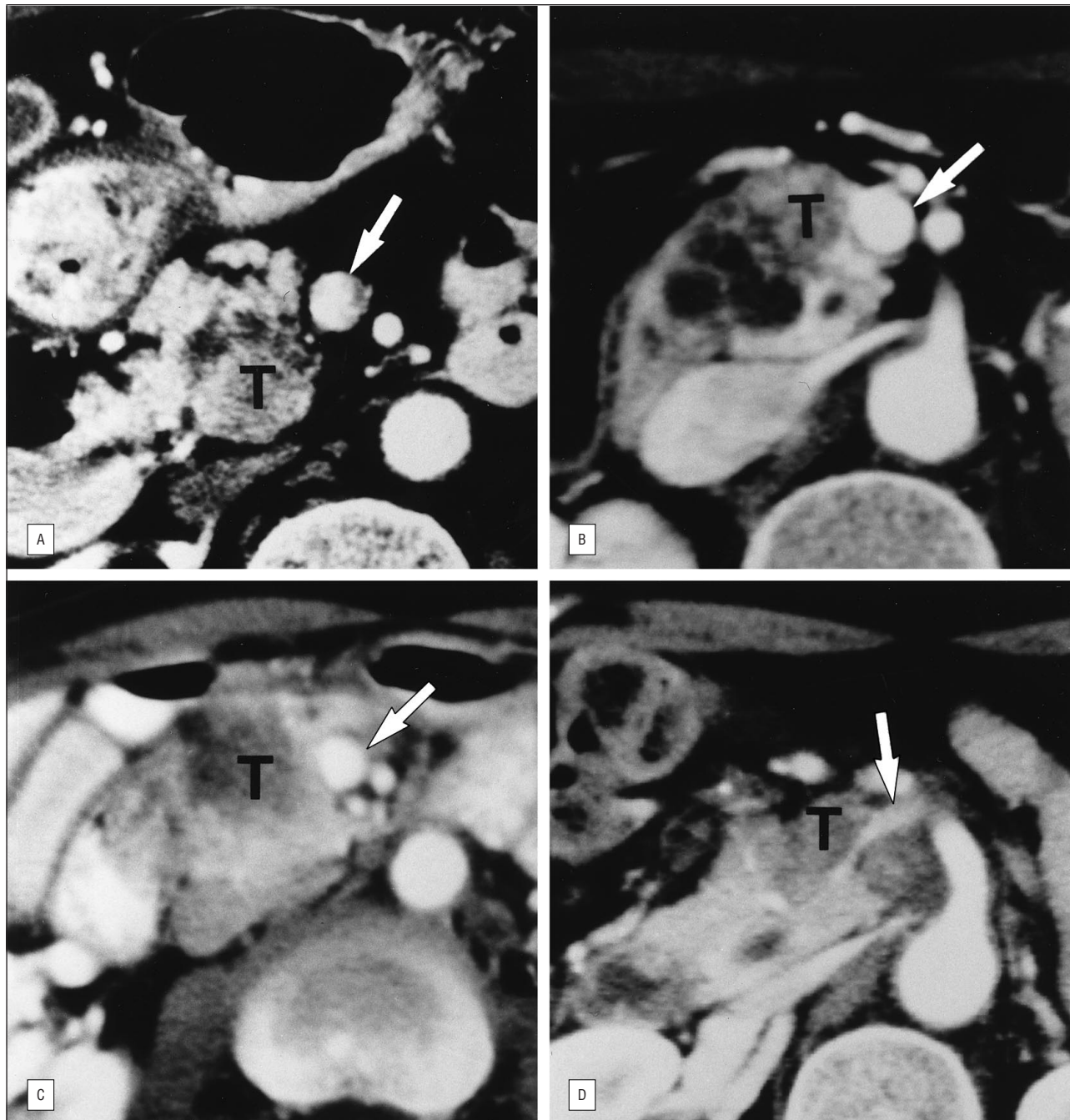


Figure 2. Helical computed tomography typing of portal vein (arrows) invasion. A, Type 1, presence of a fat plane between the portal vein and tumor (T). B, Type 2, contact between tumor and portal vein was evaluated as 90° or less. C, Type 3, contact ranged between 91° and 180° . D, Type 4, contact greater than 180° .

RESULTS

INTRAOPERATIVE AND HISTOLOGICAL EXAMINATION OF PV/SMV INVASION

Eighteen (67%) of 27 patients underwent combined resection of PV/SMV in which surgeons intraoperatively determined that the tumor invaded the PV/SMV. Tumor infiltration of the resected PV/SMV could be documented histopathologically in 13 (72%) of the 18 patients. The depth of tumor invasion was to the venous adventitia in 1 (7.7%) of these 13 patients, to the venous medial layer in 6 (46%), and to the intimal layer in 5 (39%). The remaining patient

underwent tumor resection without PV/SMV resection but with a microscopically tumor-positive margin around the area dissected from the PV.

RELATIONSHIP OF THE CONTACT BETWEEN THE PV/SMV AND TUMOR EXTENT

A fat plane was visible between PV/SMV and the tumor (type 1) in 7 patients (**Table 1**). In 1 (14%) of these 7, the tumor was adherent to the PV/SMV at surgery and combined vascular resection was performed. In the other 19 patients, helical CT showed direct contact between the tumor and adjacent PV/SMV wall. Five of the 19 had an area

Table 1. Relationship of the CT-Determined Contact Between the PV and the Tumor to PV Invasion in 27 Patients*

PV Circumference in Contact With the Tumor	No. of Patients	No. (%) of Patients	
		With Intraoperative PV Invasion	With Histological PV Invasion
None	7	1 (14)	0
≤90°	5	2 (40)	1 (20)
91°-180°	12	12 (100)	9 (75)
>180°	3	3 (100)	3 (100)
Total	27	18 (67)	13 (48)

*CT indicates computed tomography; PV, portal vein.

Table 2. Results of Helical CT Diagnosis of PV Invasion According to Intraoperative and Histological Assessments*

Type of Case	Intraoperative Assessment	Histological Assessment
True negative	9	11
True positive	15	12
False negative	3	1
False positive	0	3
Total	27	27

*CT indicates computed tomography; PV portal vein.

of contact measuring 90° or less (type 2). Two of these 5 had evidence of PV/SMV invasion at surgery. Contact greater than 90° between the PV/SMV and the tumor (types 3 and 4) correctly indicated direct invasion of the PV/SMV wall at surgery in all 15 patients.

None of the 7 type 1 cases had histologically proven PV/SMV invasion. In contrast, 1 (20%) of 5 type 2 cases, 9 (75%) of 12 type 3 cases, and all of the type 4 cases had PV/SMV invasion at histological examination.

DIAGNOSTIC ACCURACY OF HELICAL CT FOR PV/SMV INVASION

According to our data, when helical CT showed direct contact greater than 90° between the PV/SMV and the tumor (type 3 or 4), the case was diagnosed as positive for PV/SMV invasion by the tumor. The helical CT diagnoses of PV/SMV invasion were compared with intraoperative and histological assessments. The results are presented in **Table 2**. Sensitivity, specificity, positive predictive value, negative predictive value, and overall accuracy were: 83% (15 of 18 cases), 100% (9 of 9), 100% (15 of 15), 75% (9 of 12), and 89% (24 of 27) in comparison with the intraoperative assessment, and 92% (12 of 13), 79% (11 of 14), 80% (12 of 15), 92% (11 of 12), and 85% (23 of 27) when compared with the histological assessment, respectively.

POSTOPERATIVE SURVIVAL

One patient with type 4 invasion died within 30 days of undergoing surgery. **Figure 3** shows the cumulative survival rates, including the operative death, by helical CT assessment. One- and 2-year survival rates were 86% and

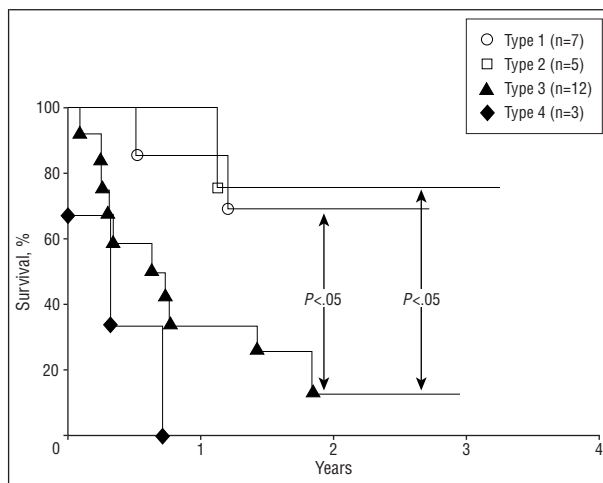


Figure 3. Cumulative survival rates according to tumor invasion type as determined by helical computed tomography. The survival rates associated with types 1 and 2 were significantly higher than that of type 3 ($P < .05$). All 3 patients with type 4 died within 9 months.

69% for type 1, 100% and 75% for type 2, and 33% and 12% for type 3, respectively. The survival rates associated with types 1 and 2 were significantly higher than those of type 3 ($P < .05$). All 3 patients with type 4 died within 9 months. Histopathologically, 3 (25%) of 12 patients with types 1 and 2 and 10 (67%) of 15 patients with types 3 and 4 had tumor involvement at a resection margin.

The survival was also examined in relation to tumor size (within 4 cm or more), lymph node metastasis, and carcinoma invasion into the common bile duct or duodenum; there was no significant correlation between the survival rate and any of these parameters.

COMMENT

Dynamic contrast-enhanced CT showed a high degree of accuracy in detecting and staging pancreatic carcinoma.³⁻⁵ The tumor is visualized as a mass on CT and the relationship between the tumor and neighboring vessels can easily be evaluated. Reports by Jafri et al⁴ and Freeny et al⁵ indicated that angiography did not contribute any additional or significant staging information compared with that contributed by CT. Warshaw et al⁶ reported that CT was as accurate as angiography for evaluating the vascular structures, although both procedures missed small liver metastases and peritoneal dissemination. Laparoscopy could detect these small distant metastases but not vascular invasion. We now perform angiography mainly to demonstrate the vascular anatomy prior to pancreatic resection.

Recently, Rösch et al⁷ reported a sensitivity of 36% for CT in assessing involvement of the portal branches and a specificity of 85%. Kaneko et al⁸ also obtained a sensitivity of 50% and a specificity of 79%. Their sensitivity and specificity values were lower than ours, which may be partially due to a difference in the CT techniques used. Gmeinwieser et al¹¹ used spiral CT and reported a sensitivity of 91% and a specificity of 94%. In many of these reports, the patient population included those with bile duct carcinomas or ampullary carcinomas that were usually

distant from the PV/SMV and results were calculated in comparison with intraoperative findings.

For accurate assessment of the diagnostic efficacy of helical CT, we restricted patients to those with ductal adenocarcinoma of the head or whole pancreas and excluded other periampullary tumors. Invasion of the PV/SMV was evaluated by both surgical and histological observations. As radical procedures involving PV/SMV resection are performed in our institute, histological assessment of the resected specimen was possible.

Discrepancies between surgical and histological assessment of PV/SMV invasion by the tumor have been described in previous reports,^{12,13,16-18} in which the degree of histological PV/SMV invasion was less than that discovered on surgical observation. Histologically, even when the tumor is in direct contact with the adventitia of the vessel but does not invade the vessel wall, it is diagnosed as negative (no invasion). However, in surgical practice, vessels in contact with the tumor should be concomitantly resected to preserve the surgical margin of the tumor. Thus, such close contact is regarded as positive on surgical observation. In this sense, surgical assessment is more important than histological observation in determining the extent of surgery, although assessment depends on the surgeon's skill and experience and the decision is often subjective.

In this study, by quantitating the area of visible contact between PV/SMV and the tumor on helical CT, PV/SMV invasion could be predicted with more than 85% accuracy when compared with either surgical or histological assessment. A fat plane normally separates the pancreas and the PV/SMV, but it may be absent because the patient has little perivascular fat or because the tumor has invaded the fat. We found that contact of more than 90° (types 3 and 4) strongly suggests invasion.

Aggressive radical surgery with PV/SMV resection for pancreatic carcinoma with PV/SMV invasion has been applied to an increased number of patients. Although the resectability rate has been increased by this aggressive approach, survival benefits for patients with invasion or near-invasion of the PV/SMV remain controversial.^{12,13,16-18} Ishikawa et al¹² and Nakao et al¹³ attempted to determine the clinical significance of PV invasion detected by angiographic findings. They classified angiographic findings into 4 or 5 types and compared the angiographic type with the actual invasion detected in the resected specimen and with survival rates. They noted poor survival after resection in patients with the finding of bilateral narrowing or marked stenosis with collateral veins of PV/SMV on angiography. Findings regarding the PV/SMV on helical CT also reflected survival after pancreatectomy, ie, postsurgical prognosis was poor in patients with type 3 or 4. Most of the tumors in type 4 were unresectable because of severe retroperitoneal infiltration or coexisting distant metastases. Consequently, only 3 patients with type 4 tumors were included in this study. Careful consideration is required in attempting radical resection in such cases because of the high risk and poor prognosis. However, if we had selected patients in whom helical CT showed type 1 or 2 invasion for aggressive surgery, approximately a 70% 2-year survival rate would be obtained. This result is better than those in many previous reports^{2,13,16-18} and almost equal to the selected series of Ishikawa et al,¹²

in which indication for aggressive surgery was defined as PV/SMV narrowing on angiography being absent, unilateral, or 1.2 cm or less in length. We consider patients with type 3 tumors to be incurable by aggressive surgery alone. Development of effective adjuvant or neoadjuvant therapy is necessary for these patients.

Helical CT provides valuable and accurate information regarding PV/SMV invasion by carcinoma of the pancreatic head and postoperative survival. Our CT classification is simple and does not require angiography. Using this CT classification, we believe that useless laparotomy or pancreatectomy may be avoided and necessary information for surgical planning provided for those patients with less extensive PV/SMV invasion.

This work was supported in part by a Grant-in-Aid for Cancer Research from the Ministry of Health and Welfare, Tokyo, Japan.

Reprints: Hiroyoshi Furukawa, MD, Department of Diagnostic Radiology, National Cancer Center Hospital, 5-1-1, Tsukiji, Chuo-ku, Tokyo 104, Japan.

REFERENCES

1. Warshaw AL, Castillo CF. Pancreatic carcinoma. *N Engl J Med.* 1992;326:455-465.
2. Nitecki SS, Sarr MG, Colby TV, van Heerden JA. Long-term survival after resection for ductal adenocarcinoma of the pancreas: is it really improving? *Ann Surg.* 1995;221:59-66.
3. Freeny PC, Marks WM, Ryan JA, Traverso LW. Pancreatic ductal adenocarcinoma: diagnosis and staging with dynamic CT. *Radiology.* 1988;166:125-133.
4. Jafri SZH, Aisen AM, Glazer GM, Weiss CA. Comparison of CT and angiography in assessing resectability of pancreatic carcinoma. *AJR Am J Roentgenol.* 1984;142:525-529.
5. Freeny PC, Traverso W, Ryan JA. Diagnosis and staging of pancreatic adenocarcinoma with dynamic computed tomography. *Am J Surg.* 1993;165:600-606.
6. Warshaw ALL, Gu ZY, Wittenberg J, Waltman AC. Preoperative staging and assessment of resectability of pancreatic cancer. *Arch Surg.* 1990;125:230-233.
7. Rösch T, Braig C, Gain T, et al. Staging of pancreatic and ampullary carcinoma by endoscopic ultrasonography. *Gastroenterology.* 1992;102:188-199.
8. Kaneko T, Nakao A, Inoue S, et al. Portal venous invasion by pancreaticobiliary carcinoma: diagnosis with intraportal endovascular US. *Radiology.* 1994;192:681-686.
9. Dupuy DE, Costello P, Ecker CP. Spiral CT of the pancreas. *Radiology.* 1992;183:815-818.
10. Fishman EF, Wyatt SH, Ney DR, Kuhlman JE, Siegelman SS. Spiral CT of the pancreas with multiplanar display. *AJR Am J Roentgenol.* 1992;159:1209-1215.
11. Gmeinwieser J, Feuerbach S, Hohenberger W, et al. Spiral CT in diagnosis of vascular involvement in pancreatic cancer. *Hepatogastroenterology.* 1995;42:418-422.
12. Ishikawa O, Ohigashi H, Imaoka S, et al. Preoperative indications for extended pancreatectomy for locally advanced pancreas cancer involving the portal vein. *Ann Surg.* 1992;215:231-236.
13. Nakao A, Harada A, Nonami T, et al. Clinical significance of portal invasion by pancreatic head carcinoma. *Surgery.* 1995;117:50-55.
14. Picus DP, Balfe DM, Koehler RE, Roper CL, Owen JW. Computed tomography in the staging of esophageal carcinoma. *Radiology.* 1983;146:433-438.
15. Japanese Pancreas Society. *General Rules for Surgical and Pathological Studies of Cancer of the Pancreas* [in Japanese]. 4th ed. Tokyo, Japan: Kanehara Publishing; 1993.
16. Allema JH, Reinders ME, Gulik TM, et al. Portal vein resection in patients undergoing pancreatoduodenectomy for carcinoma of the pancreatic head. *Br J Surg.* 1994;81:1642-1646.
17. Takahashi S, Ogata Y, Tsuzuki T. Combined resection of the pancreas and portal vein for pancreatic cancer. *Br J Surg.* 1994;81:1190-1193.
18. Roder JD, Stein HJ, Siewert R. Carcinoma of the periampullary region: who benefits from portal vein resection? *Am J Surg.* 1996;171:170-175.