

# Band Erosion in Patients Who Have Undergone Vertical Banded Gastroplasty

## Incidence and Technical Solutions

Pau Moreno, MD; Antoni Alastrué, MD; Miquel Rull, MD; Xavier Formiguera, MD; Darío Casas, MD; Jaume Boix, MD; Jaume Fernández-Llamazares, MD; Marc A. Broggi, MD

**Objectives:** To study the incidence of band erosion in patients who have undergone vertical banded gastroplasty and to describe the reparative techniques used.

**Design:** A retrospective review case series.

**Setting:** A university hospital-based tertiary referral center.

**Patients:** Two hundred fifty consecutive morbidly obese patients who underwent vertical banded gastroplasty between 1987 and 1995.

**Main Outcome Measures:** The development of band erosion into the stomach, reparative surgical techniques, and long-term weight loss control.

**Results:** Band erosion developed in 7 (2.8%) of the patients. Two patients had symptoms 1 month after under-

going forced endoscopy. Six patients required reoperation. The operative findings included 2 cases of "external" band erosion through the lesser curvature into the stomach and 4 cases of "internal" band erosion through the circular staple line. The surgical techniques used for repair depended on the radiological and endoscopic data and on the operative findings; the techniques included conversion into a gastric bypass, band replacement after the creation of a new stoma, and gastroplasty plus distal gastric bypass. There were no complications, and adequate long-term weight loss was achieved in all but 1 of the patients who underwent reoperation.

**Conclusion:** Band erosion may be corrected using appropriate surgical techniques to allow for adequate long-term weight loss in patients who have undergone vertical banded gastroplasty.

*Arch Surg.* 1998;133:189-193

**M**ORBID obesity, defined as a body mass index (BMI) (obtained by dividing the weight [given in kilograms] by the height [given in meters, squared]) exceeding 40, constitutes a major health risk. Bariatric surgery should be considered for severely obese patients when medical, dietary, or behavioral weight reduction therapies are unsuccessful or when serious comorbidity is present.<sup>1,2</sup> Vertical banded gastroplasty (VBG) is an effective and safe restrictive procedure for losing weight and changing dietary habits<sup>3-6</sup>; however, technical problems such as staple-line disruption or band erosion (BE) may have a negative effect on the course of these patients,<sup>7,8</sup> by causing either weight gain or excessive weight loss due to vomiting. The actual incidence of BE is unknown, and its surgical solution is often improvised during the reoperation. Furthermore, patients are generally removed from the bariatric

program and the weight reduction goal is not achieved.

This study investigates the incidence of BE in our series of patients who underwent VBG and describes the reparative techniques used, which may provide some useful suggestions for surgeons performing this operation.

## RESULTS

Of the 250 patients who underwent VBG, BE into the stomach developed in 7 (2.8%) of the patients (6 women and 1 man). All patients with this condition experienced excessive weight loss and symptoms of upper GI tract obstruction, which appeared between 4 and 14 months after the operation. Two patients had symptoms 1 month after undergoing forced endoscopy. The diagnosis of BE was established by means of barium studies (**Figure 1**) or endoscopy. Six of the 7 patients required reoperation, which was performed within 30 days of the diagnosis. One patient had

From the Departments of General Surgery (Drs Moreno, Alastrué, Rull, Fernández-Llamazares, and Broggi), Internal Medicine (Eating Disorders Unit) (Dr Formiguera), Radiology (Dr Casas), and Gastroenterology (Dr Boix), University Hospital "Germans Trias i Pujol," Barcelona, Spain.

## PATIENTS AND METHODS

A retrospective study of 250 consecutive patients who underwent VBG between 1987 and 1995 was performed. All patients were enrolled in a multidisciplinary bariatric surgical program at the University Hospital "Germans Trias i Pujol," Barcelona, Spain, and were operated on by the same surgical team (A.A. and M.R.). The initial eligibility criteria for the bariatric surgery program were as follows: (1) aged between 18 and 50 years; (2) overweight by 45 kg compared with the ideal body weight or a BMI greater than 40; (3) failure on a supervised diet; (4) reversible medical problems, such as sleep apnea syndrome, diabetes, and hypertension, with a BMI greater than 35; (5) team assessment; and (6) psychological factors, such as eating habits, the patient's motivation, and the patient's personality characteristics. These initial criteria only differed from our current policy (updated in 1992) in that the Salmon technique<sup>9</sup> (gastroplasty plus distal gastric bypass) was performed in superobese patients (BMI >50). The VBG was performed as described by Mason,<sup>4</sup> creating a 10- to 15-mL pouch but using a 5-cm band of expanded polytetrafluoroethylene (Goretex, WL Gore & Associates Inc, Flagstaff, Ariz) for the collar. The vertical staple line was reinforced with a running polypropylene suture.

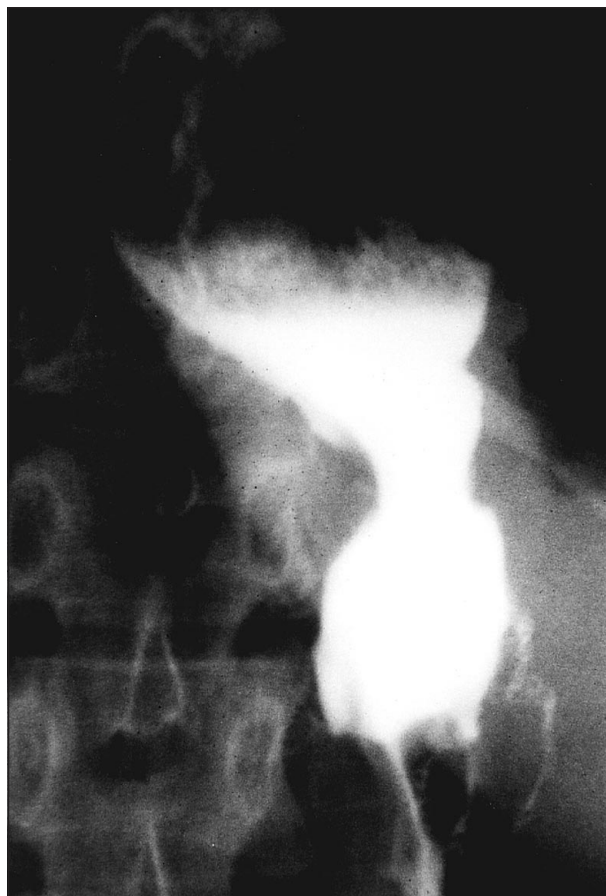The Reinhold method<sup>10</sup> was used to evaluate the actuarial and final weight results, and personal interviews with the patients were also scheduled. Barium studies were routinely performed at 6, 12, and 24 months after the operation and as needed for notable vomiting or insufficient weight loss. Patients with radiologically diagnosed BE underwent reoperation after endoscopic confirmation. Different reparative techniques were used depending on the operative findings. Antibiotic therapy with cefoxitin sodium was administered for 7 days in case of band replacement. An upper gastrointestinal (GI) tract roentgenographic series using hydrosoluble contrast material was performed on postoperative day 5 to assure the absence of leaks. Postoperative follow-up consisted of an interview 1 week after discharge from the hospital and an interview and an upper gastrointestinal tract roentgenogram at 3, 6, 12, and 24 months thereafter.

spontaneous improvement, and the results of a new endoscopic examination demonstrated the disappearance of the band; thus, this patient did not require reoperation. The operative findings included 2 cases of "external" BE through the lesser curvature into the stomach and 4 cases of "internal" BE through the circular staple

### See Invited Commentary at end of article

line (**Figure 2**). The surgical techniques varied depending on the radiological and endoscopic data and on the operative findings.

External BE caused important inflammatory responses in granulation tissue due to the extragastric involvement. In the first case of external BE (patient 1), the band was removed through a distal gastrotomy and



**Figure 1.** An upper gastrointestinal tract image showing the erosion of the band into the stomach.

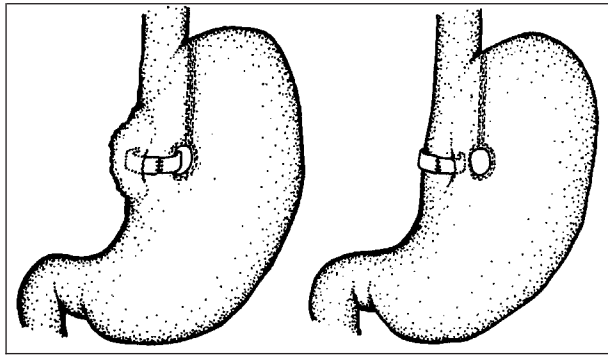
the stenotic gastric lumen was dilated by means of a Gruntzig catheter. For patient 2, the problem was solved by converting the VBG into a gastric bypass (according to the Torres and Oca technique<sup>11</sup>) and removing the inflammatory area involving the band (**Figure 3**).

In the instances of internal BE, there was enlargement of the pouch and not much inflammatory reaction. After band removal, a new circular stoma was created over and internal to the old one; a new band was replaced in 3 instances (patients 4-6), as shown in **Figure 4**. Finally, in patient 7, the VBG was converted into a Salmon technique<sup>9</sup> because of the "sweeter" eating habit of this patient (**Figure 5**).

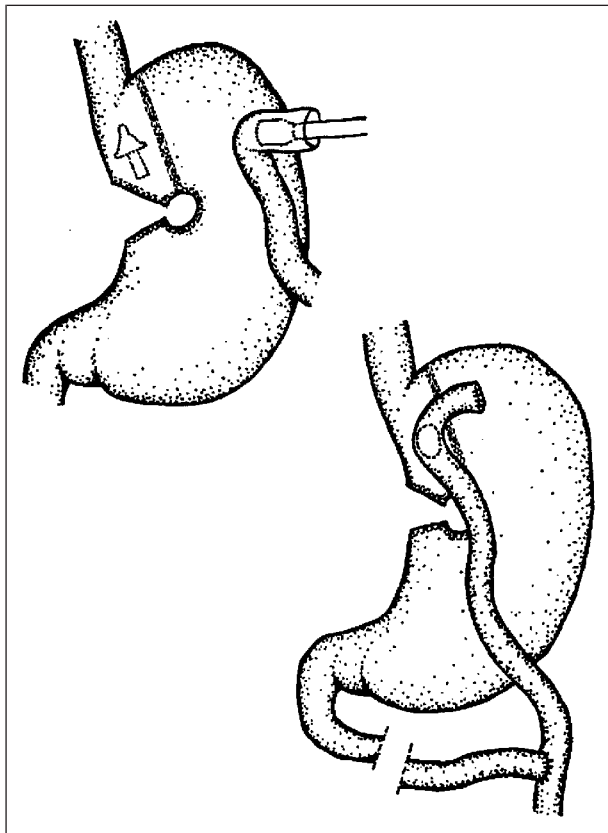
The average ( $\pm$ SD) operative time was  $90\pm 15$  minutes, and the average ( $\pm$ SD) hospital stay was  $7\pm 2$  days. There were no complications. The weight evolution of these patients is shown in the **Table**. The patient who did not undergo reoperation (patient 3) gained weight after the first year of follow-up, and an upper GI tract roentgenographic series showed enlargement of the gastric stoma. This patient is still under observation and is scheduled for reoperation using the Salmon technique.<sup>9</sup>

#### COMMENT

When functioning correctly, VBG is a simple, effective, and safe operation for the treatment of morbid obesity.<sup>3,4,12,13</sup> However, a few technical problems may hamper its long-

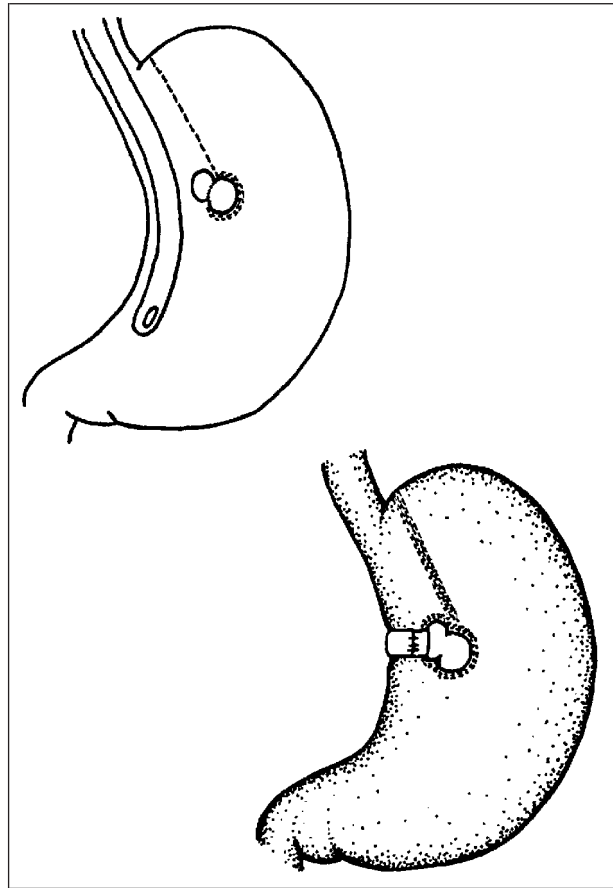


**Figure 2.** "External" band erosion through the lesser curvature into the stomach (left) and "internal" band erosion through the circular staple line (right).



**Figure 3.** Surgical repair of "external" band erosion. Conversion to a Torres and Oca<sup>11</sup> gastric bypass occurred.

term results. Staple-line disruption, the erosion and migration of the band into the stomach, stoma ulcers, or stenosis are late complications of this technique.<sup>14</sup> The actual incidence of BE is not well-known. Several series of patients who have undergone VBG have reported BE rates varying between 1% and 7%.<sup>15-17</sup> This complication generally occurred 1 to 3 years after surgery, and patients' initial symptoms were abdominal discomfort and vomiting. A few causes have been thought to produce BE, including excessively tight bands, contamination and infection of the band, and reinforcement of the circular staple line. An excessively tight band may create a shelf of enfolded stomach at the site of the band. To avoid this complication, it is essential that an Ewald or Fouchet tube (1 cm in diam-



**Figure 4.** Surgical repair of "internal" band erosion. A new circular stoma was created after band extraction.

eter) pass easily through at the moment of the operation. A contaminated band causes erosion of the wall and appearance of the band in the lumen.<sup>7</sup> There is more opportunity for band contamination with GI tract organisms during reparative operations compared with primary VBG. Finally, there are no data showing that the reinforcement of the circular suture reduces the incidence of late staple-line disruption or BE.

Conversely, our study suggests that forced endoscopy favors the development of BE, and this potential risk must be kept in mind when examining patients with food obstruction. This is consistent with our hypothesis that BE is likely the consequence of mechanical stress, such as vomiting or overdistention of the upper gastric pouch.

The composition of the band seems to be unrelated to the development of BE. However, we prefer to use polytef bands because they are easier to remove in case of a reparative operation. Subrayaman and Robins<sup>8</sup> described endoscopic extraction, but this procedure may cause patients to lose their bariatric technique and a weight increase is possible. In our study, patient 3 had not undergone any reparative technique since the band fell. However, this patient began to gain weight after the first year of follow-up. Patients suffering from BE usually have symptoms of upper GI tract obstruction. Therefore, periodic barium studies are recommended. Moreover, BE may go unnoticed if radiological studies are not routinely performed. If the diagnosis of BE is missed, it may

be erroneously concluded that VBG is a technique with poor long-term results.<sup>18</sup> In our opinion, endoscopy is essential for confirming the diagnosis of BE, particularly in those instances of partial inclusion; endoscopy also helps in planning the reoperation.

Although the Reinhold evaluation method<sup>10</sup> and the BMI provide easy ways to assess actuarial and final weight results, both methods may be confusing and may lead to misinterpretations if the quality of life is not considered. Patients may lose weight at the expense of vomiting. Personal interviews should rule out this outcome. Reparative techniques for BE depend on the operative findings and on the surgeon's experience.

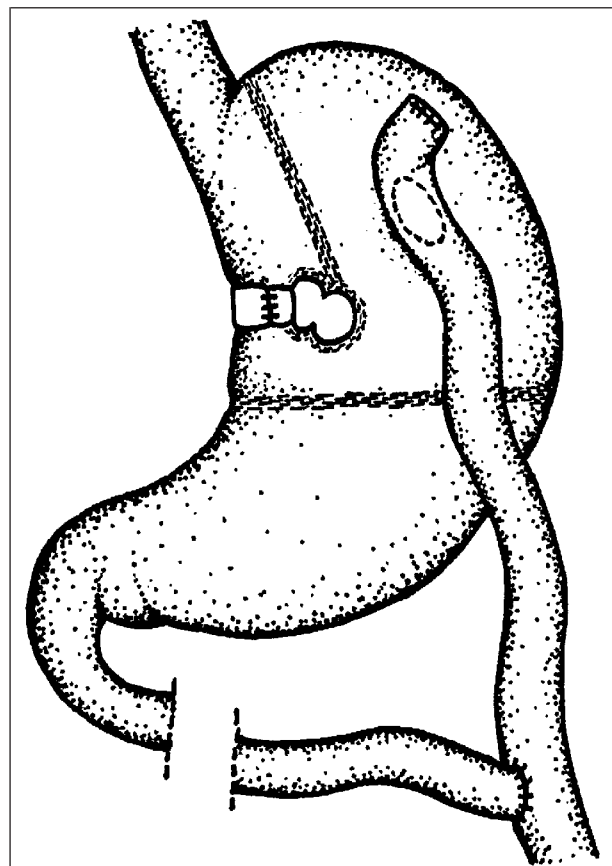


Figure 5. Conversion to the Salmon technique.<sup>9</sup>

External BE usually produces important inflammatory reactions, as in covered, free perforations (eg, perforated stomach ulcers covered by the omentum, which prevents diffuse peritonitis). There is extragastric involvement in granulation tissue without epithelial proliferation. The best solution in this case implies an eventual resection of the involved area and conversion to a Torres and Oca bypass,<sup>11</sup> whenever possible.

Internal BE may not be clearly noticed on the surgical field because it evolves as a long-term process, usually producing a slight inflammatory response. The presence of BE may easily be confirmed by turning the band, which will show a dark mark caused by the action of the gastric juice. Internal BE usually creates a double passage with gastric epithelium, which is not wide enough and acts as a lumen stenosis. This causes the upper gastric pouch to become dilated.

When there is no associated staple-line disruption and no excessive inflammatory reaction, we suggest removing the band and creating a new circular stoma above and internal to the old one, thus replacing it with a new band. In the event of a concomitant staple-line disruption, we recommend conversion to a Salmon technique<sup>9</sup> after removing the band, to avoid gastric necrosis, compared with restapling. The revisional surgery, maintaining a VBG design, is advisable if the patient is a good candidate for this procedure. As described in recent studies,<sup>3,19,20</sup> patients with sweeter eating habits or supermorbid obesity might benefit from malabsorptive (ie, gastric bypass) or partially malabsorptive (ie, Salmon technique<sup>9</sup>) methods.

A bariatric procedure must be performed if weight control is desired because an unbanded gastroplasty is an unsatisfactory operation.<sup>18</sup> The conversion of a failed initial procedure to another effective operation should be considered, as the nonsurgical treatment of morbid obesity is usually unsuccessful and a patient may then have a new technical iatrogenic problem.

This study provides some suggestions that may prove useful to surgeons confronted with these complications in their current practice.

*This study was supported in part by Fondo de Investigaciones Sanitarias de la Seguridad Social 95/0753 from the Spanish Department of Public Health.*

#### Weight Evolution of the Patients in This Study

Patient No.	Time, mo*	Reparative Technique†	Initial Weight, kg	Weight, kg		
				At Month 6	At Month 12	At Month 24
1	9	E	135	85‡	75	90
2	14	TO	125	89	81‡	72
3	4	...	117	83	81	89
4	7	BR	127	75‡	77	75
5	8	BR	115	73‡	75	71
6	10	BR	131	85‡	77	73
7	9	S	147	81‡	81	73

\*Time of occurrence of band erosion after surgery.

†E indicates simple extraction; TO, the Torres and Oca technique<sup>11</sup>; BR, band replacement after the creation of a new stoma; S, the Salmon technique<sup>9</sup>; and ellipses, data not applicable.

‡The moment of reoperation for these patients.



Corresponding author: Antoni Alastrué, MD, Department of General Surgery, Planta 6a, Hospital Universitari Germans Trias i Pujol, Ctra de Canyet s/n, 08916 Badalona, Barcelona, Spain (e-mail: 26319pms@comb.es).

## REFERENCES

1. Benotti PN, Forse RA. The role of gastric surgery in the multidisciplinary management of severe obesity. *Am J Surg*. 1995;169:361-367.
2. Sugeran HJ. Surgery for morbid obesity. *Surgery*. 1993;114:865-867.
3. MacLean JD, Rhode BM, Forse RA. Late results of vertical banded gastroplasty for morbid and super obesity. *Surgery*. 1990;107:20-27.
4. Mason EE. Vertical banded gastroplasty for obesity. *Arch Surg*. 1982;117:701-706.
5. Alastrué A, Rull M, Formiguera X, et al. Obesidad severa: tratamiento quirúrgico en 120 pacientes: resultados y enfoque prospectivo. *Nutr Hosp*. 1993;7:411-423.
6. Alastrué A, Formiguera X, Rull M. Cirugía bariátrica, gastroplastia vertical anillada: obesidad mórbida y superobesidad: resultados antropométricos, complicaciones técnicas y reintervenciones a largo plazo. *Endocrinología*. 1992;38:365-375.
7. Yale CE. Conversion surgery for morbid obesity: complications and long-term weight control. *Surgery*. 1989;106:474-480.
8. Subrayaman K, Robins HT. Erosion of Marlex band and silastic ring into the stomach after gastroplasty: endoscopic recognition and management. *Am J Gastroenterol*. 1989;84:1319-1321.
9. Salmon PA. Gastroplasty with distal gastric bypass: a new and more successful weight loss operation for the morbidly obese. *Can J Surg*. 1988;31:111-113.
10. Reinhold RB. Critical analysis of long-term weight loss following gastric bypass. *Surg Gynecol Obstet*. 1982;155:385-394.
11. Torres J, Oca C. Gastric bypass lesser curvature with distal Roux-en-Y. *Bariatric Surg*. 1987;5:10-15.
12. Alastrué A, Rull M, Formiguera X, Casas D, Vila P, Broggi MA. Obesidad severa: reflexiones sobre un protocolo quirúrgico (I y II). *Nutr Hosp*. 1995;6:307-330.
13. Mason EE. Reoperation for failed gastric bypass: procedures for obesity. *Surg Clin North Am*. 1991;1:45-56.
14. Cates JA, Drenick EJ, Abedin MZ, Doty JF, Roslyn JJ. Reoperative surgery for the morbidly obese: a university experience. *Arch Surg*. 1990;125:1400-1404.
15. Morino F, Toppino M, Fronda G, Tapparo A, Avagnina S. Weight loss and complications after vertical banded gastroplasty. *Obes Surg*. 1992;2:69-73.
16. Owen ERT, Abraham R, Kark AE. Gastroplasty for morbid obesity: technique, complications and results in 60 cases. *Br J Surg*. 1989;76:131-135.
17. MacLean LD, Rhode BM, Forse RA. A gastroplasty that avoids stapling in continuity. *Surgery*. 1993;113:380-388.
18. Linner HL, Drew RL. Reoperative surgery: indications, efficacy and long-term follow-up. *Am J Clin Nutr*. 1992;55(suppl):606S-670S.
19. Sagar PM. Surgical treatment of morbid obesity. *Br J Surg*. 1995;82:732-739.
20. Salmon PA. Gastroplasty/distal gastric bypass: an operation producing excellent and prolonged weight loss in the superobese. *Obes Surg*. 1993;3:391-39.

## Invited Commentary

This is a retrospective study of 250 obese patients operated on consecutively during an 8-year period using vertical banded gastroplasty with a 10- to 15-mL pouch and a 5-cm band of expanded polytetrafluoroethylene (also known as PTFE) (Gortex, WL Gore and Associates Inc, Flagstaff, Ariz). An erosion of the band into the stomach developed in 7 (2.8%) of these patients; all 7 patients experienced excessive weight loss and symptoms of partial obstruction. The cause of erosion was probably a tight band in all patients, and the erosion was hastened by forceful endoscopy in 2 patients. Excision of the eroded band and adjacent inflamed stomach with reformation of a new pouch and Roux-en-Y reconstruction is an attractive solution to this problem. I find reinsertion of another band in a contaminated field less attractive, but the authors used this method only with lateral erosion. The idea of using the Salmon technique<sup>1</sup> to avoid restapling an open staple line is also a useful method to consider in that special circumstance of lateral band erosion and staple-line dehiscence. The removal of the band by endoscopy or by gastrotomy (as done in patient 1) is not satisfactory, as the authors emphasize. In one of their patients in whom an erosion developed, as determined by endoscopy, the band was later not visible. This, in our experience, means that the band has eroded into the lumen of the stomach and has been passed. The late result in this setting is unacceptable weight gain. Late follow-up (5-year) data on how closely weight approximates normal values (data not provided) and information on eating habits will be of interest.

Lloyd D. MacLean, MD  
McGill University  
Royal Victoria Hospital  
Montreal, Quebec

1. Salmon PA. Gastroplasty with distal gastric bypass: a new and more successful weight loss operation for the morbidly obese. *Can J Surg*. 1988;31:111-113.