

Alternative Strategies in the Management of Primary Breast Cancer

Roger S. Foster, Jr, MD; William C. Wood, MD

This article will review the current alternative strategies in the management of primary breast cancer with an emphasis on the reasons we prefer a particular strategy. We will attempt to forecast new alternatives that we expect to emerge from advances in the molecular biology of breast cancer, as well as other technological advances.

Arch Surg. 1998;133:1182-1186

There is little modern data on the outcome of untreated breast cancer. Bloom,¹ however, summarized the results of 1728 untreated cases diagnosed between 1800 and the early 1900s. Bloom's patients had a 5-year survival rate of 18.5%, a 10-year survival rate of less than 5%, and fewer than 1% of patients were alive at 15 years.¹

Despite this large number of untreated cases collected by Bloom, the history of surgical treatment of breast cancer goes back at least 2000 years. During this time surgeons have moved back and forth between the alternatives of local excision of the cancer and more extensive operations such as total mastectomy or radical mastectomy with removal of muscles and axillary nodes.² Ambroise Pare (1510-1590) advocated local excision for smaller tumors, as well as the application of topical agents; Andreas Versalius (1514-1564) treated breast cancer by wide local excision; Laurentius Heister (1683-1758) resected the breast as well as both muscle and ribs in cases in which there was extension of the cancer; and James Syme (1789-1870) advocated wide and complete excision including removal of the axillary nodes.²

In the 19th century most surgeons apparently treated breast cancers by limited resections, with local recurrence being the rule. Alexander Monro (1773-1859) found only 4 of 60 patients treated by local resection to be free of disease at 2 years. Sir James Paget (1814-1899) operated on 235 patients and wrote, "We may, I think, dismiss that the operation will be the final remedy of the disease."²

In 1867, Charles Moore elaborated basic principles of breast cancer surgery that

by the 20th century became widely accepted. He wrote, "It is desirable to avoid not only cutting into the tumor but also seeing it . . . lest the active microscopic elements in it should be set free and lodge in the wound. Diseased axillary glands should be taken away at the same dissection as the breast itself."³ Routine axillary dissection in the treatment of breast cancer was practiced as early as 1871 by Kuster⁴ in Germany and by Banks⁵ in England by 1878. In the United States, publications by Halsted^{6,7} in 1894 and 1907 contributed to wide acceptance of radical mastectomy during the first three quarters of the 20th century, with removal of pectoral muscles and axillary nodes becoming the standard surgical treatment for primary breast cancer. Most patients in Halsted's era had advanced disease, and three quarters of Halsted's patients had axillary node metastases. The 10-year survival rate for Halsted's patients was 12%, but his local and regional recurrence rate was far lower than that of most of his surgical contemporaries, who were doing limited resection for advanced breast cancers.⁸ Throughout the first three quarters of the 20th century there were progressively improving results from radical mastectomy, not because of significant changes in technique but because of a combination of patients presenting with earlier stages of disease and surgeons having stricter criteria for selection of operable cases.

BREAST CONSERVATION AS AN ALTERNATIVE TO TOTAL MASTECTOMY

Following multiple retrospective reports of 20th-century breast cancer patients treated with breast-conserving procedures that seemed to be much more suc-

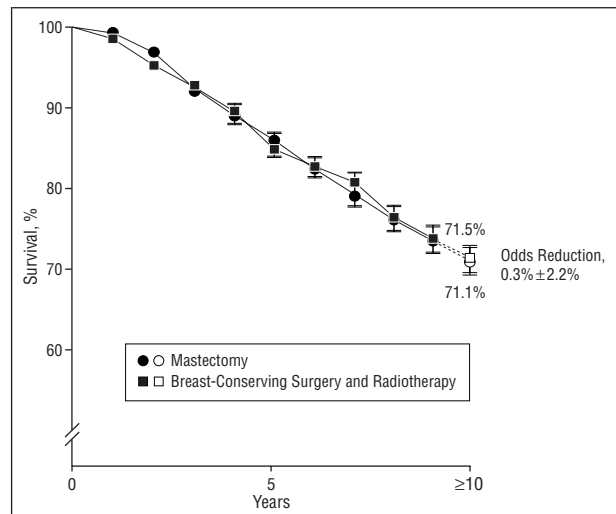
From the Whitehead Department of Surgery, Emory University School of Medicine, Atlanta, Ga.

cessful than prior attempts, 7 prospective randomized trials were carried out to compare mastectomy with breast-conserving treatment.⁹ These trials have convincingly demonstrated that for invasive breast cancer there is no difference in either overall survival or long-term disease-free survival when mastectomy is compared with breast-conserving treatment (**Figure**). Recurrence of cancer in the breast after breast-conserving surgery has been seen in 3% to 17% of the patients in the randomized studies, compared with 2% to 10% chest wall recurrence in the mastectomy patients. The majority of patients with recurrence in the breast after breast-conserving surgery can be salvaged with a mastectomy. Additional local failures after salvage mastectomy have been reported in approximately 5% of patients.

We have found that the alternative of breast-conserving surgery is appropriate management for two thirds to three quarters of our patients with breast cancer.¹⁰ However, meeting the dual goals of optimum cosmesis and minimal rates of in-breast recurrence after breast-conserving surgery requires the selection and integration of appropriate breast imaging techniques, breast biopsy techniques, breast irradiation techniques, and systemic cytotoxic and hormonal therapies.

To reduce the rate of in-breast recurrence after breast-conserving surgery, it is important to have margins that are histologically tumor free. When breast irradiation is a part of the breast conservation treatment, wide tumor-free margins have little importance. While resection margins that are grossly involved by tumor lead to high rates of in-breast recurrence, close margins and even minimally focally involved margins have not been associated with higher rates of in-breast recurrence after appropriate breast irradiation.¹¹⁻¹³ Optimum cosmesis is obtained by omitting resection of skin (unless absolutely necessary because of tumor extension) and by resecting only a small rim of normal breast tissue around the tumor, a procedure that is better described as a "lumpectomy" than a "quadrantectomy."

Several contraindications to breast-conserving surgery have been proposed, such as pregnancy, tumor near the nipple, collagen vascular disease, previous radiation therapy, and 2 tumors in separate quadrants of the breast,¹⁴ but there are alternatives that make these only relative contraindications. For example first- or second-trimester pregnancy is listed as a contraindication to breast-conserving surgery, but the contraindication really refers to radiation therapy during the pregnancy. The alternative is to delay radiation therapy until after the birth; most radiation therapy is actually delayed following breast-conserving surgery because chemotherapy is usually given for several months prior to radiation therapy. Tumor location beneath the nipple is not a contraindication; the resection may need to include the nipple-areolar complex but, with preservation of most of the breast volume, good cosmesis that is superior to that found with a reconstruction can usually be obtained. Most women accept the absence of the nipple-areolar complex, but the option of plastic surgery is available for those who desire it. Collagen vascular disease is an issue for increased adverse effects from radiation therapy only when there is active disease. Areas previously irradiated have been successfully retreated with ra-



Ten-year survival among approximately 3100 women in 7 randomized trials comparing mastectomy with breast-conserving surgery plus radiotherapy. Copyright 1995 Massachusetts Medical Society. All rights reserved. Adapted with permission, 1998.

diation therapy; morbidity is dependent in part on previous radiation therapy doses.¹⁵⁻¹⁸

INDUCTION CHEMOTHERAPY BEFORE BREAST-CONSERVING SURGERY

For patients in whom the size of the primary tumor relative to the size of the breast makes breast-conserving surgery an inappropriate choice, an alternative to mastectomy is preoperative chemotherapy. Frequently there will be enough shrinkage of the primary tumor that cosmetically satisfactory breast-conserving surgery becomes possible. A large randomized trial carried out by the National Surgical Adjuvant Breast and Bowel Project has shown equivalent survival rates when the chemotherapy is given prior to the breast surgery rather than the more traditional sequence of surgery followed by chemotherapy.¹⁹

MEDICAL TREATMENT AS AN ALTERNATIVE TO RADIOTHERAPY AFTER BREAST-CONSERVING SURGERY

The question has been raised as to whether systemic chemotherapy or hormonal therapy might substitute for radiation therapy after breast-conserving therapy. The adjuvant chemotherapy treatments used to date, when used without radiation therapy, have not greatly reduced the rate of local recurrence, but in combination with breast irradiation some recent clinical trials have shown that when systemic therapies are combined with irradiation, the 5-year rates of first recurrence in the breast are 2% or less.^{20,21} Several reviews of patients older than 70 years with T1 and T2 have shown a low risk of recurrence after wide local excision and tamoxifen (without radiotherapy).²²⁻²⁴

TAMOXIFEN IN ELDERLY PATIENTS AS PRIMARY THERAPY

For elderly patients with hormone receptor-positive tumors who have either limited life expectancy or extreme

aversion to even limited surgical excision, tamoxifen may be a reasonable alternative as the sole therapy.²⁵ For most elderly patients, lumpectomy and tamoxifen will be a more appropriate alternative. While mastectomy under general anesthesia in frail elderly patients may have mortality rates of 1% to 2%,²⁶ lumpectomies under local anesthesia should have low morbidity and mortality and provide effective tumor control when combined with tamoxifen.

IN SITU ABLATION OF THE PRIMARY TUMOR AS AN ALTERNATIVE TO SURGERY

The availability of imaging techniques, such as stereotactic mammography or ultrasonography, should permit relatively precise placement of probes to locally destroy tumors with thermal techniques. Very preliminary studies are beginning to explore the possibility of ablating primary breast tumors in situ by freezing with cryosurgery or coagulating with heat, delivered by laser fiberoptic technique.²⁷⁻³⁰

OBSERVATION WITHOUT SPECIFIC MEDICAL THERAPY

While most cases of breast cancer deserve some sort of specific antitumor treatment, the alternative of observation only may be appropriate for patients with asymptomatic tumors. Such an alternative may be particularly appropriate for patients with indolent invasive tumors when life expectancy is very limited because of other disease. Observation might also be an appropriate alternative in the elderly patient with ductal carcinoma in situ.

BREAST RECONSTRUCTION AS AN ALTERNATIVE TO BREAST-CONSERVING SURGERY

While only a small portion of mastectomy patients in the United States have breast reconstruction, in some specialized clinics most patients who undergo total mastectomy have immediate breast reconstruction. To some extent breast reconstruction competes with breast-conserving surgery. While for most women the maintenance of breast sensation and the cosmetic appearance of breast-conserving surgery make it preferable to total mastectomy and reconstruction, some women prefer reconstruction as a way to avoid irradiation therapy, or they may like the concept that near-total removal of all of the breast tissue reduces the concerns about in-breast recurrence or the development of a new primary breast cancer in the treated breast.

Breast-conserving surgery may not be appropriate either because of size or extent of tumor, patient preference for total mastectomy, or, rarely, because of some contraindication to radiotherapy. Most patients for whom total mastectomy is either necessary or is elected are candidates for breast reconstruction, either with autologous tissue, with an implant, or with a combination approach.

ALTERNATIVE BIOPSY TECHNIQUES FOR PALPABLE BREAST LESIONS

The traditional approach to the diagnosis of breast cancer has been by excisional or incisional open biopsy of

the suspect lesion followed by microscopic examination of sections prepared by either frozen section technique or after paraffin embedding. We believe that the best alternatives for making the pathological diagnosis of palpable breast cancers are fine-needle aspiration biopsies or core cutting needle biopsies. Needle biopsy diagnosis prior to excision of a palpable breast cancer has the advantages of permitting efficient preoperative staging workup, patient education and informed consent, and coordination with other portions of the management (eg, regional node procedures, preoperative vs postoperative chemotherapy), and has been associated with lower rates of tumor at the margins of resection because the surgeon's mindset at the time of surgery is toward assuring a complete resection.

Fine-needle aspiration biopsy in skilled hands is an excellent technique associated with a very low rate of false-positive diagnoses and low rates of false-negative diagnoses.³¹ The success of fine-needle aspiration biopsy is dependent on a high degree of skill by the aspirator in obtaining and properly preparing the sample and requires a pathologist specially trained and skilled in cytopathological interpretation. Noninvasive breast cancer cannot usually be distinguished from invasive breast cancers by fine-needle aspiration biopsy, but when the cytological results are positive and when the mammogram and the clinical examination results are characteristic of an invasive breast cancer (the so-called triple test), the patient can be definitively treated with confidence.

An alternative to fine-needle aspiration biopsy that may be more suitable in some medical environments is core needle biopsy. Core cutting needle biopsies with the spring-loaded automated biopsy guns provide tissue cores suitable for histological examination following either routine or frozen section processing. The possibility that a particularly hard breast cancer will lead to a false-negative diagnosis by displacing the core needle into adjacent normal breast tissue is much lower with the automatic needle than with the previous manual core biopsies. Histological interpretation of the core biopsy specimens does not require the pathologist to have special cytopathological skills.

We believe that the excision of palpable breast masses without preliminary needle biopsy should be restricted to young women and to cases in which the mass has clinical and imaging characteristics that virtually assure the surgeon that it is benign. We believe the alternative of preliminary needle biopsy is preferable in all other patients.

ALTERNATIVE BIOPSY TECHNIQUES FOR NONPALPABLE LESIONS

Screening mammography has been shown to reduce breast cancer mortality by at least 30% by detection of clinically occult lesions^{32,33} but, for every malignant lesion detected, 2 to 6 benign but "suspicious" occult lesions are detected for which biopsy is recommended.³⁴ Compliance with screening guidelines could result in more than 1 million breast biopsies per year in the United States. For nonpalpable mammographically detected lesions, excisional biopsy after image-guided needle localization has been the

criterion standard for making a tissue diagnosis. It is the only method that gives the pathologist the opportunity to characterize the entire lesion. If the lesion proves to be malignant and the margins of excision are negative, the breast surgery portion of breast-conserving treatment may be finished with this single procedure.

There are alternative "closed biopsy" image-guided tissue sampling techniques that may frequently be preferable to image-guided open biopsy. Potential advantages of closed biopsy techniques include shorter procedure times, less breast scarring and deformity, less discomfort, and less expense when the lesion proves to be benign. A potential disadvantage is that the limited sampling could lead to a false-negative diagnosis, although with appropriate safeguards and follow-up breast imaging this problem has proved to be little different than after open biopsy techniques. The potential advantages of the open technique if the lesion proves to be malignant have been described earlier, but disadvantages include incomplete excisions because the surgeon did not have a preoperative diagnosis of cancer and lower success rates for sentinel node biopsy techniques after excisional biopsies.

Alternative image-guided closed biopsy techniques are fine-needle aspiration biopsy, large-core biopsies with the automated gun, and suction trocar core biopsies. Each of these biopsy procedures can be directed either by stereotactic mammography equipment or by ultrasonography equipment. Image-guided biopsies may also be carried out using advanced breast biopsy instrumentation equipment, which permits an image-directed open excisional biopsy of small lesions.

ALTERNATIVE STRATEGIES FOR THE MANAGEMENT OF REGIONAL NODES

In primary breast cancer, metastases to the regional nodes are the most important predictor of occult systemic metastases. Nodal metastases can cause considerable morbidity if uncontrolled and if untreated may occasionally be a source of systemic metastases. Most regional node metastases are to the axillary nodes, but when there are metastases only to 1 of the 2 nodal basins (axilla or internal mammary), the internal mammary nodes alone are involved 10% of the time.³⁵ Between 4% and 9% of patients with T1 and T2 will have internal mammary node metastases when there are no axillary metastases. Randomized trials have convincingly demonstrated that there is no survival advantage to surgical resection of internal mammary nodes.³⁶ The alternative of radiation therapy to the internal mammary nodes remains the subject of debate. Meta-analyses of the randomized radiation therapy trials have as yet shown no overall survival advantage; however, there does seem to be a tradeoff of fewer breast cancer deaths after irradiation with more cardiovascular (cardiac) deaths.³⁷ Proponents of internal mammary node irradiation argue that modern radiation techniques that spare the heart should lead to fewer late cardiac deaths.^{38,39}

Alternative treatments for clinically evident regional node metastases are surgical resection, radiation therapy, and medical treatment with chemotherapy or hormonal therapy. Because radiation therapy for bulky nodes is frequently ineffective, surgical resection for clinically

evident axillary nodes has become the most generally accepted therapy. Chemotherapy, however, as part of combined treatment may permit nonsurgical alternatives. Induction chemotherapy can reduce bulky nodal disease, perhaps making it amenable to sterilization with radiation therapy, and in some cases may completely eliminate histological evidence of nodal metastases.¹⁹ There is less experience regarding the response of nodal metastatic disease to hormonal therapy, but some patients with hormone receptor-positive tumors will have regression of the nodes under treatment with hormonal therapy.

If the medical therapy leads to the nodes becoming clinically negative, the patient may become a good candidate for the alternative of radiation therapy, or even observation and additional regional treatment only if there is evidence of disease recurrence.

For clinically negative nodes, observation with treatment only when there is clinical evidence of disease progression is an additional alternative to surgery, radiation therapy, and medical therapy. Randomized clinical trials have shown that even in the pre-mammographic era, when approximately 40% of patients with clinically negative axillary nodes had histological evidence of nodal metastases, adequate therapy at the time of first evidence of disease progression led to regional control rates little different from those obtained with prophylactic resection. A meta-analysis of these randomized trials indicates that if observation led to a survival disadvantage it was probably in the range of 4%.⁴⁰ For clinically negative axillary nodes, surgical and radiation therapy provide equivalent rates of regional disease control; however, surgical resection provides histological evidence of nodal metastases for prognosis and perhaps for the guidance of systemic adjuvant therapy.

The concept of sentinel node biopsy has received much attention as a possible alternative to axillary node dissection. The concept is that in a given patient the lymphatic drainage, such as from the breast to the axilla basin, is not random but goes first to a specific single node (or occasionally several nodes) and only secondarily to other nodes in the basin.⁴¹⁻⁴⁴ It is possible to identify the sentinel nodes by injection of a marker such as a blue dye or a radionuclide into the breast at the site of the tumor. The sentinel nodes are identified either by visual inspection or with a handheld gamma probe. Surgeons who have passed through the learning curve can identify the sentinel node more than 95% of the time. Initial data indicate that if there is no evidence of metastasis to the sentinel node, the likelihood of metastasis to other nodes in the regional basin is very low (<3%). Many surgeons are beginning to accept a negative sentinel node biopsy result as adequate staging of the axilla. When the sentinel node is positive for metastatic disease, most surgeons recommended an axillary dissection, but radiation therapy to the axilla would be a therapeutic alternative. An additional alternative being proposed for a randomized clinical trial in patients with T1 and T2 and a positive axillary sentinel node would be observation of the axilla, with no deliberate treatment other than the patient's systemic chemotherapy and the irradiation of the low axillary nodes that are incidental to the tangential radiation field for the breast after breast-conserving surgery (Armando Giuliano, MD, oral and written communications, 1998).

THROUGH THE GLASS DARKLY

The increasing knowledge of the molecular genetics of cancer in general, and breast cancer in particular, hold great promise for further altering and perhaps eliminating the current surgical role in the treatment of breast cancer. One can only guess which techniques will prove most successful. Among the candidates as future treatments are antiangiogenesis agents that starve cancers by inhibiting their blood supply, antibodies targeted to specific receptors on the surface of cancer cells, agents that enhance programmed cell death, agents that induce differentiation, and gene therapy for the replacement of mutated or defective genes.

LEGITIMATE ALTERNATIVES VS QUACKERY AND OPPORTUNISTIC PREDATORS

We probably have not covered all of the legitimate alternatives in the treatment of primary breast cancer, with their varying degrees of scientific support. Unfortunately the term "alternative treatment" has also been applied to a wide variety of pseudoalternatives promoted by opportunists, quacks, and occasionally misguided and ill-informed but well-meaning individuals. Proponents of these pseudoalternatives prey on the vulnerability of patients and their families, who are faced with a disease for which standard treatments and legitimate alternative treatments are imperfect. One should be particularly wary of alternative treatments when their proponents claim they have an unusual or secret treatment, or a treatment that has been overlooked by medical science. Physicians and scientists are always on the watch for new clues and treatments for cancer, no matter how unusual they seem, but they also seek to evaluate them for effectiveness and safety. Pseudoalternatives that waste time, steal resources, and deprive loved ones of periods of companionship are not suitable alternatives but are unacceptable rivals of rational and responsible health care.

Reprints: Roger S. Foster, Jr, MD, Crawford Long Hospital of Emory University, 550 Peachtree St NE, Atlanta, GA 30365-2225.

REFERENCES

1. Bloom HJG. Survival of women with untreated breast cancer: past and present. In: Forrest APM, Kunkler PB, eds. *Prognostic Factors in Breast Cancer*. Baltimore, Md: Williams & Wilkins; 1968.
2. Mansfield CM. Early breast cancer: its history and results of treatment. *Exp Biol Med*. 1976;5:1-121.
3. Moore CH. On the influence of inadequate operations on the theory of cancer. *R Chir Soc*. 1867;1:244-280.
4. Kuster E. Zur Behandlung des Brustkrebses. *Arch F Clin Chirg*. 1883;29:723-753.
5. Banks WM. A brief history of the operations practiced for cancer of the breast. *BMJ*. 1902;1:5-10.
6. Halsted WS. The results of operations for the cure of cancer of the breast performed at the Johns Hopkins Hospitals. *Ann Surg*. 1894;20:497-555.
7. Halsted WS. The results of radical operations for the cure of carcinoma of the breast. *Ann Surg*. 1907;46:1-19.
8. Lewis D, Rienhoff WF. A study of results-Johns Hopkins Hospital, 1889-1931. *Ann Surg*. 1932;25:336-400.
9. Early Breast Cancer Trialists' Collaborative Group. Effects of radiotherapy and surgery in early breast cancer. *N Engl J Med*. 1995;333:1444-1445.
10. Foster RS Jr, Farwell ME, Costanza, MC. Breast-conserving surgery for breast cancer: patterns of care in a geographic region and estimation of potential applicability. *Ann Surg Oncol*. 1995;2:275-280.
11. Fisher B, Redmond C, Poisson R, et al. Eight-year results of a randomized clinical trial comparing total mastectomy and lumpectomy with or without irradiation in the treatment of breast cancer. *N Engl J Med*. 1989;320:822-828.
12. Anscher M, Jones P, Prosnitz L, et al. Local failure and margin status in early-stage breast carcinoma treated with conservative surgery and radiation therapy. *Ann Surg*. 1993;218:22-28.
13. Schnitt S, Abner A, Gelman R, et al. The relationship between microscopic margins of resection and the risk of local recurrence in breast cancer patients treated with conservative surgery and radiation therapy. *Cancer*. 1994;74:1746-1751.
14. Winchester D, Cox J. Standards for breast conservation treatment. *CA Cancer J Clin*. 1992;42:134-162.
15. Cowen D, Altschuler C, Blane B, et al. Second conservative surgery and brachytherapy for isolated breast carcinoma recurrence [abstract]. In: *Program and Abstracts of the European Society of Mastology*. Venice, Italy: European Society of Mastology; 1994:146.
16. Mullen E, Deutsch M, Bloomer W. Re-excision and reirradiation of local recurrence for salvage of lumpectomy failures [abstract]. *Proc Am Soc Clin Oncol*. 1992;11:60.
17. Recht A, Schnitt SJ, Connolly JL, et al. Prognosis following local or regional recurrence after conservative surgery and radiotherapy for early stage breast carcinoma. *Int J Radiat Oncol Biol Phys*. 1989;16:3-9.
18. Stotter A, Kroll S, McNeese M, et al. Salvage treatment of locoregional recurrence following breast conservation therapy for early breast cancer. *Eur J Surg Oncol*. 1991;17:231-236.
19. Fisher B, Brown A, Mamounas E, et al. Effect of preoperative chemotherapy on local-regional disease in women with operable breast cancer: findings from National Surgical Adjuvant Breast and Bowel Project B-18. *J Clin Oncol*. 1997;15:2483-2493.
20. Fisher B, Redmond C, and the National Surgical Adjuvant Breast and Bowel Project. Lumpectomy for breast cancer: an update of the NSABP experience. *J Natl Cancer Inst Monogr*. 1992;11:7-13.
21. Levine M, Gent M, Hryniuk W, et al. A randomized trial comparing 12 weeks versus 36 weeks of adjuvant chemotherapy in stage II breast cancer. *J Clin Oncol*. 1990;8:1217-1225.
22. Nemoto T, Patel J, Rosner D, et al. Factors affecting recurrence in lumpectomy without irradiation for breast cancer. *Cancer*. 1991;67:2079-2082.
23. Cooke A, Perera F, Fisher B, et al. Tamoxifen with and without radiation after partial mastectomy in patients with involved nodes. *Int J Radiat Oncol Biol Phys*. 1995;31:777-781.
24. Lee K, Plowman P, Gilmore O, et al. Breast conservation therapy: how safe is postoperative tamoxifen? only in the elderly and frail [abstract]. *Proc Am Soc Clin Oncol*. 1992;11:50.
25. Margolese RG, Foster RS Jr. Tamoxifen as an alternative to surgical resection for selected geriatric patients with primary breast cancer. *Arch Surg*. 1989;124:548-551.
26. Morrow M. Breast disease in elderly women. *Surg Clin North Am*. 1994;74:145.
27. Staren ED, Sabel MS, Gianakakis LM, et al. Cryosurgery of breast cancer. *Arch Surg*. 1997;132:28-33.
28. Robinson DS, Parel J-M, Denham DB, et al. Stereotactic uses beyond core biopsy: model development for minimally invasive treatment of breast cancer through interstitial laser hyperthermia. *Am Surg*. 1996;62:117-118.
29. Robinson DS, Parel J-M, Denham DB, et al. Interstitial laser hyperthermia model development for minimally invasive therapy of breast carcinoma. *J Am Coll Surg*. 1998;186:284-292.
30. Dowlatshahi K, Bauich D, Kluber R. Histologic evaluation of rat mammary tumor necrosis by interstitial Nd:YAG laser hyperthermia. *Lasers Surg Med*. 1992;12:159-164.
31. National Cancer Institute Conference Participants. The uniform approach to breast fine-needle aspiration biopsy. *Am J Surg*. 1997;174:371-385.
32. Nystrom L, Rutqvist LE, Wall S, Lindgren A, et al. Breast cancer screening with mammography: overview of Swedish randomised trials. *Lancet*. 1993;341:973-978.
33. National Institutes of Health Consensus Development Panel. National Institute of Health consensus development conference statement: breast cancer screening for women ages 40-49. *J Natl Cancer Inst*. 1997;89:1015-1026.
34. Hall FM, Storella JM, Silverstone DX, et al. Nonpalpable breast lesions: recommendations for biopsy based on suspicion of carcinoma at mammography. *Radiology*. 1988;167:353-358.
35. Morrow M, Foster RS Jr. Staging of breast cancer: a new rationale for internal mammary node biopsy. *Arch Surg*. 1981;116:748-751.
36. Veronesi V, Valagussa P. Inefficacy of internal mammary nodes dissection in breast cancer. *Cancer*. 1981;47:170-175.
37. Cuzick J, Stewart H, Rutqvist L, et al. Cause-specific mortality in long-term survivors of breast cancer who participated in trials of radiotherapy. *J Clin Oncol*. 1994;12:447-453.
38. Rutqvist L, Lax I, Fornander T, et al. Cardiovascular mortality in a randomized trial of adjuvant radiation therapy versus surgery alone in primary breast cancer. *Int J Radiat Oncol Biol Phys*. 1992;22:887-896.
39. Harris J, Hellman S. Put the "hockey stick" on ice. *Int J Radiat Oncol Biol Phys*. 1988;15:497-499.
40. Orr R. The impact of prophylactic axillary node dissection on breast cancer survival: a bayesian meta-analysis. Presented at: Cancer Symposium, SSO 51st Annual Symposium, March 27, 1998, San Diego, Calif.
41. Giuliano AE, Jones RC, Brennan M, et al. Sentinel lymphadenectomy in breast cancer. *J Clin Oncol*. 1997;15:2345-2350.
42. Veronesi U, Paganelli G, Galimberti V, et al. Sentinel node biopsy to avoid dissection in breast cancer with clinically negative lymph-nodes. *Lancet*. 1997;349:1864-1867.
43. Krag DN, Weaver D, Ashikaga T, et al. The sentinel node in breast cancer: a multicenter validation study. *N Engl J Med*. In press.
44. Albertini JJ, Lyman GF, Cox C, et al. Lymphatic mapping and sentinel node biopsy in the patient with breast cancer. *JAMA*. 1996;276:1818-1822.