

Effective Prevention of Adhesions With Hyaluronate

Klaus Kramer, MD; Norbert Senninger, MD, FACS; Hermann Herbst, MD, MRCPATH; Wolfgang Probst, MD

Hypothesis: Hyaluronate sodium in the form of a bioresorbant membrane reduces the development of intra-abdominal adhesions frequently found after implantation of synthetic mesh in the context of surgical hernia repair.

Design: The effect of hyaluronate on the formation of adhesions was evaluated when applied laparoscopically as a bioresorbant membrane to protect the peritoneal surface of a synthetic mesh.

Setting: Experimental animal model.

Interventions: A peritoneal defect 5 cm in diameter was bilaterally created in the abdominal wall of each of 9 pigs by laparoscopy. A polypropylene mesh was fixed with clips onto these defects on both sides. In each of the animals, only on one side, the synthetic mesh was also covered by a hyaluronate membrane.

Main Outcome Measures: The incidence and severity of adhesions (grade 0-4, where 0 indicates no adhe-

sion; 1, filmy avascular adhesions; 2, vascular adhesions; 3, cordlike fibrous adhesions; and 4, plain fibrous adhesions) were determined after 45 days, comparing treated and untreated sides by autopsy results and histological features.

Results: Adhesions, mainly grades 3 and 4, occurred in 7 of the 9 animals in those meshes not covered by hyaluronate; 2 untreated animals did not develop adhesions. On the other hand, only 1 of the 9 animals developed adhesions (grade 2) at the mesh concealed by the hyaluronate membrane.

Conclusions: The bioresorbant hyaluronate membrane significantly reduced the formation of peritoneal adhesions (1-sided sign test, $P < .05$) induced by the insertion of a polypropylene mesh, when compared with the contralateral implants not protected by hyaluronate. Thus, hyaluronate membranes are efficient for reducing the incidence of peritoneal adhesions.

Arch Surg. 2002;137:278-282

PERITONEAL ADHESIONS after abdominal surgery are the principal cause of intestinal obstruction in the Western world.¹⁻³ Furthermore, adhesions are a frequent cause of infertility and pelvic pain in women.⁴ In association with synthetic implants, which are increasingly used in the field of hernia surgery, adhesions occur especially frequently if such implants come into contact with serosal surfaces.⁵⁻⁸ Healing of peritoneal defects is a process with high adhesiogenic potential.⁹ The determiner for the outcome of mesothelial injury—the development of an adhesion or *restitutio ad integrum*—is the balance between fibrin deposition and fibrinolysis during the early phase of peritoneal wound healing, ie, before the formation of mature connective tissue takes place. Fibrinolytic agents reduce the development of adhesions, whereas inhibitors of fibrinolysis accelerate their formation.¹⁰

Even with an optimal surgical technique intending to minimize mesothelial injury, peritoneal trauma is inevitable. In consequence, the use of adhesion-preventing adjuvants is desirable.¹¹ Adhesion-preventing substances are characterized by the following¹¹: adhesiogenesis inhibition without restraint of wound healing, efficacy even in the presence of blood or other body fluids, anti-inflammatory properties, the absence of immunogenic determinants, biodegradability, the safety of remaining in place after application, easy handling, and an immediate effect.

Hyaluronate sodium meets all of these criteria, except for its complicated handling. It is a linear polymer of the disaccharide *N*-acetylglucosamino glucuronic acid that may assemble to long chains with a molecular weight of up to 10⁶ kd.¹² Hyaluronate is ubiquitously distributed in all body tissues.¹³ It is among nature's most hygroscopic substances. With its physical and chemical charac-

From the Department of Surgery (Drs Kramer and Senninger) and the Gerhard-Domagk Institute of Pathology (Dr Herbst), University of Muenster, Muenster, Germany; and the Department of Surgery, Ammerland Hospital, Westerstede, Germany (Dr Probst).

SUBJECTS AND METHODS

ANIMALS

Pigs with an average body weight of 24 kg were purchased out of herds from Oberheldrungen and Bachra, Thüringen, Germany. The experiments were performed at the Institute of Innovative Medicine, Beichlingen, Thüringen. The body weight of the animals was 60 to 65 kg at final examination. All animal experiments were conducted in accordance with state laws determining the use of experimental animals.

MEDICATIONS

Premedication included azaperone, 1 to 2 mg/kg of body weight; and atropine, 0.05 mg/kg of body weight (both were given intramuscularly). Sedation for intubation was achieved with 4% thiamylal sodium (Surital), approximately 10 mL/25 kg (dose according to effect). Muscle relaxation was achieved with succinylcholine and postoperatively with pancuronium bromide (Organon), 0.1 mg/kg of body weight. Inhalation narcosis was achieved with an oxygen and halothane mixture. The analgesic used was fentanyl citrate, 0.005 mg/kg of body weight, given intravenously; droperidol, 0.2 mg/kg of body weight; and ketamine hydrochloride or diazepam. The postoperative analgesic used was aspirin or dipyron, given orally and parenterally.

MATERIALS

We used the autosuture mesh (Surgipro Mesh) with a diameter of 5 cm. The mesh was fixed laparoscopically with clips onto the previously incised circular peritoneal defect.

To cover the polypropylene mesh, a hyaluronate-CMC membrane (Septrafilm II; Genzyme Corp), 12.7 × 15.2 cm, was applied unilaterally.

PROCEDURE

A peritoneal defect, 5 cm in diameter, was created laparoscopically on each side of the abdominal wall of 9 pigs. A polypropylene mesh was fixed with clips onto this defect. Only on one side, the synthetic mesh was also covered by a hyaluronate membrane. Each pig provided its own control by comparing both sides. After 45 days, the development of adhesions on both sides in all the pigs was compared and pictorially documented for occurrence, relationship to the intra-abdominal organs, and strength of the adhesions.

The severity of the adhesions was scored according to Burns et al,²⁰ Diamond,²¹ and Hoshiai et al²²: grade 0 indicates no adhesion; 1, filmy avascular adhesions; 2, vascular adhesions; 3, cordlike fibrous adhesions; and 4, plain fibrous adhesions.

Tissue specimens were fixed with formaldehyde solution and routinely embedded in paraffin wax. Tissue sections were stained with hematoxylin-eosin.

To determine the level of statistical significance, the 1-sided sign test was used. Differences were considered statistically significant at $P < .05$.

teristics, it determines the viscosity of the extracellular matrix.¹⁴

Septrafilm (Genzyme Corp, Cambridge, Mass) is a bioresorbable membrane made of hyaluronate sodium and carboxymethylated cellulose (CMC). It is transformed within 1 day into a gel and offers a complete covering of a tissue surface for a minimum of 7 days, with slow decline in the following 28 days due to resorption. Hyaluronate-CMC is neither toxic nor immunogenic and, thus, displays an optimal biocompatibility.^{15,16} It does not require suturing for fixation and is efficaciously applied even in the presence of blood. Thus, the incidence, and the extent and severity, of adhesions in a rat model¹⁵⁻¹⁷ and in humans^{18,19} was reduced. In both cases, different subjects were used as controls for the treated groups. To our knowledge, the adhesion-preventing effect has not been demonstrated by using the same subject as the experimental control. Also, to our knowledge, studies in larger animals, especially the domestic pig—which is known to be fibrophilic and to have similar physiological characteristics of wound healing as observed in humans—have not yet been performed.

This study examines the effect of hyaluronate on the formation of adhesions when used as a bioresorbant membrane in an intra-abdominal application.

RESULTS

We compared the incidence, severity, extent, and area of the adhesions of both sides of the abdominal wall after 45 days. Adhesions were noted in 7 of the 9 pigs over those meshes not covered by hyaluronate (**Figure 1** and **Table**). Adhesions were absent from the remaining 2 untreated sides of the animals. Over those meshes protected by hyaluronate membranes, an adhesion was noted in only 1 pig; 8 of the 9 treated sides of the pigs displayed no adhesions at all (**Table**). Therefore, significantly more adhesions were found on the untreated sides vs those sides treated with hyaluronate ($P < .05$, 1-sided sign test).

Adhesions observed on the side without a hyaluronate application were mainly grade 3 to 4 adhesions. On the side on which the hyaluronate-CMC membrane was applied, the only adhesion observed was a minor one (grade 2) between the polypropylene mesh and the greater omentum.

Histologically, a foreign body reaction with the formation of multinucleated foreign body giant cells (**Figure 2**) was observed along the polypropylene meshes. Inhomogeneity of the pattern of incorporation occurred on both sides (with or without hyaluronate). All meshes—no matter which side—were peritonealized completely. There were no differences between both investigated groups in the thickness of soft tissue between the neoperitoneum and mesh or in the degree of lymphocytic infiltration.

COMMENT

To induce an adhesiogenic stimulus in 9 pigs, laparoscopic excision of a peritoneal area was performed and subsequently a polypropylene mesh was fixed onto it with clips on both sides. In addition, only on one side, the mesh was

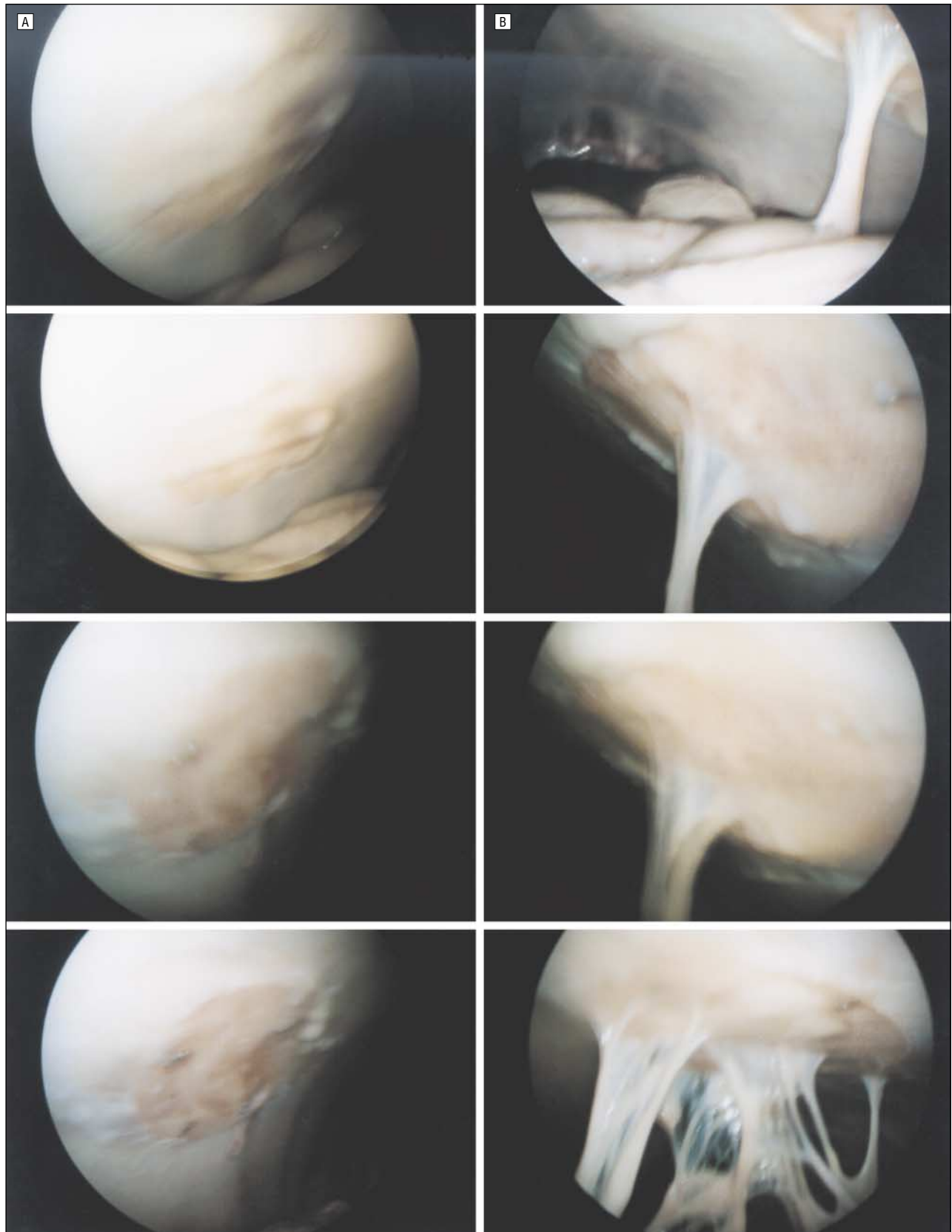


Figure 1. Intraoperative laparoscopic aspect. A, Treated with hyaluronate sodium. B, Not treated with hyaluronate.

covered with a hyaluronate-CMC membrane, also laparoscopically, to assess its adhesion-preventing effect. After an interval of 45 days, the incidence and severity of ad-

hesions were analyzed by comparing the 2 sides (with or without hyaluronate). We registered a significant reduction of the incidence of adhesions on the side with a hy-

Occurrence of Adhesions in 9 Pigs Treated With and Without Hyaluronate*

Variable	Pig No.								
	1	2	3	4	5	6	7	8	9
Treated with hyaluronate sodium									
Yes	0	0	0	0	0	0	0	0	2
No	3	4	4	3	4	2	4	0	0
Organ affected	SI	SI	SI and Om	SI	SI and C	SI	Om and S	...	Om

*Data are given as the incidence and severity of adhesions (grade 0 indicates no adhesion; 1, filmy avascular adhesion; 2, vascular adhesion; 3, cordlike fibrous adhesion; and 4, plain fibrous adhesion) unless otherwise indicated. SI indicates small intestine; Om, omentum; C, colon; S, spleen; and ellipses, data not applicable.

aluronate application compared with the untreated side (1 vs 7 adhesions; $P < .05$); also, the adhesions that developed on the side without treatment were much more severe (mainly grades 3-4) than those on the treated side (grade 2) (Table).

Thus, the adhesiogenesis-inhibiting efficacy is significant for the incidence of adhesions; the decreased severity of adhesions seen seems convincing but was not statistically significant. Absolute prevention of an adhesion could not be described using the presented manner of application and concentration. To what extent the effect occurs, only locally or in general, and whether an absolute impediment of adhesion can be achieved by increasing the concentration of hyaluronate will have to be demonstrated by further investigations.

We believe our results represent the first evidence of an intraindividual comparison of the adhesiogenesis-inhibiting effect within one animal, avoiding the bias of interindividual differences. Nevertheless, we may expect variations between different animals, which is shown by the fact that in one case an adhesion—albeit minor—appeared on the treated side in opposition to no adhesions on the untreated side.

Histopathologically, all implanted meshes appeared completely peritonealized and, thus, biologically integrated. The hyaluronate-treated meshes showed a tendency to reduced lymphocyte infiltration, although there were areas on the treated mesh that showed the opposite. The pattern of infiltration was not homogeneous enough to determine a level of significance. A definite clarification could only be achieved by serial sections in combination with laborious scoring of the degree of infiltration. Macroscopically, however, the presented results are convincing.

The presented results are consistent with the existing published literature in animal models¹⁶ and in humans.¹⁸ In rodents, the adhesion-preventing effect of hyaluronate was described in cecal abrasion, cecal adhesiolysis, and sidewall models.¹⁶ Similar significant adhesion-preventing effects have also been seen in humans undergoing surgical revision, like closure of the ileostomata 3 months after colectomy.¹⁸ In this context, no undesirable adverse effect has been observed. Moreover, our results were observed in a highly fibrophilic species (the pig).

The pathophysiological mechanism involved in the effect of hyaluronate on the inhibition of adhesiogenesis is not known yet. The key step in adhesiogenesis is the deposition of fibrin due to peritoneal trauma and the degree of its fibrinolysis. Hyaluronate itself shows plasmin

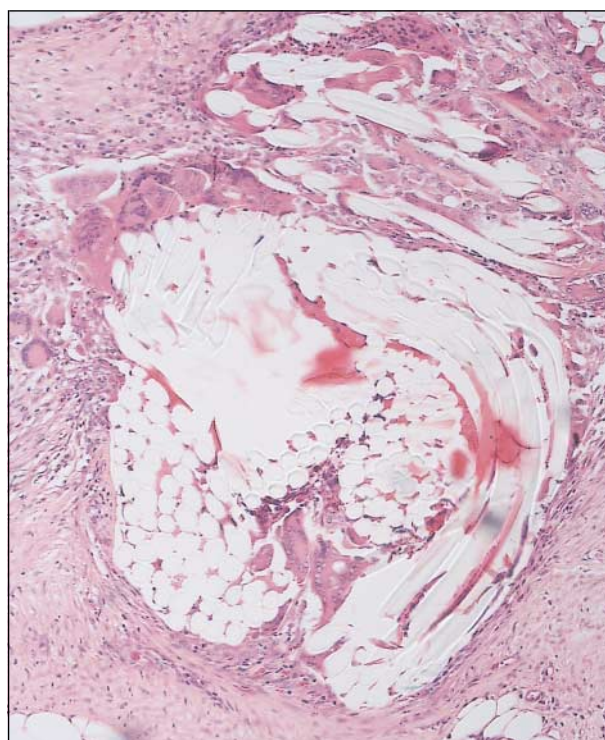


Figure 2. Paraffin section of a polypropylene mesh encased by fibrous tissue and infiltrated by moderate numbers of lymphocytes, plasma cells, and macrophages in addition to occasional multinucleated foreign body giant cells (hematoxylin-eosin, original magnification $\times 40$).

activation and, thus, a fibrinolytic effect.¹³ In addition to this, an indirect fibrinolytic effect also exists, caused, for example, by interleukin 1 and tumor necrosis factor α .¹³ The role and function of hyaluronate in wound healing is complex, however, and cannot be explained by one phenomenon alone. Further investigations of the role of inflammatory mediators and cytokines are needed to clarify the mechanism of action of hyaluronate.

For the role of hyaluronate in wound healing in general, it is known that it is traceable during the first aggregation of fibrin in wounds. In the following phase of inflammation, hyaluronate is promoting the activity of phagocytosis²³ through increased macrophage function and increased cytokine/mediator release.²⁴ In the proliferative phase, the level of hyaluronate in the extracellular matrix is maximal. Cell proliferation and angiogenesis are promoted. It is thought that metabolites of hyaluronate (polysaccharides) are responsible for promoting angiogenesis.²⁵ Hyaluronate increases cytokine release out of

macrophages, improving their migration.²⁶ In the remodeling phase, hyaluronate is necessary in the organization of collagen in the extracellular matrix. This again is necessary for a physiological cell/cell and cell/matrix interaction.²⁵ Hyaluronate inhibits matrix cells, which constitute soft tissue, and thus reduces collagen deposition. Similarly, scarless wound healing in the fetus is constituted by an effect of hyaluronate. By reduction of the hyaluronate concentration, the development of fibrous tissue is observed.²⁷ Hyaluronate is a free radical eliminator²⁸; it suppresses and regulates matrix-degrading enzymes, and it moderates inflammation.²⁹ In summary, hyaluronate is supposed to promote and moderate wound healing at the same time.^{13,30}

Although the presented experiments provide evidence for the adhesion-preventing effect of hyaluronate when applied on polypropylene meshes, our results do not allow us to extend these conclusions to the value of other resorbable materials. It may be of interest to study the adhesion-preventing effect of hyaluronate when applied as a coating of resorbable meshes, such as polyglactin 910 (Vicryl) or polyglycolic acid (Dexon). The presented model might also be suited for evaluation of the adhesiogenic potential of different synthetic meshes.

The annual cost impact for postsurgical adhesions in the United States in 1993 amounted to \$1.2 billion.³¹ This is sufficient justification for efforts to prevent the development of adhesions. The cost of one bioresorbant hyaluronate membrane (Seprafilm II), 12.7 × 15.2 cm, is about \$150. Among adhesion-preventing agents, only hyaluronate is significantly effective while neither impairing wound healing nor causing adverse effects. If the adhesion-reducing effect of hyaluronate is clinically confirmed, the cost impact compared with surgical revision due to postsurgical peritoneal adhesions should be a favorable one.

Thus, in the presented animal model, the application of a hyaluronate-CMC membrane reduced the incidence of adhesions significantly and limited their severity. These observations are supported by initial clinical experience with hyaluronate in patients. Additional animal studies may answer certain further questions, but they need to be specifically focused to justify killing further animals. We advocate gaining further well-documented clinical experience with the application of hyaluronate in patients with a history of adhesions. We suggest that, for hernia surgery, the hyaluronate-CMC membrane be applied whenever complete peritoneal covering of a prosthetic mesh will not be possible.

This study was presented in preliminary form as a poster at the 35th Congress of the European Society of Surgical Research, Malmö, Sweden, January 3, 2000, and at the 118th Congress of the German Society of Surgery, Munich, Germany, May 5, 2001.

We thank Frank Pölzing, MD, for his help with the pig experiments; Rudolf-Josef Fischer, MD, for his help with the statistical evaluations; Dietlind Elsner, MD, for her editorial assistance; and Klaus Kuben for the industrial grant for the autostature.

Corresponding author and reprints: Wolfgang Probst, MD, Department of Surgery, Ammerland Hospital, 26655 Westerstede, Germany (e-mail: probst@ammerland-klinik.de).

1. Ellis H. Prevention and treatment of adhesions. *Infect Surg*. November 1983; 803-807.
2. Menzies D. Postoperative adhesions: their treatment and relevance in clinical practice. *Ann R Coll Surg Engl*. 1993;75:147-153.
3. Menzies D. Peritoneal adhesions: incidence, cause, and prevention. *Ann Surg*. 1992;24(pt 1):29-45.
4. Di Zerega GS. The peritoneum: postsurgical repair and adhesion formation. In: Rock JA, Murphy AA, Jones HW, eds. *Female Reproductive Surgery*. Baltimore, Md: Williams & Wilkins; 1992:2-18.
5. Luijendijk RW, deLange DCD, Wauters CCAP, Hop van Geldop HJ, Jekel J. Foreign material in postoperative adhesions. *Ann Surg*. 1996;223:242-248.
6. Voeller GR, Ramshaw B, Park AE, Heniford BT. Incisional hernia. *J Am Coll Surg*. 1999;189:635-637.
7. Farmer L, Ayoub M, Warejcka D, Southerland S, Freeman A, Solis M. Adhesion formation after intraperitoneal and extraperitoneal implantation of polypropylene mesh. *Am Surg*. 1998;64:144-146.
8. Baptista ML, Bonsack ME, Felemovicus I, Delaney JP. Abdominal adhesion to prosthetic mesh evaluated by laparoscopy and electron microscopy. *J Am Coll Surg*. 2000;190:271-280.
9. Di Zerega GS. Biochemical events in peritoneal tissue repair. *Eur J Surg*. 1997;(suppl 577):10-16.
10. Holmdahl L, Ivarsson ML. The role of cytokines, coagulation and fibrinolysis in peritoneal tissue repair. *Eur J Surg*. 1999;165:1012-1019.
11. Risberg B. Adhesions: preventive strategies. *Eur J Surg*. 1997;(suppl 577):32-39.
12. Laurent TC, Fraser JR. Hyaluronan. *FASEB J*. 1992;6:2397-2404.
13. Chen WYJ, Abatangelo G. Functions of hyaluronan in wound repair. *Wound Repair Regen*. 1999;7:79-89.
14. Fraser JRE, Laurent TC. New applications for hyaluronan. In: Comper WD, ed. *Extracellular Matrix, Volume II: Molecular Components and Interactions*. Amsterdam, the Netherlands: Harwood Academic Publishers; 1996:141-199.
15. Medina M, Paddock HN, Connolly RJ, et al. Novel antiadhesion barrier does not prevent anastomotic healing in a rabbit model. *J Invest Surg*. 1995;8:179-186.
16. Burns JW, Colt MJ, Burgess LS, Skinner KC. Preclinical evaluation of Seprafilm bioresorbable membrane. *Eur J Surg*. 1997;suppl 577:40-48.
17. Burns JW, Skinner K, Colt J, et al. Prevention of tissue injury and postsurgical adhesion by precoating tissues with hyaluronic acid solutions. *J Surg Res*. 1995; 59:644-652.
18. Beck DE. The role of Seprafilm bioresorbable membrane in adhesion prevention. *Eur J Surg*. 1997;suppl 577:49-55.
19. Becker JM, Beck DE, Dayton MT, et al. Prevention of postoperative abdominal adhesions by a sodium hyaluronate-based bioresorbable membrane: a prospective, randomized, double-blind multicenter study. *J Am Coll Surg*. 1996;183:297-306.
20. Burns JW, Skinner K, Colt J, et al. Prevention of tissue injury and postsurgical adhesions by precoating tissue with hyaluronic acid solutions. *J Surg Res*. 1995; 59:644-652.
21. Diamond MP, for the Sepracoat Adhesion Study Group. Reduction of de novo postsurgical adhesions by intraoperative precoating with Sepracoat™ (HAL-C) solution: a prospective, randomized, blinded, placebo-controlled multicenter study. *Fertil Steril*. 1998;69:1067-1074.
22. Hoshiai H, Masaoka N, Satou K, et al. A clinical study of Seprafilm™ absorbable membrane to reduce postoperative adhesions in gynecologic surgery. *Obstet Gynecol*. 1998;111:803-812.
23. Tool BP. Development role of hyaluronate. *Connect Tissue Res*. 1982;10:93-100.
24. Hiro D, Ito A, Matsuta K, Mori Y. Hyaluronic acid is an endogenous inducer of interleukin-1 production by human monocytes and rabbit macrophages. *Biochem Biophys Res Commun*. 1986;140:715-722.
25. West DC, Hampson IN, Arnold F, Kumar S. Angiogenesis induced by degradation products of hyaluronic acid. *Science*. 1985;228:1324-1326.
26. Siebensschuh I, Rösken F, Koschnik M, Menger MD, Mutschler W. Hyaluronsäure in der Wundbehandlung. *Z Wundbhdg*. 1998;3:6-8.
27. West DC, Shaw DM, Lorenz P, Adzick NS, Longaker MT. Fibrotic healing of adult and late gestation fetal wounds correlates with increased hyaluronidase activity and removal of hyaluronan. *Int J Biochem Cell Biol*. 1997;29:201-210.
28. Foschi D, Castoldi L, Radaelli E, et al. Hyaluronic acid prevents oxygen free-radical damage to granulation tissue: a study in rats. *Int J Tissue React*. 1990; 12:333-339.
29. Ialenti A, Di Rosa M. Hyaluronate acid modulates acute and chronic inflammation. *Agents Actions*. 1994;43:44-47.
30. Wigle PH, Frost SJ, McGary CT, LeBoeuf RD. The role of hyaluronic acid in inflammation and wound healing. *Int J Tissue React*. 1988;10:355-365.
31. Ellis H. The clinical significance of adhesions: focus on intestinal obstruction. *Eur J Surg*. 1997;suppl 577:5-9.