

Laparoscopically Treated Liver Hydatid Cysts

Metin Ertem, MD; Tayfun Karahasanoglu, MD; Nihat Yavuz, MD; Sabri Erguney, MD

Hypothesis: Laparoscopy is effective and reliable in treating hepatic hydatid disease.

Design: Case series of patients with hepatic hydatid disease who underwent laparoscopic treatment within 7 years.

Setting: Department of General Surgery, Cerrahpasa Medical School, University of Istanbul, Istanbul, Turkey.

Patients: Forty-eight patients with hydatid disease who met our criteria for laparoscopic surgery and were aged 17 years or older.

Interventions: Cystotomy and partial cystectomy with drainage were performed in 33 patients. Omentoplasty was simultaneously performed in 15 patients to obliterate the cystic cavity.

Main Outcome Measures: Clinicopathologic features, morbidity, mortality, operative time, length of hospital stay, conversion to laparotomy, and recurrences were reviewed retrospectively.

Results: The mean operative time was 82 minutes (range, 45-170 minutes). The conversion rate to open surgery was 4%. The mean postoperative length of hospital stay was 4.2 days. Morbidity was 6% (3 patients). There was no mortality. The mean follow-up was 34.2 months. No recurrences were observed during this period.

Conclusions: Laparoscopic hepatic hydatid surgery is a safe and effective method in selected patients. Further studies should be encouraged in this field because there is no universally accepted standard technique.

Arch Surg. 2002;137:1170-1173

IN THE LAST DECADE, laparoscopic treatment of hepatic hydatid disease has been increasingly popular and has undergone a revolution parallel to the progress in laparoscopic surgery. There are encouraging preliminary results; however, there have been limited reports concerning long-term results of this technique.

Preliminary results of 12 patients treated laparoscopically were published in 1998,¹ and results of 34 patients were published in 2000.² With increased use, the technique has been refined and standardized. This study presents our experience, new techniques, and long-term cumulative results in laparoscopic treatment of hepatic hydatid disease.

PATIENTS AND METHODS

From January 1, 1994, to February 28, 2001, 48 patients with hepatic hydatid disease were treated laparoscopically in the Department of General Surgery, Cerrahpasa Medical School, University of Istanbul, Istanbul, Turkey. One of them had undergone conventional surgery

4 years earlier. During the same period, 228 patients with hepatic hydatid disease underwent conventional surgery. The disease was diagnosed by ultrasonography (US) and computed tomography (CT) and confirmed by serological examination.

Our exclusion criteria for laparoscopic intervention included intraparenchymal location of the cyst, more than 3 cysts, or cysts with thick and calcified walls. There were 32 women and 16 men. The mean age was 40.6 years (range, 17-71 years). Although 46 patients had solitary cysts, 1 patient had 2 and another had 3 cysts. The mean cystic diameter was 8 cm (range, 2-18 cm). Eighteen cysts were localized in subsegment VI, 12 in subsegment V, 6 in subsegment VII, 6 in subsegment IV, 5 in subsegment III, and 4 in subsegment VIII.

All procedures were performed in the supine position under endotracheal anesthesia. Antibiotics were administered 30 minutes before the operation. A nasogastric tube was placed, and the urinary bladder was catheterized. Five trocars were placed according to cyst location (**Figure 1**). Following exposure of the cyst by a 30° telescope inserted through the umbilical trocar, an 11-mm trocar was inserted from a point as close as possible to the cyst. From this trocar, 3 gauzes were introduced into the

From the Department of General Surgery, Cerrahpasa Medical School, University of Istanbul, Istanbul, Turkey.

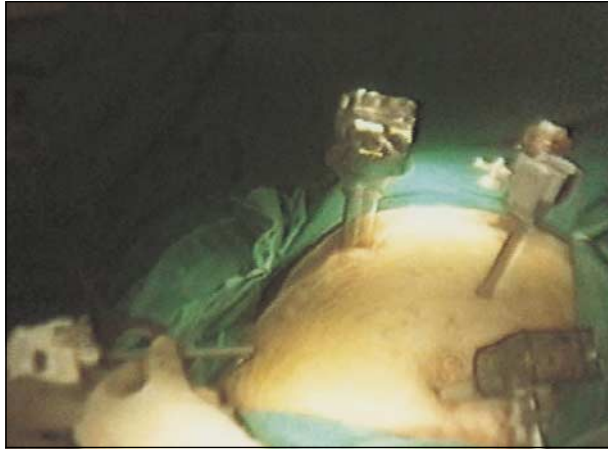

Figure 1. Trocar sites.

abdominal cavity, placed around the cyst, and soaked with 10% povidone iodine solution as a scolecidal agent. The cyst was punctured with a 14-gauge 6F aspiration needle. As a precaution, the tip of a 5-mm suction catheter was placed close to the puncture site (Figure 2), and as much cystic fluid as possible was aspirated, so that the endocyst (germinative membrane) detached from the cystic wall and shrank to the bottom of the cyst. The deflated cystic wall was suspended by 2 graspers, and cystotomy was performed. At this stage, the 11-mm trocar was exchanged for an 18-mm one. A transparent tube with a 15-mm internal diameter was inserted through the 18-mm trocar, and the germinative membrane was aspirated (Figure 3). A hose of the same diameter was connected to the transparent tube, and the entire membrane was removed. In all cases, the telescope was inserted into the cyst to explore for potential biliary openings and retained daughter cysts. The cystic cavity was irrigated with 20% hypertonic saline (another scolecidal agent) several times, and unroofing was performed by partial or near-total cystectomy. Omentoplasty was simultaneously performed in suitable cases. In the remaining patients, a drain was placed in the cystic cavity. Gauzes and pieces of the excised cystic wall were placed in an endosac and removed.

Oral liquid intake was started on the first postoperative day. After drain removal, if no bile leakage or major ascites drainage was present, the drain was removed and the patient was discharged. A 3-month course of albendazole (10 mg/kg per day) was administered postoperatively to all patients.

The patients were followed up by US every 3 months during the first year, then by US and CT every 6 months during the second year, and thereafter by US, CT, and serological examinations annually.

RESULTS

Laparoscopic cystotomy and partial cystectomy with drainage were performed in 33 patients, and laparoscopic cystotomy and partial cystectomy with omentoplasty were performed in 15 patients. In 2 patients (4%), laparoscopic procedures were converted to open surgery because of inadequate exposure and access. Other simultaneously performed surgical procedures were cholecystectomy in 4 patients, cholecystectomy and T-tube drainage in 1 patient, and inguinal hernia repair (transabdominal preperitoneal polypropylene meshplasty) in 1 patient. In 1 patient, the cystic fluid was noted to be bile stained, suggesting biliary rupture. We performed choledochotomy and T-tube drainage. On the tenth post-

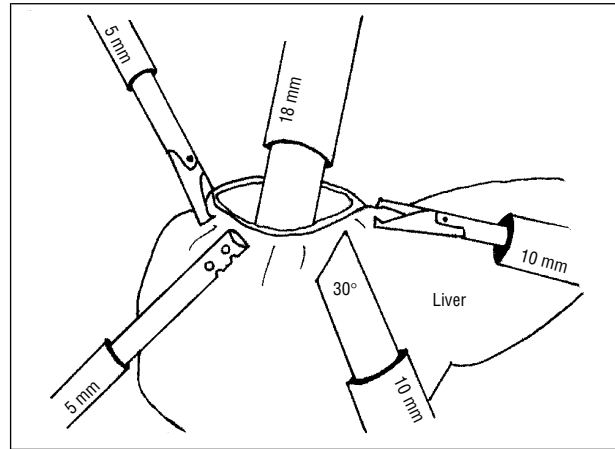


Figure 2. Schematic view of cyst evacuation.

operative day, the drain was removed under controlled T-tube cholangiographic examination.

The mean operative time was 82 minutes (range, 45-170 minutes). There was no mortality. Morbidity was 6.2% (3 patients). Port-side infection occurred in 1 patient. In another patient, bile leakage was observed on the second postoperative day, which was managed by endoscopic sphincterotomy. The leakage gradually ceased within 9 days. This patient was discharged on the twelfth postoperative day. In the third patient, an infected perihepatic hematoma developed after discharge from the hospital. This patient was rehospitalized with pain and high fever (temperature, 39°C), and the collection was drained percutaneously.

The mean length of hospital stay was 4.2 days (range, 3-13 days). The mean follow-up was 34.2 months (range, 4-78 months). Radiological and serological test results showed no recurrences. A recurrence was suspected in 1 patient based on US and CT images in the sixth postoperative month (Figure 4). Laparotomy was performed, and exploration revealed a cystic cavity filled with scolex-free sterile fluid, which was later confirmed microscopically.

COMMENT

Although treatment choices for hydatid disease of the liver have increased in the last 2 decades, including medical treatment, percutaneous drainage, or a combination, surgery remains the mainstay of therapy. Use of these other modalities is restricted to certain stages of the disease and is associated with inconsistent results.³⁻⁷

Total pericystectomy seems to be the best operative procedure for small and peripherally located cysts.⁸ It has been demonstrated that pericysts contain no scolices.³ For large and deeply located cysts, the more extensive cystectomy and hepatectomy are accompanied by higher morbidity.

We have used laparoscopic techniques in selected patients since 1994, applying the principles of conventional liver hydatid cyst surgery, including inactivation of scolices, prevention of spillage, elimination of viable elements of the cyst, and management of the residual cavity.

A major disadvantage of laparoscopy is the lack of precautionary measures concerning spillage, especially under high abdominal pressures induced by pneumo-

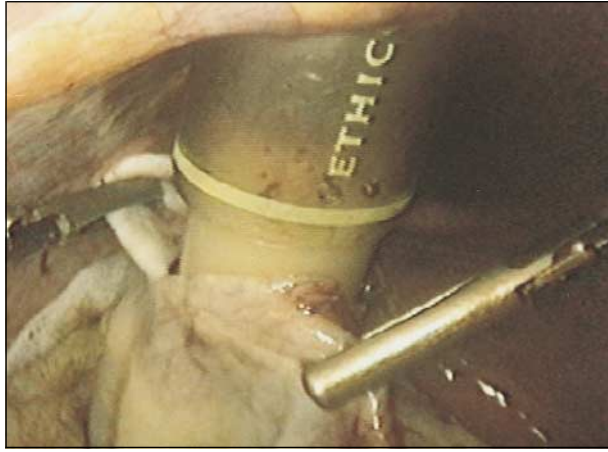


Figure 3. Aspiration of the germinative membrane.

peritoneum.⁹⁻¹² However, Bickel et al¹³ demonstrated that the increase in intracystic pressure was no greater than the increase in intraabdominal pressure and that the pneumoperitoneum was protective against spillage. We believe that decreasing the pressure of the pneumoperitoneum to avoid possible spillage is not beneficial and is perhaps harmful. The most dangerous step is the initial puncture and aspiration of the cystic fluid, but no less precaution is taken than in conventional surgery, with gauzes soaked with scolecidal agents surrounding the puncture site and the suction catheter on guard.

In the past, we considered cysts with diameters greater than 15 cm and recurrent hydatid disease as exclusion criteria but, with increased experience, no longer do so.^{1,2} The content of cysts with calcified walls is unlikely to be fertile, and these should be followed up.³

We converted to laparotomy in 2 patients because of unsafe exposure and unsatisfactory access. In both cases, the cysts were located in subsegment VII. We used the supine position in all cases. One report describes the placement of a patient in a lateral position to gain access to a simple cyst of the liver located posterolaterally within segment VII.¹⁴ We do not consider the lateral position safe for laparoscopic access to hydatid cysts of the liver.

Some authors do not recommend the use of scolecidal agents because of possible sclerosing cholangitis.¹⁵ We believe these are necessary because simple irrigation with isotonic sodium chloride does not ensure the inactivation or clearance of scolices.

Intrabiliary rupture of the cyst is the most common complication of the disease, seen in 5% to 25% of patients.¹⁶ In these patients, the ideal technique is choledochotomy, irrigation, and T-tube drainage. However, this procedure prolongs the hospitalization. We found bilious cystic content in 1 patient that had not been recognized preoperatively. We used intraoperative cholangiography to confirm this and performed choledochotomy and T-tube drainage laparoscopically.

Endoscopic sphincterotomy is the first line of treatment for postoperative external biliary fistulas related to treatment of hepatic hydatid disease.¹⁷ In 1 patient, we encountered a biliary leakage through the drain on the second postoperative day, which resolved in 10 days following endoscopic sphincterotomy.

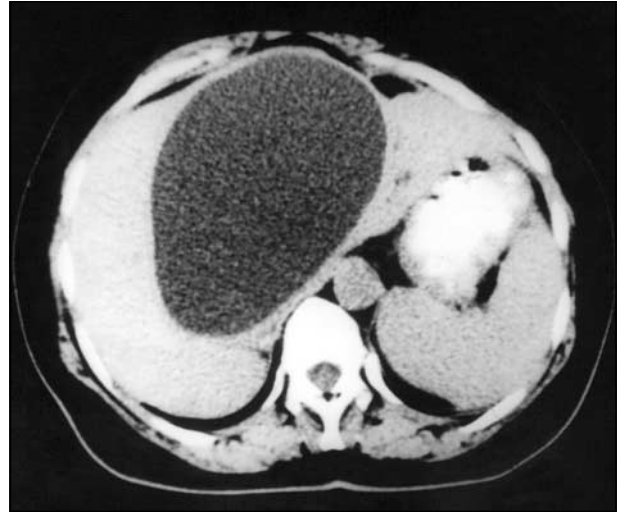

Figure 4. Preoperative computed tomographic image.

Another important issue in laparoscopic hydatid cyst surgery is the removal of the germinative membrane. For this procedure, several techniques and instruments have been described. Alper et al¹⁸ use an aspirator-grinder apparatus, and Bickel and Eitan¹⁹ recommend the use of a large-bore suction catheter. We use a wide-bore suction catheter without a valvular system, which avoids the narrowing caused by valvular systems.

Marvik et al²⁰ use US in laparoscopic cyst unroofing. We concur that intraoperative US can be useful in detecting the cyst and assessing the structure of the liver.

Because of suspected recurrence, based on US and CT findings, laparotomy was performed in one of our patients (Figure 4). A similar radiological misinterpretation has been reported,^{21,22} underscoring caution in making premature misdiagnoses. Recurrence should be confirmed by seropositivity and by an observed increase in the size of the cyst during follow-up. It is advisable to wait until the characteristic signs appear before surgical exploration.

The recurrence rate ranges from 3% to 10% following open surgery for hepatic hydatid cysts.^{23,24} In our laparoscopic series and follow-up, we have not seen any recurrences.

In conclusion, laparoscopic treatment of liver hydatid cyst disease is safe and effective in selected patients and offers all the advantages of laparoscopic surgery. Further studies should be encouraged in this field to determine a universally accepted standard technique.

Corresponding author: Metin Ertem, MD, Department of General Surgery, Cerrahpasa Medical School, University of Istanbul, Istasyon Cad Kemal Kayacan sok 16/3, Goztepe/Istanbul, Turkey (e-mail: mertem@istanbul.edu.tr).

REFERENCES

1. Ertem M, Uras C, Karahasanoglu T, Erguney S, Alemdaroglu K. Laparoscopic approach to hepatic hydatid disease. *Dig Surg*. 1998;15:333-336.
2. Ertem M. Our experience with laparoscopic treatment of liver hydatid cyst. *Arch Balkan Med Union*. 2000;35:115-120.
3. Goksoy E, Duren M. Operative therapies of *Echinococcus granulosus* (cystic). *Chirurgia (Bucur)*. 2000;71:21-29.

4. Aktan AO, Yalin R. Preoperative albendazole treatment for liver hydatid disease decreases the viability of the cyst. *Eur J Gastroenterol Hepatol.* 1996;8:877-879.
5. Aktan O, Ozmen MN, Dincer A, Sayek I, Gocmen A. Liver hydatid disease: long-term results of percutaneous treatment. *Radiology.* 1996;198:259-264.
6. Bastrol C, Azar C, Doyer M, Sahal P. Percutaneous treatment of hydatid cysts under sonographic guidance. *Dig Dis Sci.* 1989;7:1576-1580.
7. Adrien GS. Medical treatment of liver hydatidosis. *World J Surg.* 2001;25:15-20.
8. Guibert L, Gayral F. Laparoscopic pericystectomy of a liver hydatid cyst. *Surg Endosc.* 1995;9:442-443.
9. Terblanche J, Krige JEJ. Hepatic echinococcosis. In: Cameron JL, ed. *Current Surgical Therapy.* 6th ed. London, England: Mosby Inc; 1998:326-330.
10. Klingler PJ, Gadenstatter M, Schmid T, Bodner E, Schwelberger HG. Treatment of hepatic cysts in the era of laparoscopic surgery. *Br J Surg.* 1997;84:438-444.
11. Iskender S. Diagnosis and treatment of uncomplicated hydatid cyst of the liver. *World J Surg.* 2001;25:21-27.
12. Berberoglu M, Taner S, Dilek ON, Demir A, Sari S. Gasless vs gaseous laparoscopy in the treatment of hepatic hydatid disease. *Surg Endosc.* 1999;13:1195-1198.
13. Bickel A, Daud G, Urbach D, Lefler E, Barasch EF, Eitan A. Laparoscopic approach to hydatid liver cysts: is it logical? physical, experimental and practical aspects. *Surg Endosc.* 1998;12:1073-1077.
14. Watson DI, Jamieson GG. Laparoscopic fenestration of giant posterolateral liver cyst. *J Laparoendosc Surg.* 1995;5:255-257.
15. Senyuz OF, Celayir AC, Kilic N, et al. Hydatid disease of the liver in childhood. *Pediatr Surg.* 1999;15:217-220.
16. Alper A, Ariogul O, Emre A, Uras A, Okten A. Choledochoduodenostomy for intrabiliary rupture of hydatid cysts of liver. *Br J Surg.* 1987;74:243-245.
17. Tekant Y, Bilge K, Acarli K, Alper A, Emre A, Ariogul O. Endoscopic sphincterotomy in the treatment of postoperative biliary fistulas of hepatic hydatid disease. *Surg Endosc.* 1996;10:909-911.
18. Alper A, Emre A, Acarli K, Bilge O, Ozden I, Ariogul O. Laparoscopic treatment of hepatic hydatid disease. *J Laparoendosc Surg.* 1996;6:29-33.
19. Bickel A, Eitan A. The use of a large, transparent cannula, with a beveled tip, for safe laparoscopic management of hydatid cysts of liver. *Surg Endosc.* 1995;9:1304-1305.
20. Marvic R, Myrvold HE, Johnsen G, Roysland P. Laparoscopic ultrasonography and treatment of hepatic cysts. *Surg Laparosc Endosc.* 1993;3:172-174.
21. Yalin R, Ozdemir A, Acikozoglu S. Computed tomography and sonography of hydatid cysts of the liver after surgical management. *J Med Imaging.* 1989;3:301-305.
22. Adam A, Roddie ME. Computed tomography of the liver and biliary tract. In: Blumgart LH, ed. *Surgery of the Liver and Biliary Tract.* Edinburgh, Scotland: Churchill Livingstone; 1994:243-267.
23. Demirci S, Eraslan S, Anado E, Bozatl L. Comparison of the results of different surgical techniques in the management of hydatid cysts of the liver. *World J Surg.* 1989;13:88-91.
24. Turkcapar AG, Ersoz S, Gungor C, Aydinuraz K, Yerdel MA, Aras N. Surgical treatment of hepatic hydatidosis combined with preoperative treatment with albendazole. *Eur J Surg.* 1997;163:923-928.

Surgical Anatomy

Pectus excavatum is a congenital malformation caused by a deformity of the costal cartilages (fifth through eighth), which develop abnormally in a concave manner, pushing the sternum posteriorly. This chest deformity is most severe at the xiphoid.

Source: Blackbourne LH, Fleischer KJ, eds. *Advanced Surgical Recall.* Baltimore, Md: Williams & Wilkins; 1997:846.