

# Total Laparoscopic Pancreaticoduodenectomy

## Feasibility and Outcome in an Early Experience

Michael L. Kendrick, MD; Daniel Cusati, MD

**Hypothesis:** Total laparoscopic pancreaticoduodenectomy is a safe and effective therapeutic approach.

**Design:** Single-institutional retrospective review.

**Setting:** Tertiary referral center.

**Patients:** All consecutive patients undergoing total laparoscopic pancreaticoduodenectomy from July 2007 through July 2009 at a single center (n=62).

**Main Outcome Measures:** Blood loss, operative time, postoperative morbidity, length of hospital stay, and 30-day or in-hospital mortality.

**Results:** Of 65 patients undergoing laparoscopic resection, 62 patients with a mean age of 66 years (SD, 12 years) underwent total laparoscopic pancreaticoduodenectomy. The pancreaticojejunostomy consisted of a duct-to-mucosa anastomosis with interrupted suture. Median operative time was 368 minutes (range, 258-608 minutes) and median blood loss was 240 mL (range, 30-1200 mL). Diagnosis was pancreatic adenocarcinoma

(n=31), intraductal papillary mucinous neoplasm (n=12), periampullary adenocarcinoma (n=8), neuroendocrine tumor (n=4), chronic pancreatitis (n=3), cholangiocarcinoma (n=1), metastatic renal cell carcinoma (n=1), cystadenoma (n=1), and duodenal adenoma (n=1). Median tumor size was 3 cm (range, 0.9-10.0 cm) and the median number of lymph nodes harvested was 15 (range, 6-31). Perioperative morbidity occurred in 26 patients and included pancreatic fistula (n=11), delayed gastric emptying (n=9), bleeding (n=5), and deep vein thrombosis (n=2). There was 1 postoperative mortality. Median length of hospital stay was 7 days (range, 4-69 days).

**Conclusions:** Laparoscopic pancreaticoduodenectomy is feasible, safe, and effective. Outcomes appear comparable with those via the open approach; however, controlled trials are needed. Despite this series representing experience within the learning curve, laparoscopic pancreaticoduodenectomy holds promise for providing advantages seen with minimally invasive approaches in other procedures.

*Arch Surg.* 2010;145(1):19-23

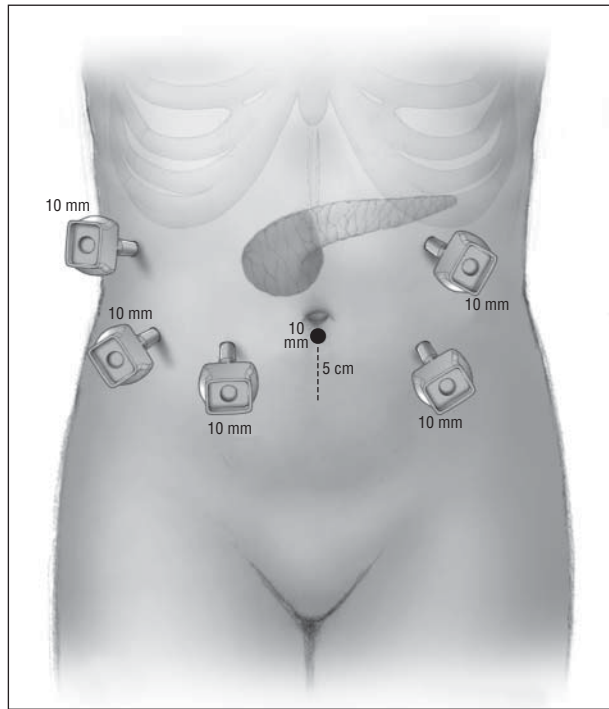
LAPAROSCOPIC PANCREATICO-  
duodenectomy represents one of the most advanced abdominal operations owing to the necessity of a complex dissection and reconstruction. Despite its first description by Gagner and Pomp<sup>1</sup> in 1994, there has not been wide acceptance of the procedure to date. Pessimism has stemmed from long operative times, lack of apparent advantages, and the requirement of advanced laparoscopic skills. The current literature contains several case reports and small series of laparoscopic pancreaticoduodenectomy. However, in many of these articles, very few patients actually underwent a totally laparoscopic procedure.<sup>2-4</sup> Rather, many choose to perform laparoscopic resection with subsequent open reconstruction. These hybrid approaches and the lack of sufficient

patient numbers preclude any meaningful assessment of the maximal advantages of minimally invasive techniques or the feasibility and outcomes of a total laparoscopic approach to resection and reconstruction. Our aim was to describe the feasibility and outcome of total laparoscopic pancreaticoduodenectomy (TLPD) at a single institution.

## METHODS

A review of prospectively collected data was performed for all patients undergoing TLPD from July 2007 through July 2009. Demographic data, preoperative evaluation, operative procedure, pathology, perioperative data, and clinical follow-up were reviewed. All patients underwent a full clinical evaluation to assess overall health and medical comorbidities. Helical computed tomography was per-

**Author Affiliations:** Division of Gastroenterologic and General Surgery, Department of Surgery, Mayo Clinic College of Medicine, Rochester, Minnesota.



**Figure.** Trocar location for total laparoscopic pancreaticoduodenectomy. Reprinted with permission from the Mayo Clinic.

formed routinely and endoscopic ultrasound selectively to evaluate the primary lesion and exclude vascular invasion or distant metastases. Exclusion criteria for laparoscopic pancreaticoduodenectomy were having tumors adjacent to the portal vein or superior mesenteric vein on radiographic imaging for which venous resection may be necessary. During the study period, 34 additional patients underwent open pancreaticoduodenectomy performed by one of the authors (M.L.K.). These patients either met the exclusion criteria or chose not to undergo the laparoscopic approach. All results are presented as mean (standard deviation [SD]) or median (range).

### OPERATIVE PROCEDURE

The procedure is performed with the patient in the supine position. Typically, a total of 6 (12-mm) trocars are used for the procedure, placed in a semicircle in the lower and lateral aspects of the abdomen (**Figure**). When deemed necessary for adequate exposure, a seventh trocar (5 mm) is placed in the subxiphoid position for liver retraction. After establishing a pneumoperitoneum, a thorough diagnostic laparoscopy is performed inspecting all visible peritoneal and visceral surfaces. A 7.5-MHz laparoscopic ultrasound probe is used to perform ultrasonography of the liver and pancreas. Using ultrasonic shears, the gastrocolic ligament is divided and the lesser sac widely exposed. The hepatic flexure of the colon is mobilized inferiorly and a Kocher maneuver is performed. The portal vein is identified at the superior border of the pancreatic neck and the superior mesenteric vein at the inferior border. A tunnel is dissected posterior to the pancreatic neck, anterior to the superior mesenteric vein and portal vein. The gastroduodenal and right gastric arteries are ligated, clipped, and divided. The first portion of the duodenum is dissected and transected with a linear stapler 2 to 3 cm distal to the pylorus. The right gastroepiploic vessels are ligated and divided. The bile duct at the superior border of the pancreatic head is dissected, ligated distally, and divided. A cholecystectomy is performed. The fourth portion of the duodenum and proximal jejunum are mobilized and

the jejunum is transected 15 cm distal to the ligament of Treitz with the linear stapler. The jejunal stump is passed into the supramesocolic compartment. The pancreatic neck parenchyma is divided with electrocautery or (more recently) ultrasonic shears, and the pancreatic duct is divided sharply with scissors. Dissection of the pancreatic head and uncinate process off the portal vein, superior mesenteric vein, and superior mesenteric artery is typically performed using Ligasure (Tyco Healthcare Group, Dublin, Ireland). Larger tributary vessels (pancreaticoduodenal vessels) are ligated or clipped. All peripancreatic lymphatic tissue is taken en bloc with the specimen. The specimen is then removed in an endosac via the infraumbilical trocar site extended 4 to 7 cm. The portal vein groove and retroperitoneal/uncinate margin are inked, and separate bile duct and pancreatic neck margins are obtained prior to sending the specimen for frozen section analysis. After fascial closure of the extraction site, the pneumoperitoneum is reestablished and intracorporeal reconstruction begun once margin status is confirmed on histology. The jejunum is brought through the duodenal resection bed, posterior to the superior mesenteric vessels into the supramesocolic compartment. An end-to-side, pancreaticojejunostomy, duct-to-mucosa anastomosis is performed over an 8-cm Silastic tube with an inner layer of 5-0 Vicryl sutures and an outer layer of interrupted 3-0 silk sutures. Approximately 10 cm distally, an end-to-side hepaticojejunostomy is performed with running (bile duct >5 mm) or interrupted (bile duct ≤5 mm) Vicryl sutures. The jejunum is secured, closing the defect at the ligament of Treitz. Approximately 40 cm distal to the biliary anastomosis, an antecolic, end-to-side duodenojejunostomy is performed with 2 layers of running 3-0 Vicryl. Operative drains are not routinely used. Trocars are removed and trocar sites are closed with an absorbable, monofilament, subcuticular suture.

### PERIOPERATIVE CARE

After anesthesia recovery, patients are admitted to a general surgical unit unless significant medical comorbidities or intraoperative hemodynamics warrant continuous monitoring overnight. On postoperative day 1, the nasogastric tube is removed and the patient is not given any food or water orally. A clear liquid diet is begun on postoperative day 2, and an oral diet is advanced as tolerated. Analgesia consists of scheduled intravenous ketorolac and supplemental intravenous morphine via a patient-controlled analgesia pump. Once the patient is tolerating oral intake, patient-controlled analgesia is discontinued and oral narcotic analgesics are given as needed. Perioperative prophylactic antibiotics (preincision and 2 postoperative doses) and subcutaneous unfractionated heparin (preincision and 3 times a day during hospitalization) are given. Patients are discharged after postoperative day 5 if tolerating oral intake and there are no signs or symptoms of complications.

### RESULTS

Of 65 patients who underwent laparoscopic pancreaticoduodenectomy, 3 patients underwent conversion to laparotomy. One patient underwent a planned conversion for the reconstruction phase after laparoscopic resection early in the experience; the other 2 patients were converted owing to unsuspected findings of tumor invasion into the superior mesenteric vein. These 3 patients were excluded from the analysis. The remaining 62 patients underwent TLPD and comprise the study population. Patients included 30 women and 32 men with a mean age of 66 years (SD, 12 years), median body mass

**Table 1. Patient Demographics and Operative Data**

Characteristic	Median (Range)
Patients, No.	62
Age, mean (SD), y	66 (12)
Body mass index <sup>a</sup>	26 (17-40)
American Society of Anesthesiologists score	3 (2-3)
Sex, female/male, No.	30/32
Disease status, No. (%)	
Benign	17 (27)
Malignant	45 (73)
Type of procedure, No (%)	
Pylorus-preserving	59 (95)
Robotic-assisted	8 (13)
Operative time, mm	368 (258-608)
Estimated blood loss, mL	240 (30-1200)
No. of lymph nodes retrieved	15 (6-31)

<sup>a</sup>Calculated as weight in kilograms divided by height in meters squared.

index (calculated as weight in kilograms divided by height in meters squared) of 26 (range, 17-40), and median American Society of Anesthesiologists score of three.<sup>2,3</sup> Indication for pancreaticoduodenectomy included benign (n=17 [27%]) and malignant (n=45 [73%]) diseases. Operative findings and perioperative data are summarized in **Table 1**. In all patients who underwent TLPD, the procedure was performed with curative intent; no patient had evidence of local unresectability, superior mesenteric vein vascular involvement, or metastatic disease. The pancreatic parenchymal texture was reported as soft (n=15), intermediate (n=24), or firm (n=20). Median pancreatic duct and bile duct diameters were 4 mm (range, 1.5-9 mm) and 9 mm (range, 4-17 mm), respectively. In 59 patients, a pylorus-preserving pancreaticoduodenectomy was performed; 3 patients had a standard Whipple resection. While all procedures were performed totally laparoscopically (intracorporeal resection and reconstruction), in 8 patients robotic assistance was used for laparoscopic reconstruction. Median operative time and blood loss were 368 minutes (range, 258-608 minutes) and 240 mL (range, 30-1200 mL), respectively. A Jackson-Pratt drain was left at the completion of the procedure near the pancreaticojejunostomy in 12 patients at the discretion of the surgeon.

Histologic diagnosis was confirmed in all patients and included pancreatic adenocarcinoma (n=31), intraductal papillary mucinous neoplasm (n=12), periampullary adenocarcinoma (n=8), neuroendocrine carcinoma (n=4), chronic pancreatitis (n=3), cholangiocarcinoma (n=1), metastatic renal cell carcinoma (n=1), cystadenoma (n=1), and duodenal adenoma (n=1). The median tumor size was 3 cm (range, 0.9-10 cm) and the median number of lymph nodes retrieved was 15 (range, 6-31). In 89% of patients, an R0 (margin-negative) resection was possible. Regional lymph node metastases were identified in 27 of 45 patients (60%) with malignancy. Pathology findings are summarized in **Table 2**.

Perioperative complications occurred in 26 (42%) patients and included pancreatic anastomotic leak (n=11 [18%]), delayed gastric emptying (n=9 [15%]), postoperative anemia (n=5 [8%]), superficial surgical site in-

**Table 2. Final Diagnosis and Histologic Findings**

Diagnosis	No. of Cases
Pancreatic ductal adenocarcinoma	31
Intraductal papillary mucinous neoplasm	12
Ampullary adenocarcinoma	8
Neuroendocrine carcinoma	4
Chronic pancreatitis	3
Cholangiocarcinoma	1
Metastatic renal cell carcinoma	1
Cystadenoma	1
Duodenal adenoma	1
Specimen characteristics	
Tumor size, median (range), cm	3 (0.9-10.0)
Margin-negative, R0, resection, No. (%)	40 (89) <sup>a</sup>
Regional lymph node metastases, No. (%)	27 (60) <sup>a</sup>

<sup>a</sup>Calculations include only patients with malignancy (n = 45).

fection (n=4 [6%]), deep venous thrombosis (n=2), atrial fibrillation (n=1), urinary retention (n=1), and pneumonia (n=1). Reoperation was necessary in 3 patients for control of sepsis after pancreatic anastomotic leak, control of hemorrhage after percutaneous drain placement, and revision of a biliary anastomotic leak. Six days postoperatively, another patient with a pancreatic leak developed intraperitoneal bleeding that required angiography with embolization of the superior pancreaticoduodenal artery arising from a replaced right hepatic artery; this patient also developed transient renal failure. Thirty-day or in-hospital mortality occurred in 1 patient. This 85-year-old patient developed persistent cardiopulmonary failure after control of sepsis from a pancreatic anastomotic leak; care was withdrawn and the patient died 61 days postoperatively. Overall median length of hospital stay was 7 days (range, 4-69 days). Follow-up was complete in all patients for a mean of 7.2 months. Of the 45 patients with malignancy, hepatic or pulmonary recurrence was identified in 7 (16%) within a mean of 7.4 months; 6 of these patients died of progressive malignancy a mean of 9 months<sup>3-14</sup> after resection. No port-site recurrences were identified in any patient during the observation period.

#### COMMENT

Minimally invasive approaches to pancreatic resection are of increasing interest. The typical advantages of decreased pain, reduced wound-related complications, shorter hospitalization, and quicker recovery that have been observed with several minimally invasive surgical abdominal procedures would also be beneficial in patients undergoing pancreatic resection. The most logical and feasible initial application of minimally invasive surgical approaches has been for distal pancreatectomy, for which there is limited dissection and reconstruction is not required. In the past several years, there has been an increasing acceptance of laparoscopic distal pancreatectomy, with evidence suggesting advantages of reduced blood loss, complication rate, and shorter hospi-

**Table 3. Series Comparison of Total Laparoscopic Pancreaticoduodenectomy<sup>a</sup>**

Characteristic	Palanivelu et al, 2007 <sup>9</sup> (n=42)	Dulucq et al, <sup>10</sup> 2006 (n=13)	Current Series (n=62)
Operative time, median, min	370	295	368
Estimated blood loss, median, mL	65	89	240
Tumor size, median, cm	2.9	2.8	3
Margin-negative resection, %	100	100	89
Pancreatic fistula, No. (%)	3 (7)	1 (8)	11 (18)
Mortality, No. (%)	1 (2)	1 (8)	1 (1.6)

<sup>a</sup>Includes only peer-reviewed series with more than 10 patients who underwent total laparoscopic pancreaticoduodenectomy.

talization with laparoscopic over open approaches.<sup>4</sup> For pancreaticoduodenectomy, however, enthusiasm has been much more dampened. Despite the initial description of laparoscopic pancreaticoduodenectomy approximately 15 years ago, acceptance has been limited owing to the technical demands of this procedure.<sup>2,5</sup> Several authors have described hybrid, laparoscopic-open approaches to avoid the complexity of a purely laparoscopic procedure.<sup>6-8</sup> While these approaches may obviate some of the limitations, they may also reduce the potential benefits of purely laparoscopic approaches and limit the ability to assess the feasibility and outcome of totally laparoscopic pancreaticoduodenectomy. After excluding patients with conversion to laparotomy or hybrid laparoscopic-laparotomy approaches, there are only 2 series in the current peer-reviewed literature in which TLPD was performed in more than 10 patients.<sup>9,10</sup> These studies have demonstrated favorable results of TLPD. **Table 3** summarizes the outcomes of these 2 studies and our current series of 62 patients. Gumbs and Gayet,<sup>11</sup> in an abstract accompanying an online video submission, briefly mention performance of laparoscopic pancreaticoduodenectomy in 35 patients. However, there is insufficient information available to assess the extent of the laparoscopic approach, operative data, or outcomes.

Pessimism of laparoscopic pancreaticoduodenectomy has risen from initial long operative time, advanced laparoscopic skills necessary, and lack of perceived benefits over open approaches. Fortunately, initially long operative times have decreased in our experience from a mean of 7.7 hours in the first 10 patients to 5.3 hours in the last 10. We agree that advanced laparoscopic skills are necessary to perform this procedure to reduce operative time, morbidity, and surgeon frustration. It is also imperative that surgeons attempting TLPD have sufficient experience with open pancreatic operations to avoid significant complications and ensure that oncologic standards of pancreatic resection are understood and maintained.

Robotic-assisted procedures are also of interest in pancreatic resection. We have used this technology in only 8 patients to date, largely because of the limited availability of the robot in our practice during this study period. Potential advantages of robotic assistance, such as added maneuverability and fine movement, may be bal-

anced by the disadvantage of lack of haptic feedback, especially in patients with a soft, friable pancreas or a tenuous anastomosis. Controlled trials performed by those experienced with both approaches will be necessary to establish any potential advantages of robotic assistance over purely laparoscopic approaches.

The current literature is insufficient to demonstrate any clear advantages of laparoscopic compared with open pancreaticoduodenectomy. Based on an increasing body of literature with regard to other laparoscopic procedures, it is reasonable to assume that the typical laparoscopic benefits of decreased pain, wound complications, and length of hospital stay will be realized. Wound complications can be a significant early (surgical site infection or dehiscence) or late (ventral hernia) morbidity of the open approach. In addition to the morbidity, these complications delay recovery and may delay adjuvant treatments. Despite the potential advantages of minimally invasive approaches, the major morbidity of pancreatic resection is pancreatic fistula and delayed gastric emptying. Whether the laparoscopic approach can reduce either of these complications is speculative. Our data suggest, however, that even within the initial learning curve of TLPD, these complication rates are comparable with those seen reported in open series, and outcomes beyond the learning curve are eagerly awaited. The learning curve for this complex procedure is not yet defined, but our early experience suggests that operative time and even leak rate may be decreasing. Our exclusion of patients for TLPD with tumors in proximity to the portal vein or superior mesenteric vein may also have resulted in a selection bias toward patients with smaller, nonobstructing lesions leading to patients with greater risk for pancreatic anastomotic leak. Both a soft pancreas and small pancreatic duct have been suggested to increase the risk of pancreatic fistula.<sup>12</sup> In our series, 9 of the 11 pancreatic fistulae occurred in patients with a soft pancreas or pancreatic duct 3 mm or smaller. The use of prophylactic drains in patients undergoing pancreaticoduodenectomy remains controversial. We do not routinely use operative drains after open or laparoscopic pancreaticoduodenectomy, as existing studies suggest that they offer no clear benefit, may increase abscess or fistula rates, and are frequently insufficient to manage the leak without additional percutaneous intervention.<sup>13,14</sup> We used prophylactic drains selectively in patients with a soft pancreas and pancreatic duct 3 mm or smaller, who we felt were at high risk of pancreatic leak.

The oncologic outcomes of laparoscopic approaches in pancreatic resection have not yet been adequately evaluated. This series lacks a sufficient number of patients and length of follow-up to accurately assess oncologic outcomes such as tumor recurrence and disease-free and overall survival. Possible surrogates to assess the oncologic procedure itself, however, may include extent of resection, margin status, and number of lymph nodes harvested. In this series, these outcomes are comparable with those reported for open pancreaticoduodenectomy,<sup>15,16</sup> suggesting at least the possibility of noninferiority. Additionally, we did not identify any patient with port-site recurrence of malignancy.

Beyond oncologic outcomes, perhaps the most important outcome measures that should direct further study



in TLPD are patient recovery and quality of life. Patients with benign disease are anxious to return to normal function, and those with malignancy may need adjuvant treatments and have shortened survivals. Any approaches that improve the patient's recovery to allow necessary adjuvant treatment or improve the quality of life would clearly be praiseworthy. For this reason, minimally invasive procedures should continue to be investigated in patients undergoing pancreatic resection.

In conclusion, this early experience suggests that TLPD is feasible and safe. Experience in pancreatic resection and possession of advanced laparoscopic skills are recommended prerequisites. While it is plausible that the typical benefits of laparoscopic approaches may be realized in patients undergoing TLPD, this remains to be substantiated. Patients undergoing pancreaticoduodenectomy could benefit greatly from reduced wound complications, quicker recovery, and improved quality of life. With increasing experience with TLPD, large series and controlled trials may become feasible to explore these possible advantages.

**Accepted for Publication:** February 10, 2009.

**Correspondence:** Michael L. Kendrick, MD, Department of Surgery, Mayo Clinic, 200 First St SW, Rochester, MN 55905 (kendrick.michael@mayo.edu).

**Author Contributions:** *Study concept and design:* Kendrick. *Acquisition of data:* Kendrick and Cusati. *Analysis and interpretation of data:* Kendrick and Cusati. *Drafting of the manuscript:* Kendrick and Cusati. *Critical revision of the manuscript for important intellectual content:* Kendrick and Cusati. *Study supervision:* Kendrick.

**Financial Disclosure:** None reported.

**Previous Presentation:** This work was presented in part at the 116th Annual Meeting of the Western Surgical Association; November 11, 2008; Santa Fe, New Mexico.

## REFERENCES

1. Gagner M, Pomp A. Laparoscopic pylorus-preserving pancreaticoduodenectomy. *Surg Endosc.* 1994;8(5):408-410.
2. Gagner M, Pomp A. Laparoscopic pancreatic resection: is it worthwhile? *J Gastrointest Surg.* 1997;1(1):20-26.
3. Pugliese R, Scandroglio I, Sansonna F, et al. Laparoscopic pancreaticoduodenectomy: a retrospective review of 19 cases. *Surg Laparosc Endosc Percutan Tech.* 2008;18(1):13-18.
4. Kooby DA, Gillespie T, Bentrem D, et al. Left-sided pancreatotomy: a multi-center comparison of laparoscopic and open approaches. *Ann Surg.* 2008; 248(3):438-446.
5. Cuschieri SA, Jakimowicz JJ. Laparoscopic pancreatic resections. *Semin Laparosc Surg.* 1998;5(3):168-179.
6. Ammorì BJ. Laparoscopic hand-assisted pancreaticoduodenectomy: initial UK experience. *Surg Endosc.* 2004;18(4):717-718.
7. Kimura Y, Hirata K, Mukaiya M, Mizuguchi T, Koito K, Katsuramaki T. Hand-assisted laparoscopic pylorus-preserving pancreaticoduodenectomy for pancreas head disease. *Am J Surg.* 2005;189(6):734-737.
8. Giulianotti PC, Coratti A, Angelini M, et al. Robotics in general surgery: personal experience in a large community hospital. *Arch Surg.* 2003;138(7):777-784.
9. Palanivelu C, Jani K, Senthilnathan P, Parthasarathi R, Rajapandian S, Madhan-kumar MV. Laparoscopic pancreaticoduodenectomy: technique and outcomes. *J Am Coll Surg.* 2007;205(2):222-230.
10. Dulucq JL, Wintringer P, Mahajna A. Laparoscopic pancreaticoduodenectomy for benign and malignant diseases. *Surg Endosc.* 2006;20(7):1045-1050.
11. Gumbs AA, Gayet B. The laparoscopic duodenopancreatotomy: the posterior approach. *Surg Endosc.* 2008;22(2):539-540.
12. Pratt WB, Callery MP, Vollmer CM Jr. Risk Prediction for development of pancreatic fistula using ISGPF classification scheme. *World J Surg.* 2008;32(3): 419-428.
13. Conlon KC, Labow D, Leung D, et al. Prospective randomized clinical trial of the value of intraperitoneal drainage after pancreatic resection. *Ann Surg.* 2001; 234(4):487-494.
14. Kendrick ML, Nagorney DM, Sarr MG, et al. The value of prophylactic intraperitoneal drainage with Pancreaticoduodenectomy for pancreatic head and periampullary neoplasms [abstract]. *J Gastrointest Surg.* 2003;7:297.
15. Sohn TA, Yeo CJ, Cameron JL, et al. Resected adenocarcinoma of the pancreas—616 patients: results, outcomes, and prognostic indicators. *J Gastrointest Surg.* 2000;4(6):567-579.
16. Schnelldorfer T, Ware AL, Sarr MG, et al. Long-term survival after pancreaticoduodenectomy for pancreatic adenocarcinoma: is cure possible? *Ann Surg.* 2008; 247(3):456-462.