

ONLINE FIRST

# Fate of the Pancreatic Remnant After Resection for an Intraductal Papillary Mucinous Neoplasm

## A Longitudinal Level II Cohort Study

Toshiyuki Moriya, MD, PhD; L. William Traverso, MD

**Objective:** To determine the occurrence of new disease in the pancreatic remnant after resection for intraductal papillary mucinous neoplasms.

**Design:** A longitudinal level II cohort study.

**Setting:** Virginia Mason Medical Center, Seattle, Washington.

**Patients:** The primary cohort was a “resection cohort” of 203 patients who underwent partial pancreatic resection for an intraductal papillary mucinous neoplasm.

**Main Outcome Measures:** The occurrence rate of lesions in the pancreatic remnant after resection for an intraductal papillary mucinous neoplasm, determined by use of an annual computed tomographic scan of the pancreas.

**Results:** New lesions were observed in the remnant of 17 of the 203 patients (8%) after a median follow-up of 40 months and a median interval of 38 months from the initial resection. Only 1 of these 17 patients with new lesions had a surgical margin that was positive for an ad-

enoma at the time of resection. Comparing the 17 patients with new lesions with the 186 patients without new lesions, we found no difference in age, sex, procedure type, location in ductal system, original histology, or original margin status. In the new lesion group, no treatment was used for 12 patients who had side-branch disease detected by imaging (6% of all patients). Surgical treatment was used for 5 patients (2% of all patients): 2 with adenomas, 1 with a carcinoma in situ, and 2 with an invasive ductal carcinoma (1 with liver metastases).

**Conclusions:** We found that, following a partial pancreatic resection for an intraductal papillary mucinous neoplasm and a 40-month follow-up with an annual computed tomographic scan of the pancreas, 17 of 203 patients (8%) developed a new intraductal papillary mucinous neoplastic lesion in the pancreatic remnant. As follow-up time increases, we suspect that new lesions will constantly appear regardless of whether the surgical margin was negative at initial resection.

*Arch Surg.* 2012;147(6):528-535. Published online February 20, 2012. doi:10.1001/archsurg.2011.2276

**B**ECAUSE AN INTRADUCTAL papillary mucinous neoplasm (IPMN) of the pancreas is more common in clinical practice today, there is much interest in its natural history, yet most articles on the subject indicate that the natural history is unknown.<sup>1</sup> However, as our experience increases, the management of an IPMN has become more standardized. One question that could be answered using the natural history of an IPMN is the occurrence rate of new lesions. After resection of an IPMN, will another IPMN occur in the pancreatic remnant? Will the new IPMN in the remnant be benign or malignant depending on the original lesion? Knowing an expected biologic time schedule for the development of new lesions would be useful in determining the timing of follow-up imaging studies.<sup>1</sup> If this information suggested continued risk for new lesions, it would sup-

port the concept that the tendency for an IPMN is not focal in the pancreas, where the primary tumor arose, but is more diffuse in the pancreatic parenchyma (ie, a “field defect”). A longitudinal cohort study following the pancreatic remnant in patients after resection for an IPMN could help answer these questions. Is the process slow or fast and/or focal or diffuse?

### See Invited Critique at end of article

Previously, we reviewed the literature for the period from 1993 to 2006 and found 2547 resected cases from 28 case series. Only 7 of these studies<sup>2-8</sup> provided some information about the pancreatic remnant. These 7 studies report 486 resected cases with a median follow-up of 26 to 53 months. Half of these cases (n=245) were determined to be a benign IPMN, and these benign cases showed a

**Author Affiliations:** Section of General, Vascular, and Thoracic Surgery, Virginia Mason Medical Center, Seattle, Washington. Dr Traverso is now with the Center for Pancreatic Disease, Boise, Idaho.

new lesion rate of 2% (5 cases), with only 1 case having a malignant tumor (carcinoma in situ). From this sparse data, the appearance of a new IPMN in the remnant after a resection for benign disease would be considered uncommon. However, the follow-up was not standardized in these reported cases from multiple centers and may be underestimating the new occurrence rate of the disease.

In addition to the occurrence rate in the pancreatic remnant, surgeons are faced with the question of how much of the pancreas to resect, weighing the risk of recurrence at the margin against the morbidity of additional resection. One previous study<sup>9</sup> suggested that recurrence in the remnant was more likely to be increased in patients with an IPMN at the surgical pancreatic cut margin, but most studies<sup>3-8,10-13</sup> do not show this relationship between a surgical pancreatic cut margin positive for an IPMN and the recurrence in the remnant at the surgical margin or the occurrence of new lesions in the remnant.

To examine both the rate of occurrence of IPMNs in the pancreatic remnant and the relationship between new lesions and disease at the surgical cut margin, we conducted a prospective cohort study, with the cohort being those with a pancreatic remnant after resection for an IPMN. These patients were from a single institution that was conducting a lifelong annual follow-up to answer these questions.

## METHODS

### DEFINITIONS

A *cohort* is a segment of the population that had undergone a partial pancreatic resection for an IPMN. In our study, the primary cohort was a "resection cohort" of patients whose life histories were being studied to determine the occurrence of new disease in the pancreatic remnant after resection for an IPMN. A *pancreatic remnant* is the portion of the pancreas that is left in place at the time of a surgical resection.

In the case of multiple lesions at the time of a surgical resection for an IPMN, a *residual lesion* is a lesion that may have been purposely left in the remnant of the pancreas if it did not meet criteria for resection based on international guidelines. A *surgical margin* or *pancreatic cut margin* is positive for an IPMN if the permanent sections of the surgical margin of the resected pancreas showed the presence of any form of an IPMN (ie, adenoma, borderline neoplasm, in situ carcinoma, or invasive carcinoma).

A *new lesion* is a lesion that is consistent with an IPMN and that was discovered in the pancreatic remnant during follow-up. Prior to resection, the new lesion had not been seen on any imaging study and, when first observed, was felt to be consistent with an IPMN. A *local recurrence* is any lesion discovered in the bed of the resected pancreas.

### STUDY DESIGN

The present study is a single-institution cohort study. The primary cohort comprised 219 patients who underwent curative pancreatectomy for an IPMN by a single surgeon between 1989 and 2010 at the Virginia Mason Medical Center in Seattle, Washington. Sixteen of these patients were excluded because they did not have a pancreatic remnant (ie, they underwent a total pan-

atectomy). The remaining 203 patients were entered into our study. We prospectively performed annual lifelong follow-ups for all patients. After hospital discharge, the patients underwent computed tomographic (CT) scans of their pancreases at the time of their annual follow-up visits. At that time, the senior author (L.W.T.) interviewed each patient for the presence of symptoms that might be attributable to the pancreatic remnant (ie, upper abdominal pain or documented pancreatitis).

### PATHOLOGICAL CLASSIFICATION

All cases of IPMN were histologically confirmed by a collaborative group of 10 staff pathologists. An IPMN was distinguished from a mucinous cystic neoplasm by the former having connection to the pancreatic ductal system (based mainly on endoscopic retrograde cholangiopancreatography) and a lack of ovarian-type stroma.<sup>14</sup> These IPMN lesions were also distinguished from pancreatic intraepithelial neoplasia by their being greater than 1 cm in size either grossly or radiographically.<sup>15</sup> We used the 4 categories of the World Health Organization classification for IPMN: adenoma, borderline neoplasm, carcinoma in situ, and invasive carcinoma.<sup>16,17</sup> The pathological diagnosis was based on the most severe epithelial dysplasia within the tumor as determined by the staff pathologist. The surgical cut margin status was examined by both an intraoperative frozen section and the final permanent sections of the cut margin. In the present study, the cut margin status was based on the permanent sections.

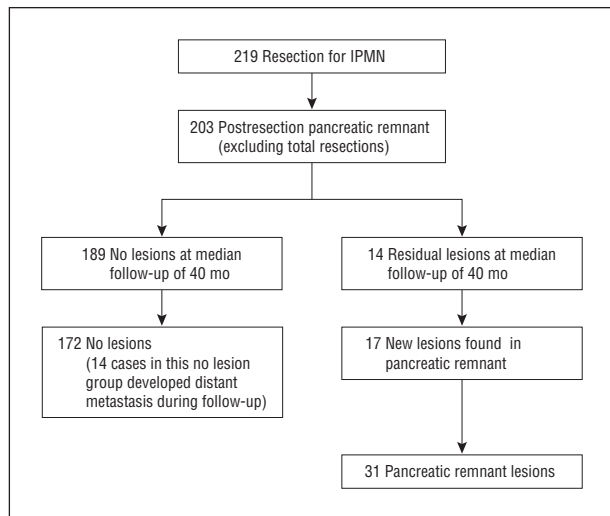
### RESIDUAL AND NEW LESIONS

The radiographic sizes of the residual pancreatic lesions that were left in pancreatic remnants were recorded to determine whether they might now meet criteria for resection. Was the judgment to save this portion of the pancreas (based on international criteria) adequate to avoid subsequent resection due to progression of disease? The occurrence of a new pancreatic lesion in the pancreatic remnant was determined radiographically and confirmed either pathologically or clinically. The primary end point was the date of the last follow-up computed tomography or, if required, the date of a secondary pancreatic resection for pancreatic remnant lesions.

To look for risk factors for the development of new lesions, we recorded the rate of occurrence of any new pancreatic remnant lesion during annual follow-up. Then we compared the group with new lesions with the group without new lesions using sex, age, operative procedure at first resection, duct location, histology, and surgical pancreatic cut margin status at the site of the original operation. Next we examined the outcomes of patients with residual lesions to determine whether our judgment to preserve this parenchyma had been correct, and then we examined the outcomes of those with new pancreatic remnant lesions. Finally, we investigated the outcomes of those who required an additional pancreatic resection.

### INDICATION FOR SURGICAL RESECTION FOR ORIGINAL OR NEW LESIONS

More specifically, there were 3 indications for resection based on international guidelines: the lesion was felt to be causing symptoms, regardless of location in the ductal system; the lesion was thought to involve the main pancreatic duct (MPD), even if asymptomatic; and the presence of an intraductal papillary mucinous neoplastic side-branch duct (SBD) lesion with "malignant risk," where an asymptomatic SBD-type lesion was associated with at least 1 predictive criterion of malignancy.<sup>18</sup> The latter criteria included the presence of a SBD cyst more than



**Figure 1.** Flowchart of 219 patients in our longitudinal level II cohort study. During the original pancreatic resection, 14 of 203 patients (7%) had residual lesions in their pancreatic remnants that did not meet criteria for resection by international criteria. These lesions were intentionally left in the remnant to preserve pancreatic parenchyma. The remaining 189 patients (93%) had no residual lesions in their pancreatic remnants after their first resections. After a median follow-up period of 40 months (range, 3-127 months), new lesions developed in the pancreatic remnants of 17 patients (8%). Therefore, 31 of 203 patients (15%) had lesions in their pancreatic remnants at the end of the follow-up period. IPMN indicates intraductal papillary mucinous neoplasm.

30 mm in size, the presence of any mural nodule in a SBD cyst determined by imaging, or the presence of malignancy determined by cytology.

## STATISTICAL ANALYSIS

Continuous data are presented as mean (SD) values. The Mann-Whitney *U* test was used for all comparisons among continuous variables. Categorical variables were compared by using the  $\chi^2$  test or the Fisher exact test when appropriate. A *P* value of less than .05 was accepted as statistically significant.

## RESULTS

### PATIENT POPULATION

Between 1989 and 2010, a total of 203 patients underwent a curative partial pancreatic resection for an IPMN; because our study focused on the pancreatic remnant, we excluded 16 of 219 patients with a total pancreatectomy (**Figure 1**). The median age was 66 years (range, 32-90 years). Of the 203 patients who underwent a curative partial pancreatic resection for an IPMN, 93 (46%) were women, and 110 (54%) were men.

The tumors were located in the head of the pancreas (74% of patients) and in the tail (26% of patients). A pancreaticoduodenectomy was performed for 146 patients (72%), of whom 142 underwent a pylorus-preserving pancreaticoduodenectomy, whereas 4 patients underwent a classic pancreaticoduodenectomy with antrectomy. Forty-nine patients (24%) underwent a distal pancreatectomy, and 8 patients (4%) a central pancreatectomy. The final histologic diagnoses of the IPMN were adenoma (78 patients [38%]), borderline neoplasm (50 patients [25%]), carci-

noma in situ (32 patients [16%]), and invasive carcinoma (43 patients [21%]). The location of the tumor in relation to the pancreatic ductal system was the MPD (89 patients [44%]), the MPD and the SBD (35 patients [17%]), and the SBD (79 patients [39%]). After the original resection, 187 of 203 patients (92%) had specimens that were negative for an IPMN in the final histologic surgical cut margin of the pancreas, whereas 16 of 203 patients (8%) had margins that contained some lesion: adenoma (11 patients), borderline neoplasm (2 patients), carcinoma in situ (1 patient), and an unknown lesion (2 patients).

## RESIDUAL AND NEW LESIONS OF THE PANCREATIC REMNANT

At the original pancreatic resection, 14 of 203 patients (7%) had residual lesions in the pancreatic remnant that did not meet criteria for resection. These lesions were left in place to preserve the pancreatic parenchyma. The remaining 189 patients (93%) had no residual lesions in their pancreatic remnant after the first resection (**Figure 1**).

After a median follow-up of 40 months (range, 3-127 months), new lesions developed in the pancreatic remnant in 17 (8%) of 203 patients (**Figure 1**). Therefore, 31 patients (15%) had lesions in their pancreatic remnant at the end of the follow-up period. The mean number of cysts in the pancreatic remnant was 1.5 (range, 1-7), and the mean maximum diameter of the cysts was 10.3 mm (range, 3-32 mm).

At the end of the follow-up period, 14 patients (7%) had developed distant metastases, and 6 patients (3%) had a local recurrence located in the pancreatic bed. These 20 patients were included in the “no-new-lesion” group because they did not have a new lesion in the pancreatic remnant (**Figure 1**).

## COMPARISON BETWEEN PATIENTS WITH AND PATIENTS WITHOUT NEW LESIONS IN THE PANCREATIC REMNANT

**Table 1** shows a comparison of 203 patients requiring a partial pancreatic resection for an IPMN based on the appearance of new lesions in the pancreatic remnant (yes or no) during a median follow-up of 40 months. There were no significant differences between the no-new-lesion group and the new-lesion group with regard to sex, age, operative procedure, duct location, original histology, and surgical pancreatic cut margin status at the site of the original operation. Note that only 1 of 43 patients with an original histology of invasive IPMN developed a new lesion in their pancreatic remnant.

## OUTCOME OF LESIONS IN THE PANCREATIC REMNANT

**Figure 2** shows the outcome after the follow-up period of the 31 patients with lesions in their pancreatic remnant that were either lesions left in the remnant at the time of resection (14 residual lesions) or were identified by new imaging observations (17 new lesions). All 14 residual lesions were considered SBD-type IPMNs that were less than 3 cm in diameter. During the follow-up pe-

**Table 1. Characteristics of 203 Patients Requiring Partial Pancreatic Resection for an IPMN Based on Appearance of New Lesions During a Median Follow-up of 40 Months**

Characteristic	Patients, No. (%)		P Value
	No New Lesions (n = 186)	New Lesions in Pancreatic Remnant (n = 17)	
Sex, No.			
Male	100	10	.69
Female	86	7	
Age, mean (SD), y	66 (11)	66 (10)	.93
Procedure			
PD	134 (72)	12 (71)	.92
DP	45 (24)	4 (24)	
CP	7 (4)	1 (6)	
Duct location			
MPD	82 (44)	7 (41)	.97
MPD and SBD	32 (17)	3 (18)	
SBD	72 (39)	7 (41)	
Original histology			
Adenoma	70 (38)	8 (47)	.25
Borderline neoplasm	44 (24)	6 (35)	
Carcinoma in situ	30 (16)	2 (12)	
Invasive carcinoma	42 (23)	1 (6)	
Margin status			
Negative for dysplasia	171 (92)	16 (94)	.93
Positive for adenoma	10 (5)	1 (6)	
Positive for borderline neoplasm	2 (1)	0 (0)	
Positive for carcinoma in situ	1 (1)	0 (0)	
Positive for invasive carcinoma	0 (0)	0 (0)	
Unknown	2 (1)	0 (0)	
Time to new lesions after resection, mean (SD), mo		38 (20)	

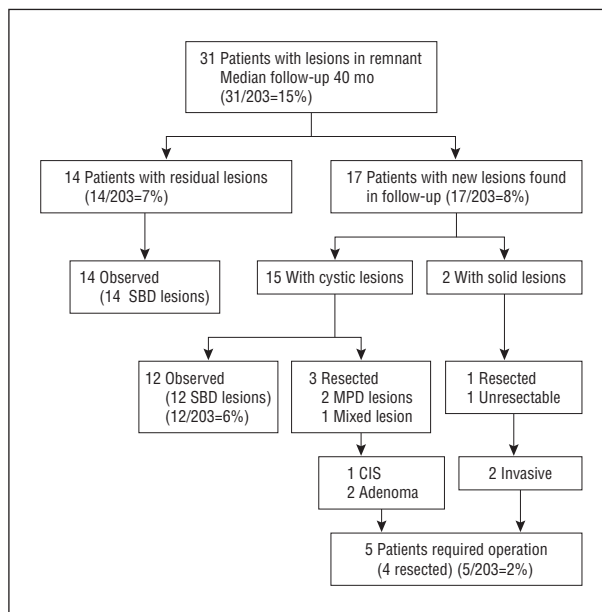
Abbreviations: CP, central pancreatectomy; DP, distal pancreatectomy; IPMN, intraductal papillary mucinous neoplasm; MPD, main pancreatic duct; PD, pancreaticoduodenectomy; SBD, side-branch duct.

riod, none of these 14 patients had residual lesions that changed in size, and none of these 14 patients developed any symptoms.

Figure 2 also illustrates the number of patients with new lesions that had been observed in the pancreatic remnant (17 patients [8%]). Of these 17 patients with pancreatic remnant lesions, 15 had cystic lesions. A total of 12 patients had SBD lesions that did not change in size and were observed for a median of 50 months (range, 13-112 months). Secondary operations were felt necessary for 5 patients with new lesions because all of these new lesions were in the MPD; 2 were associated with suspicious solid lesions.

#### DETAILS OF SECONDARY OPERATIONS THAT 5 PATIENTS UNDERWENT FOR LESIONS IN THE PANCREATIC REMNANT

**Table 2** and **Table 3** show the details of secondary operations that 5 patients underwent for lesions in the pancreatic remnant. Note that, between 15 and 127 months from the first resection, all 5 patients with new lesions required resection that involved the MPD. Those pa-



**Figure 2.** Flowchart of 31 of 203 patients (15%) with lesions found in the pancreatic remnants who underwent a partial pancreatic resection. Fourteen of the 31 patients had residual lesions intentionally left in their remnants during their first pancreatic resections. All 14 patients had residual lesions that were considered side-branch duct (SBD)-type intraductal papillary mucinous neoplasms that were less than 3 cm in diameter. None of these residual lesions changed in size during the median follow-up period of 40 months. New lesions were observed in the pancreatic remnants of 17 patients (8%). Of these 17 patients, 15 had cystic lesions, and 2 had solid lesions. Two of these patients had lesions that were located in the main pancreatic duct (MPD), 1 patient had lesions that were located in the MPD and SBD (mixed lesions), and 12 patients had lesions that were located in the SBD. We observed all 12 patients with SBD lesions for a median of 50 months (range, 13-112 months), and all of these lesions remained the same size. Secondary operations were felt necessary in 5 cases (with 4 cases having lesions that were resected); the criteria were MPD location (3 patients) and suspicious solid lesion (2 patients). The pathological findings for the MPD lesions were carcinoma in situ (CIS; 1 patient) and adenoma (2 patients), and both solid lesions were invasive adenocarcinomas arising in the MPD.

tients who had a lesion with an original histology that was malignant (carcinoma in situ or invasive carcinoma) developed new malignant lesions. Those patients with benign disease originally (adenoma or borderline neoplasm) developed benign lesions.

A 70-year-old man originally underwent a pylorus-preserving pancreaticoduodenectomy for an invasive IPMN with a surgical cut margin that was negative for IPMN. He developed a solid mass in the remnant (pancreatic tail) 127 months later and underwent completion pancreatectomy for an invasive carcinoma. He died 16 months later of disease.

A 56-year-old woman who underwent a distal pancreatectomy for carcinoma in situ with a surgical cut margin negative for IPMN developed abdominal pain 39 months later, and a CT scan revealed a solid mass in the head of the pancreas. She underwent an operation with a curative intent; however, liver metastases were detected intraoperatively. Liver and lymph node biopsies revealed invasive adenocarcinoma. She was alive at 8 months postoperatively and undergoing chemotherapy.

A 74-year-old woman underwent a distal pancreatectomy for carcinoma in situ with a surgical cut margin negative for IPMN and developed abdominal pain 40 months



**Table 2. Details of 5 Cases Requiring a Second Operation for New Lesions in Pancreatic Remnant**

Patient Sex/ Age, y	First Resection				Second Operation	
	Procedure	Duct Location <sup>a</sup>	Histology	Surgical Cut Margin Status	Reason for 2nd Resection	Duration Between 1st and 2nd Operation, mo
M/70	PpPD	Mixed	Invasive	Negative for IPMN	Solid mass	127
F/56	DPS	MPD	CIS	Negative for IPMN	Solid mass, abdominal pain	39
F/74	DPS	MPD	CIS	Negative for IPMN	MPD-type lesion, abdominal pain	40
M/73	PpPD	Mixed	Adenoma	Negative for IPMN	MPD-type lesion, abdominal pain	108
F/64	PpPD	Mixed	Adenoma	Positive for adenoma	Mixed-type lesion, abdominal pain	15

Abbreviations: CIS, carcinoma in situ; DPS, distal pancreatectomy, splenectomy; IPMN, intraductal papillary mucinous neoplasm; MPD, main pancreatic duct; PpPD, pylorus-preserving pancreaticoduodenectomy; SBD, side-branch duct.

<sup>a</sup>A mixed-type lesion is one that is located in the MPD and SBD.

**Table 3. Outcome of 5 Patients Who Underwent a Second Operation**

Patient Age, <sup>a</sup> y	Second Operation		After Second Operation		
	Procedure	Histology	Follow-up Period, mo	Recurrence?	Disease-Specific Death?
80	Completion pancreatic resection	Invasive adenocarcinoma	16	Yes	Yes
59	Unresectable <sup>b</sup>	Invasive adenocarcinoma	8	Yes	No
77	Completion pancreatic resection	Carcinoma in situ	100	No	No
82	Completion pancreatic resection	Adenoma	20	No	No
66	Excision of body of the pancreas	Adenoma	68	No	No

<sup>a</sup>At the time of second resection.

<sup>b</sup>Unresectable due to intraoperative findings of liver metastasis.

later. A CT scan revealed pancreatic ductal dilatation without solid mass. She underwent completion pancreatectomy for carcinoma in situ located in the pancreatic head. She is doing well without evidence of disease 100 months later.

A 73-year-old man underwent a pylorus-preserving pancreaticoduodenectomy for an intraductal papillary mucinous neoplastic adenoma in the MPD with a surgical cut margin negative for IPMN. He developed abdominal pain 105 months later, and a CT scan revealed main pancreatic ductal dilatation without solid mass. He underwent completion pancreatectomy for an intraductal papillary mucinous neoplastic adenoma located in MPD. He is doing well without evidence of recurrent disease 20 months later.

A 64-year-old woman underwent a pylorus-preserving pancreaticoduodenectomy for an adenoma located in the MPD with a surgical cut margin positive for an intraductal papillary mucinous neoplastic adenoma. She developed abdominal pain 15 months later, and a CT scan revealed dilatation of the MPD and the SBD without solid mass. She underwent excision of the body of the pancreas for the adenoma located in the MPD. She is doing well without evidence of recurrent disease 68 months later.

### COMMENT

Our study focuses on the fate of the pancreatic remnant after pancreatic resection for an IPMN. Planned lifelong follow-up was completed annually with CT imaging in a cohort of patients who had undergone pancreatic resection for an IPMN. The international criteria for when

to resect cystic lesions allowed us to successfully utilize parenchymal preservation to avoid diabetes. For instance, when multiple intraductal papillary mucinous neoplastic lesions were found in the pancreas, only those lesions that met the criteria were resected. For instance, 14 cases had lesions that did not meet international criteria, and these lesions were left in place to allow parenchymal preservation. None of these lesions progressed to require an operation after a median follow-up period of 40 months.

Also during this period, just 17 of 203 patients (8%) developed a new lesion in the remnant. Five of these 17 new cases met the criteria for an additional resection. All the resected new lesions involved the MPD: 3 patients had malignant lesions originally and developed new lesions that were malignant, whereas 2 patients had benign lesions originally and developed new lesions that were benign. Surprisingly, the occurrence of a new lesion in the pancreatic remnant was not associated with the original duct location (the MPD or the SBD), the original histology (benign or malignant), or the status of the surgical pancreatic cut margin at the site of the original operation. Note that there were no margins positive for invasive cancer, but we had an 8% positive margin rate (all benign or carcinoma in situ). This finding suggested that new lesions were uncommon and, when they occurred, were part of a diffuse field defect that involved the entire pancreas. Progression of a field defect in the pancreatic remnant was therefore slow and uncommon, regardless of the original histology, at least within the limits of our 40-month follow-up period.

**Table 4. Review of Studies for Intraductal Papillary Mucinous Neoplasms**

Study	Year	Patients, No.	Positive Margin Rate, %	Mean or Median Follow-up, mo (Range)	New Lesions in Pancreatic Remnant Detected by Imaging, %	New Lesions in Pancreatic Remnant Requiring Any Treatment, %	Correlation Between Cut Margin Positive for IPMN and Subsequent New Pancreatic Lesions?
Chari et al <sup>5</sup>	2002	113	8	37	Not stated	9 <sup>a</sup>	No
Sohn et al <sup>10</sup>	2004	136	29	24	Not stated	4 <sup>a</sup>	No
Salvia et al <sup>6</sup>	2004	140	23	40	Not stated	7 <sup>a</sup>	No
Wada et al <sup>7</sup>	2005	100	7	31	Not stated	2	No
Raut et al <sup>8</sup>	2006	35	23	30	Not stated	3 <sup>a</sup>	No
White et al <sup>9</sup>	2007	78	29	40 (4-162)	Not stated	8 <sup>a</sup>	Yes
Schnelldorfer et al <sup>11</sup>	2008	208	11	38 (0-180)	3	1	No
Kim et al <sup>12</sup>	2008	118	20	62 (18-134)	Not stated	0	No
Present report	2011	203	8	40 (3-129)	8	2	No
Total		1131	18	(24-62)	5	4	Yes, 1; no, 8

<sup>a</sup>Possibly included pancreatic bed recurrence.

The literature on new pancreatic lesions developing in the remnant after resection seems to support these findings. **Table 4** reviews 9 studies<sup>5-12</sup> for a total of 1131 cases with follow-up of the pancreatic remnant following resection for an IPMN. Surgical margins were positive for some form of an IPMN in 18% of cases (range, 7%-29% of cases), with a mean or median follow-up ranging from 24 to 62 months. Only 2 studies (the study by Schnelldorfer et al<sup>11</sup> and our own) specifically stated the occurrence rate of new lesions in the pancreatic remnant by use of imaging: Schnelldorfer et al<sup>11</sup> found an occurrence rate of 3%, and we found an occurrence rate of 8%. All studies in Table 4 described a resection rate for new lesions (mean rate, 4% [range, 0%-9%]). Except for the one study by Kim et al,<sup>12</sup> all the remaining studies<sup>5-11</sup> (including our own) did not find a correlation between surgical cut margin involvement and development of new lesions in the remnant. These findings support the concept that new lesions can develop in the pancreatic remnant at the same low rate in those with or without surgical margins positive for IPMN (provided it is not invasive cancer). The process is slow, and the chance of a new malignant tumor in the remnant is low after resection. Our current policy is to focus on parenchymal preservation for cases with either a benign or malignant IPMN if the surgical cut margin does not contain a malignant tumor (a carcinoma in situ or an invasive IPMN); other lesions remote from the primary IPMN are not resected if they do not meet the international criteria for resection.

Our goal has been to maintain a surgical margin at the line of pancreatic resection that is negative for IPMN. We performed additional resections on 26 patients (13%) based on the frozen section to avoid a cut surgical margin positive for any dysplasia. However, most pathologists experience difficulty analyzing frozen sections for dysplasia. Recall that our study uses the permanent sections for analysis, but with frozen sections, we seek to avoid the permanent section having a carcinoma in situ or an invasive IPMN. In an effort to promote parenchymal preservation, we used total pancreatectomy on just 16 patients and only when the entire MPD was thought to be involved.

In summary, we found that, after a partial pancreatic resection for an IPMN and a 40-month follow-up with

annual imaging, 8% of patients developed a new intraductal papillary mucinous neoplastic lesion in the pancreatic remnant and 2% required a second resection. The new lesions that developed were more commonly benign, but when patients with either an original benign or malignant lesion later developed a new lesion, it was the same as that of the original pathology (Table 1). Tables 2 and 3 support this finding by showing that, if those patients with an original malignant pathology required an operation, it was for a new malignant lesion, and if those patients with an original benign pathology required an operation, it was for a benign lesion.

Caution should be used while interpreting these results. Even though more than 200 resected cases were annually followed for almost 4 years by the same team, there were just 17 cases with new lesions in the pancreatic remnant to analyze for predictive factors. In this small number of cases, the surgical margin status did not seem to matter when compared with the larger group with no lesions. We suspect that, as our follow-up time increases, new lesions will constantly appear regardless of whether the surgical margin at initial resection is negative for new disease. The annual follow-up of our study was performed to be inclusive and standardized. We cannot recommend annual follow-up CT scanning for everyone (as we did in our study). However, with 62% of these cases having benign lesions and with a median follow-up period of 40 months, we observed the occurrence rate to be 4 times that described in the combined literature (up from 2% to 8%). If a 10-year follow-up could be performed, the rate of new lesions in the remnant should be higher. Therefore, the decision to scan again may be based on the knowledge that 8% of patients will have new lesions in 4 years and that one might assume that 1 in 5 patients may have new lesions in 10 years.

How often should we scan if the chance of a new lesion is around 20% at 10 years? Recall that new lesions tend to be benign and of the same proportions as the original lesions (Table 1). Also, the need for an operation for a new lesion was due to a histology similar to that of the original lesion: a new malignant lesion had an original histology that was malignant, whereas a new benign lesion had an original histology that was benign. New lesions appear to retain a similar biology, as reflected his-

tologically. This might help us to decide how often to reimaging: annually for malignant lesions and every 2 or 3 years for benign lesions, with the proviso that they remain asymptomatic. Any patient that becomes symptomatic from the standpoint of the pancreas requires reimaging. Some follow-up on every patient should be done on a regular basis.

**Accepted for Publication:** December 13, 2011.

**Published Online:** February 20, 2012. doi:10.1001/archsurg.2011.2276

**Correspondence:** L. William Traverso, MD, Center for Pancreatic Disease, 100 E Idaho St, Ste 301, Boise, ID 83712 (traversw@slhs.org).

**Author Contributions:** *Study concept and design:* Moriya and Traverso. *Acquisition of data:* Moriya. *Analysis and interpretation of data:* Moriya. *Drafting of the manuscript:* Moriya and Traverso. *Critical revision of the manuscript for important intellectual content:* Moriya and Traverso. *Statistical analysis:* Moriya. *Administrative, technical, and material support:* Traverso. *Study supervision:* Traverso. **Financial Disclosure:** None reported.

**Funding/Support:** Funding for this study was provided by the Virginia Mason Medical Clinic.

**Previous Presentations:** Presented in part at the 45th Annual Meeting of the Pancreas Club; May 7, 2011; Chicago, Illinois (long oral presentation); and in part at the Annual Meeting of the Society of Surgery of the Alimentary Tract; May 10, 2011; Chicago, Illinois (poster).

## REFERENCES

1. Traverso LW, Kozarek RA. Diagnosis and natural history of intraductal papillary mucinous neoplasms. In: Beger HG, Büchler MW, Kozarek RA, eds, et al. *The Pancreas: An Integrated Textbook of Basic Science, Medicine, and Surgery*. 2nd ed. Malden, MA: Blackwell Publishing; 2008:918-923.
2. Sho M, Nakajima Y, Kanehiro H, et al. Pattern of recurrence after resection for intraductal papillary mucinous tumors of the pancreas. *World J Surg*. 1998; 22(8):874-878.
3. Paye F, Sauvanet A, Terris B, et al. Intraductal papillary mucinous tumors of the pancreas: pancreatic resections guided by preoperative morphological assessment and intraoperative frozen section examination. *Surgery*. 2000;127(5): 536-544.
4. Terris B, Ponsot P, Paye F, et al. Intraductal papillary mucinous tumors of the pancreas confined to secondary ducts show less aggressive pathologic features as compared with those involving the main pancreatic duct. *Am J Surg Pathol*. 2000;24(10):1372-1377.
5. Chari ST, Yadav D, Smyrk TC, et al. Study of recurrence after surgical resection of intraductal papillary mucinous neoplasm of the pancreas. *Gastroenterology*. 2002;123(5):1500-1507.
6. Salvia R, Fernández-del Castillo C, Bassi C, et al. Main-duct intraductal papillary mucinous neoplasms of the pancreas: clinical predictors of malignancy and long-term survival following resection. *Ann Surg*. 2004;239(5):678-685, discussion 685-687.
7. Wada K, Kozarek RA, Traverso LW. Outcomes following resection of invasive and noninvasive intraductal papillary mucinous neoplasms of the pancreas. *Am J Surg*. 2005;189(5):632-636, discussion 637.
8. Raut CP, Cleary KR, Staerckel GA, et al. Intraductal papillary mucinous neoplasms of the pancreas: effect of invasion and pancreatic margin status on recurrence and survival. *Ann Surg Oncol*. 2006;13(4):582-594.
9. White R, D'Angelica M, Katabi N, et al. Fate of the remnant pancreas after resection of noninvasive intraductal papillary mucinous neoplasm. *J Am Coll Surg*. 2007;204(5):987-993, discussion 993-995.
10. Sohn TA, Yeo CJ, Cameron JL, et al. Intraductal papillary mucinous neoplasms of the pancreas: an updated experience. *Ann Surg*. 2004;239(6):788-797, discussion 797-799.
11. Schnellendorfer T, Sarr MG, Nagorney DM, et al. Experience with 208 resections for intraductal papillary mucinous neoplasm of the pancreas. *Arch Surg*. 2008; 143(7):639-646, discussion 646.
12. Kim SC, Park KT, Lee YJ, et al. Intraductal papillary mucinous neoplasm of the pancreas: clinical characteristics and treatment outcomes of 118 consecutive patients from a single center. *J Hepatobiliary Pancreat Surg*. 2008;15(2):183-188.
13. Moriya T, Kimura W, Sakurai F, et al. Minute invasive ductal carcinoma of the residual pancreas after distal pancreatectomy for intraductal papillary-mucinous tumor. *Int J Gastrointest Cancer*. 2002;31(1-3):191-197.
14. Zamboni G, Scarpa A, Bogina G, et al. Mucinous cystic tumors of the pancreas: clinicopathological features, prognosis, and relationship to other mucinous cystic tumors. *Am J Surg Pathol*. 1999;23(4):410-422.
15. Longnecker DS, Adler G, Hruban RH, Klöppel G. Intraductal papillary-mucinous neoplasms of the pancreas. In: Hamilton SR, Aaltonen LA, eds. *World Health Organization Classification of Tumours: Pathology and Genetics: Tumours of the Digestive System*. Lyon, France: IARC Press; 2000:237-241.
16. Klöppel G, Solcia E, Longnecker DS, Capella C, Sobin LH. *World Health Organization International Classification of Tumours. Histological Typing of Tumours of the Exocrine Pancreas*. Germany: Springer-Verlag Berlin Heidelberg; 1996:1-61.
17. Klöppel G, Lüttges J. WHO-classification 2000: exocrine pancreatic tumors. *Verh Dtsch Ges Pathol*. 2001;85:219-228.
18. Tanaka M, Chari S, Adsay V, et al; International Association of Pancreatology. International consensus guidelines for management of intraductal papillary mucinous neoplasms and mucinous cystic neoplasms of the pancreas. *Pancreatol*. 2006;6(1-2):17-32.

## INVITED CRITIQUE

### The Balance

The more data accumulate on intraductal papillary mucinous neoplasms (IPMNs), the more we see that its treatment is a balancing act. Are all IPMNs premalignant? Should all diseases be resected? Can we leave positive margins? How often should we follow-up with patients postoperatively?

Moriya and Traverso<sup>1</sup> show that this “field defect” in pancreatic genetics should be handled by experts. A cohort of 203 patients underwent partial pancreatic resection by a surgeon who tailored operations using recent theory and who leads a very effective multidisciplinary group. Postoperatively, patients were cautiously ob-

served for 40 months. Only from a model like this can we learn about IPMNs.

Intraductal papillary mucinous neoplasms are not simple lesions. There are 4 types of pathology, and Moriya and Traverso<sup>1</sup> introduce new terms such as *residual lesions* (for IPMNs deliberately, and safely, left in the remnant of the pancreas after the first operation to preserve parenchyma) and *new lesions* (for IPMNs that are discovered in the pancreatic remnant during follow-up after surgery).

The data in the study by Moriya and Traverso<sup>1</sup> show that, in the 10% of patients who had a residual lesion or