

Distal Splenorenal Shunt

Role, Indications, and Utility in the Era of Liver Transplantation

Roger L. Jenkins, MD; Roberto Gedaly, MD; James J. Pomposelli, MD, PhD; Elizabeth A. Pomfret, MD, PhD; Fredric Gordon, MD; W. David Lewis, MD

Hypothesis: The distal splenorenal shunt (DSRS) continues to play an important role in the management of recurrent variceal bleeding with minimal negative impact on subsequent orthotopic liver transplantation (OLT).

Design: Case-control study.

Setting: Hepatobiliary surgery and liver transplantation unit in a tertiary referral medical center.

Patients: From August 1, 1985, through October 31, 1997, a single team of surgeons performed 81 DSRS procedures for recurrent variceal hemorrhage. Eleven patients undergoing OLT subsequent to DSRS were compared with a group of 274 patients undergoing OLT without any previous shunt during the same period.

Main Outcome Measures: Operative time, use of blood products, length of hospital stay, perioperative complications, and survival rates.

Results: Operative (30-day) mortality for DSRS was 6%

(n = 5). From follow-up information available for 74 patients, the 1- and 5-year survival rates were 86.4% (n = 64) and 74.3% (n = 55), respectively. Recurrent variceal bleeding and hepatic encephalopathy occurred in 5 (6.8%) and 11 patients (14.9%), respectively, after DSRS. In 9 patients, DSRS was used as salvage for failed transjugular intrahepatic portosystemic shunt.

Conclusions: Distal splenorenal shunt is a safe, durable, and effective treatment for controlling recurrent variceal hemorrhage in patients with acceptable operative risk and good liver function. It does not compromise future liver transplantation and can considerably delay the time until transplantation is required. Given the early occlusion rate and need for constant surveillance, transjugular intrahepatic portosystemic shunting should be reserved for patients with Child C classification cirrhosis with chronic hemorrhage or intractable ascites or as an emergency procedure for patients with uncontrollable bleeding using endoscopic therapy.

Arch Surg. 1999;134:416-420

TREATMENT OPTIONS for the patient with variceal bleeding and portal hypertension have changed dramatically during the past decade. Historically, medical therapy, balloon tamponade, and emergency portal decompression procedures were the mainstay of treatment for the patient with refractory variceal bleeding but were associated with significant morbidity and mortality.¹⁻⁴ Refinements in endoscopic sclerotherapy and pharmacological intervention led to an increasing number of patients successfully treated without the need for emergency surgical shunt procedures.^{5,6}

More recently, the development of transjugular intrahepatic portosystemic shunting (TIPS) has added substantially to the armamentarium of therapeutic options for patients with complications of chronic liver disease. Transjugular intrahepatic portosystemic shunting has demonstrated efficacy as an emergency mo-

dality for the patient with refractory variceal bleeding, or as the primary therapy for the patient in whom operative risk is considered poor. The use of TIPS is limited, however, by the need for constant surveillance, frequent revisions, and a high rate of early thrombosis.^{7,8}

See Invited Critique at end of article

For the patient with relative preservation of hepatic function and minimal ascites, selective portosystemic shunting still should be considered for the management of variceal bleeding when pharmacological therapy and sclerotherapy have failed.^{9,10} Although orthotopic liver transplantation (OLT) remains the definitive treatment for the patient with liver failure, many patients with portal hypertension and esophageal bleeding may not require OLT for many years.¹¹

From the Division of Hepatobiliary and Transplantation Surgery, Department of Surgery, Beth Israel Deaconess Medical Center, Harvard Medical School, Boston, Mass.

PATIENTS AND METHODS

From August 1, 1985, through October 31, 1997, DSRS was performed in 81 patients in the liver transplantation unit at the Beth Israel Deaconess Medical Center, Boston, Mass. Patient medical records were reviewed for demographics, cause of the liver disease, Child classification, indication for shunting, intraoperative blood loss, transfusion requirement, perioperative surgical complications, length of hospitalization, postoperative encephalopathy, and rebleeding rates. A group of 11 patients undergoing OLT subsequent to DSRS (DSRS was performed at the study center in 6 patients and at referring hospitals in 5) was compared with a group of 274 patients who underwent OLT only during the same interval. Thirty-day operative mortality and long-term survival rates were evaluated.

The primary indication for DSRS was recurrent variceal bleeding. In 9 patients, however, DSRS was used for salvage after TIPS and subsequent development of acute occlusion and rebleeding (**Figure 1**).

Seven of 81 patients were unavailable for follow-up and were excluded from statistical analysis. Of the 74 patients in whom complete data were available, Child classification was A in 57 (77%) and B in 17 (23%) at the time of surgery. Endoscopy showed esophageal varices alone in 52 patients (70%) and esophageal and gastric varices in 22 (30%). Primary sclerotherapy was performed in all patients to control initial bleeding episodes. In cases of medical failure with recurrent hemorrhage refractory to sclerotherapy, TIPS or DSRS was considered. Distal splenorenal shunting was performed only in patients with Child A or B classification. Patients were selected for transplantation based on the development of end-stage liver failure in accordance to guidelines promulgated by the United Network for Organ Sharing.¹⁴

Unless otherwise indicated, all data are presented as mean \pm SEM. Continuous data were compared using Student *t* test. Thirty-day survival data were compared using χ^2 test. Statistical significance was set at $P < .05$ in all cases. Survival data were calculated using the Kaplan-Meier product-limit method.

Each year the number of patients waiting for liver transplants increases, yet the number of available organs from suitable donors remains relatively unchanged.¹² This places a premium on the development of strategies for treating patients with portal hypertension to delay the need for transplantation. The goal should be to maintain the functional reserve of the remaining liver while minimizing recurrent bleeding without compromising the ability to perform a remedial transplantation. The distal splenorenal shunt (DSRS) procedure developed by Warren et al¹³ in 1967 fulfills these criteria.

In this study, we review a single center's experience in performing DSRS during a 12-year period in a single institution with an active liver transplantation program. We explore the utility of DSRS in the manage-

ment of recurrent variceal bleeding, outcome analysis, and impact on subsequent OLT.

RESULTS

Fifty-two men (64%) and 29 women (36%) had a mean age of 56.9 ± 1.2 years (range, 35-88 years) at the time of surgery. The primary causes of portal hypertension and variceal bleeding are summarized in the following tabulation:

Cause	No. (%) of Patients
Alcohol	34 (42)
Cryptogenic liver disease	15 (18)
Hepatitis C	11 (14)
Primary sclerosing cholangitis	8 (10)
Primary biliary cirrhosis	4 (5)
Hepatitis B	3 (4)
Autoimmune hepatitis	3 (4)
Portal vein thrombosis	1 (1)
Budd-Chiari syndrome	1 (1)
Hemochromatosis	1 (1)
Total	81 (100)

Hepatitis C disease assumed increasing importance in later years and undoubtedly contributed to cirrhosis in patients with cryptogenic or alcoholic liver disease before serologic markers became routinely available.

Hospital course is summarized in the following tabulation:

Factor	Mean \pm SEM (Range)
Operative time, h	5.68 ± 0.12 (2.75-8.00)
Estimated blood loss, mL	1209 ± 176 (100-5000)
Packed red blood cells, U	2.1 ± 0.3 (0-15)
Length of hospital stay, d	16.1 ± 1.8 (4-71)

Perioperative and long-term complications are summarized in **Table 1**. Most complications developed during the perioperative phase and required observation or short-term treatment. Operative 30-day mortality was 6% ($n = 5$). Child classification in 3 of these patients was A; in 2, B. Causes of death included adult respiratory distress syndrome and multiple organ failure ($n = 2$), coagulopathy and uncontrolled bleeding ($n = 2$), and cardiac arrhythmia ($n = 1$). Of particular note is the finding that thrombosis of the portal vein developed within the first week of surgery in 5 patients, contributing to delay in resolution of postoperative ascites in all. Three of these 5 patients have subsequently required OLT. One of these patients required an iliac vein graft to reconstruct the portal vein, whereas the other 2 underwent thrombectomy and standard anastomosis.

Long-term complications included recurrent variceal bleeding and hepatic encephalopathy, which occurred in 6.8% ($n = 5$) and 14.9% ($n = 11$) of patients, respectively. These data reflect occurrences throughout a mean survival time of 6.5 years. **Figure 2** shows the Kaplan-Meier survival curve for all patients who underwent successful DSRS. The 1- and 5-year survival rates were 86.4% ($n = 64$) and 74.3% ($n = 55$), respectively.

During the study, 11 patients underwent OLT a median of 5.1 years following DSRS (range, 0.4-10.1 years). We compared these patients with 274 patients who underwent OLT during the same period without any pre-existing shunt. The relative impact of previous DSRS on operative outcome of OLT is shown in **Table 2**. There was no significant statistical impact on duration of sur-

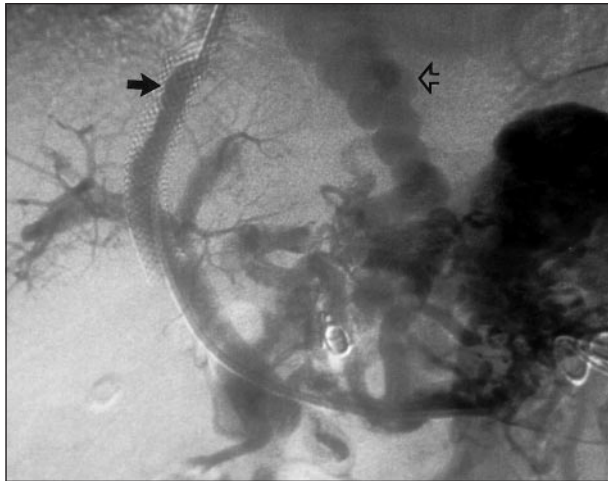


Figure 1. Angiographic study in patient presenting with third variceal bleed following transjugular intrahepatic portosystemic shunting. Large varices remain despite placement of multiple coils (open arrow). Laminated thrombus is visible within lumen of stent. Distal splenorenal shunting was performed subsequently (solid arrow).

Table 1. Early and Late Postoperative Complications*

Complications	No. of Patients
Perioperative	
Abdominal	
Portal vein thrombosis	5
Pancreatitis	2
Ascites requiring readmission	2
Retroperitoneal bleeding	1†
Variceal bleeding	1†
Pancreatic pseudocyst	1
Adynamic ileus	1
Cardiopulmonary	
ARDS and MOF	2†
Nonfatal arrhythmia	1
Fatal arrhythmia	1†
Aspiration	1
Pneumonia	1
Wound infection	2
Renal	
Urinary tract infection	2
Renal	1
Late complications	
Hepatic encephalopathy	11
Recurrent variceal bleeding	4

*ARDS indicates adult respiratory distress syndrome; MOF, multiple organ failure. Thirty-four of 81 patients had at least 1 complication, for a perioperative morbidity rate of 42%. Perioperative complications are defined as those within 30 days of surgery. Late complications are those after 30 postoperative days and represent occurrences throughout a mean follow-up of 6.5 years. One patient had recurrent variceal bleeding after surgery and died. Encephalopathy developed in 15 of 74 patients.

†Indicates patients who died (perioperative mortality, 6%).

gery, use of blood products, or 30-day operative mortality. The DSRS was ligated after hepatic revascularization in 5 patients, and was left intact in the remaining 6.

COMMENT

Management of portal hypertension and variceal bleeding is complicated by the variable degree of hepatic syn-

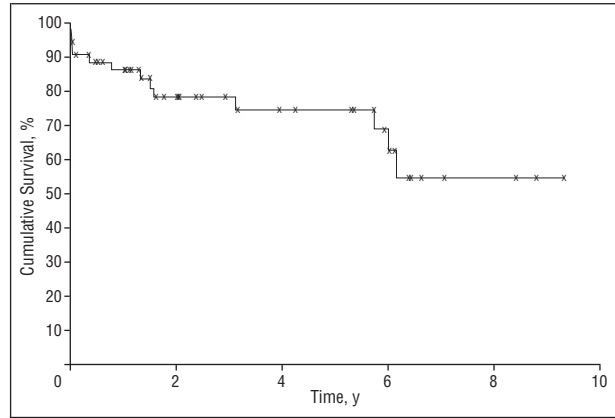


Figure 2. Survival curve after distal splenorenal shunting. Patients were observed for a mean of 6.5 years and censored according to Kaplan-Meier methods. The 1- and 5-year survival rates were 86.0% and 74.2%, respectively.

Table 2. Liver Transplant Outcome After DSRS vs No Previous Shunt*

Group†	Mean ± SD			30-Day Mortality, %
	Operative Time, h	PRBC, U	FFP, U	
DSRS	7.4 ± 2.5	12.0 ± 8.6	14.1 ± 10.7	0
No-shunt	6.5 ± 2.0	17.4 ± 15.6	18.9 ± 15.9	12

*Mortality was not significant using χ^2 analysis. Operative variables were not significant by Student *t* test. No-shunt group represents 274 patients undergoing liver transplantation during the same period. DSRS indicates distal splenorenal shunt; PRBC, packed red blood cells; and FFP, fresh frozen plasma.

†Described in the "Results" section.

thetic disruption by a diverse group of chronic liver diseases and the number of treatment options available. For the patient with recurrent variceal hemorrhage but adequate hepatic function, controversy exists as to the best method of prophylaxis against future bleeding.^{1,15,16} In patients with unsuccessful pharmacological and endoscopic control of variceal bleeding, TIPS has evolved recently as a relatively convenient treatment modality, and in many institutions its use is not restricted to patients with poor hepatic reserve. Emerging data suggest the frequent need for TIPS revision for stenosis or thrombosis within the first 1 to 2 years (20%-50%) and the potential for life-threatening complications.^{7,17-22} These observations should temper enthusiasm for the use of TIPS in good-risk patients who have the potential for long-term survival once portal hypertension is controlled. Properly used, TIPS should play its pivotal role in the treatment of patients with recurrent variceal hemorrhage who are not candidates for transplantation, in bleeding patients desperately awaiting liver replacement, and in selected patients with intractable ascites.²³

Whereas liver transplantation offers the best long-term solution to portal hypertension, end-stage liver failure may not develop for many years in many patients after their first bleeding episode. Therefore, any treatment option to control variceal hemorrhage should reduce the incidence of bleeding, maintain hepatic reserve, and remain durable for years.

There are several advantages to a selective DSRS over other selective and nonselective shunts in controlling variceal bleeding. First, selective decompression of gastroesophageal varices via the splenic circulation maintains prograde portal flow into the liver while effectively decompressing esophageal and gastric varices.²⁴ Maintenance of portal flow may better preserve the delivery of hepatotropic factors that, in turn, are responsible for preservation of hepatic architecture and function.²⁵ Second, DSRS avoids extensive hepatic hilar mobilization, which might significantly complicate any future transplantation effort. Some caution in the use of DSRS is suggested by the low incidence of postoperative portal vein thrombosis, which occurred in 5 of our patients. Although recanalization of the portal vein may occur during several months, complete or partial thrombosis of the portal vein adds complexity to a subsequent liver transplantation.^{26,27}

Our study confirms that DSRS can be performed in select patients with low operative mortality and a 6.8% rate of rebleeding during a mean follow-up of 6.5 years. Encephalopathy, which occurs frequently after nonselective shunts such as portocaval shunts and TIPS, occurred in only 14.9% of our patients during follow-up and was readily managed by dietary restriction and lactulose.^{28,29} In patients with DSRS undergoing later transplantation, adhesions may increase the technical difficulties of recipient hepatectomy, but operative times, use of blood products, and survival rates are equivalent to those of the population undergoing liver transplantation as the primary treatment.

Our present algorithm for the management of variceal hemorrhage uses most of the available treatment options, with an emphasis on the immediate identification of patients who are anticipated to need urgent or late transplantation. Octreotide infusion and endoscopic sclerotherapy or banding is used initially in all patients presenting with variceal bleeding. Patients with Child A classification and in whom endoscopic variceal control fails are offered DSRS surgery in anticipation that they will not need transplantation for a prolonged period. Attempts are made to optimize patients with Child B classification who may then also be candidates for DSRS. Patients with Child C classification who are poor candidates for transplantation and patients actively waiting on the transplant list with uncontrollable bleeding are offered TIPS. Surgical portocaval shunts are restricted to rare patients in whom TIPS or DSRS fails or patients with salvageable Budd-Chiari syndrome.³⁰

Given the long waiting times on many transplant lists, evaluation for potential liver transplantation should be instituted early in the patient's clinical course. Patients with chronic liver failure who are referred near the end of their disease process often will not survive the waiting period before a donor organ becomes available.

Distal splenorenal shunting continues to be a safe and effective procedure for controlling recurrent variceal hemorrhage and should be the treatment of choice for patients with acceptable operative risk and good liver function. It also serves as an excellent salvage procedure for patients with favorable Child classification in whom injudiciously placed TIPS fail. Furthermore, DSRS is a du-

table bridge to transplantation, with a greater than 5-year interval between surgical decompression and OLT in our series.

Presented at the 79th Annual Meeting of the New England Surgical Society, Toronto, Ontario, September 25, 1998.

Corresponding author: Roger L. Jenkins, MD, Division of Hepatobiliary and Transplantation Surgery, Beth Israel Deaconess Medical Center, 110 Francis St, Suite 8C, Boston, MA 02215 (e-mail: rjenkins@caregroup.harvard.edu).

REFERENCES

- Henderson JM. Portal hypertension and shunt surgery. *Adv Surg.* 1993;26:233-257.
- Orloff MJ, Orloff MS, Orloff SL, Rambotti M, Girard B. Three decades of experience with emergency portacaval shunt for acutely bleeding esophageal varices in 400 unselected patients with cirrhosis of the liver. *J Am Coll Surg.* 1995;180:257-272.
- Spina GP, Henderson JM, Rikkers LF, et al. Distal spleno-renal shunt versus endoscopic sclerotherapy in the prevention of variceal rebleeding: a meta-analysis of 4 randomized clinical trials. *J Hepatol.* 1992;16:338-345.
- Rikkers LF, Jin G. Emergency shunt: role in the present management of variceal bleeding. *Arch Surg.* 1995;130:472-477.
- Besson I, Ingrand P, Person B, et al. Sclerotherapy with or without octreotide for acute variceal bleeding. *N Engl J Med.* 1995;333:555-560.
- Conn HO, Lebrech D, Terblanche J. The treatment of oesophageal varices: a debate and a discussion. *J Intern Med.* 1997;241:103-108.
- Rossle M, Siegerstetter V, Huber M, Ochs A. The first decade of the transjugular intrahepatic portosystemic shunt (TIPS): state of the art. *Liver.* 1998;18:73-89.
- Rosemurgy AS II, Bloomston M, Zervos EE, et al. Transjugular intrahepatic portosystemic shunt versus H-graft portacaval shunt in the management of bleeding varices: a cost-benefit analysis. *Surgery.* 1997;122:794-800.
- Abouljoud MS, Levy MF, Rees CR, et al. A comparison of treatment with transjugular intrahepatic portosystemic shunt or distal splenorenal shunt in the management of variceal bleeding prior to liver transplantation. *Transplantation.* 1995;59:226-229.
- Mercado MA, Morales-Linares JC, Granados-Garcia J, et al. Distal splenorenal shunt versus 10-mm low-diameter mesocaval shunt for variceal hemorrhage. *Am J Surg.* 1996;171:591-595.
- Hermann RE, Henderson JM, Vogt DP, Mayes JT, Geisinger MA, Agnor C. Fifty years of surgery for portal hypertension at the Cleveland Clinic Foundation: lessons and prospects. *Ann Surg.* 1995;221:459-468.
- Harper AM, Rosendale JD. The UNOS OPTN waiting list and donor registry: 1988-1996. In: Cecka JM, Terasaki P, eds. *Clinical Transplants.* Los Angeles, Calif: UCLA Tissue Typing Laboratory; 1996:69-90.
- Warren WD, Zeppa R, Fomon JJ. Selective trans-splenic decompression of gastroesophageal varices by distal splenorenal shunt. *Ann Surg.* 1967;166:437-455.
- Blumstein JF. Government's role in organ transplantation policy. *J Health Polit Policy Law.* 1989;14:5-39.
- Rees CJ, Hudson M, Record CO. Therapeutic modalities in portal hypertension. *Eur J Gastroenterol Hepatol.* 1997;9:9-11.
- Navarro VJ, Garcia-Tsao G. Variceal hemorrhage. *Crit Care Clin.* 1995;11:391-414.
- Kerlan RK Jr, LaBerge JM, Gordon RL, Ring EJ. Transjugular intrahepatic portosystemic shunts: current status. *AJR Am J Roentgenol.* 1995;164:1059-1066.
- Sanyal AJ, Freedman AM, Luketic VA, et al. The natural history of portal hypertension after transjugular intrahepatic portosystemic shunts. *Gastroenterology.* 1997;112:889-898.
- Sanyal AJ, Freedman AM, Luketic VA, et al. Transjugular intrahepatic portosystemic shunts compared with endoscopic sclerotherapy for the prevention of recurrent variceal hemorrhage: a randomized controlled trial. *Ann Intern Med.* 1997;126:849-857.
- Cosenza CA, Hoffman AL, Friedman ML, et al. Transjugular intrahepatic portosystemic shunt: efficacy for the treatment of portal hypertension and impact on liver transplantation. *Am Surg.* 1996;62:835-839.
- LaBerge JM, Somberg KA, Lake JR, et al. Two-year outcome following transjugular intrahepatic portosystemic shunt for variceal bleeding: results in 90 patients. *Gastroenterology.* 1995;108:1143-1151.

22. Foshager MC, Ferral H, Nazarian GK, Castaneda-Zuniga WR, Letourneau JG. Duplex sonography after transjugular intrahepatic portosystemic shunts (TIPS): normal hemodynamic findings and efficacy in predicting shunt patency and stenosis. *AJR Am J Roentgenol.* 1995;165:1-7.
23. Bataller R, Arroyo V, Gines P. Management of ascites in cirrhosis. *J Gastroenterol Hepatol.* 1997;12:723-733.
24. Rikkens LF, Jin G, Langnas AN, Shaw BW Jr. Shunt surgery during the era of liver transplantation. *Ann Surg.* 1997;226:51-57.
25. Starzl TE, Porter KA, Kashiwagi N. Portal hepatotrophic factors, diabetes mellitus and acute liver atrophy, hypertrophy and regeneration. *Surg Gynecol Obstet.* 1975;141:843-858.
26. Lerut JP, Mazza D, van Leeuw V, et al. Adult liver transplantation and abnormalities of splanchnic veins: experience in 53 patients. *Transpl Int.* 1997;10:125-132.
27. Langnas AN, Marujo WC, Stratta RJ, et al. A selective approach to preexisting portal vein thrombosis in patients undergoing liver transplantation. *Am J Surg.* 1992;163:132-136.
28. Pomier-Layrargues G. TIPS and hepatic encephalopathy. *Semin Liver Dis.* 1996; 16:315-320.
29. Riggio O, Merli M, Pedretti G, et al. Hepatic encephalopathy after transjugular intrahepatic portosystemic shunt: incidence and risk factors. *Dig Dis Sci.* 1996; 41:578-584.
30. Hemming AW, Langer B, Greig P, et al. Treatment of Budd-Chiari syndrome with portosystemic shunt or liver transplantation. *Am J Surg.* 1996;171:176-180.

Invited Critique

The article by Jenkins et al reports a single center's experience with distal splenorenal shunt (DSRS) over a 12-year period. It helps to define the effect of shunt surgery in the overall scheme of management of patients with portal hypertension, variceal bleeding, and liver disease. The authors define which patients have been selected for shunts, what outcomes have been achieved, and where DSRS fits in the scheme of endoscopic therapy, transjugular intrahepatic portosystemic shunt (TIPS), and transplantations.

Child class A and B patients with recurrent variceal bleeding were candidates for DSRS, and as reported in other surgical series, the authors achieved a low operative mortality rate (6.2%) and good long-term survival rates, 86% at 1 year and 74% at 5 years. The rebleeding rate was 6.8%, the encephalopathy rate was 14.9%, and the transplantation rate was 13.6%, with a median follow-up time of approximately 5 years, indicating what can be achieved in a highly selected group of patients.

Eleven of their 81 patients underwent orthotopic liver transplantation (OLT), and the data presented support the current literature indicating that patients with DSRS who undergo OLT are at no disadvantage. Operative time, blood loss, and early mortality are not significantly different from those in the transplantation population as a whole. The fact that only 13.6% of their DSRS population needed OLT over 5 years indicates that this operation did not accelerate this group's need for OLT.

An interesting aside is the number of patients who required surgical rescue for TIPS thrombosis. Nine of the 81 DSRS patients fell into this category, but unfortunately, we do not have the total number of TIPS procedures performed during this time. The lesson learned is that DSRS can be successfully achieved when TIPS has failed, and failed TIPS does not necessarily lead to a need for OLT.

Where does this leave us in the use of DSRS? This group has documented that a "Hepatobiliary Surgery and Transplant Unit"—as they define themselves—can and should have this surgical option available as part of their repertoire. As Jenkins et al point out, it is important that the full breadth of options be available to patients, and liver transplant surgeons should provide this expertise for appropriately selected patients.

*J. Michael Henderson, MD
Cleveland, Ohio*