

# Regular Scintigraphic Measurements of Food Transit Following Different Types of Reconstruction After Total Gastrectomy

Beatrix Hokschi, MD; Hans-Udo Zieren, MD; Joachim M. Müller, MD, FACS

**Hypothesis:** Ideal reconstruction after gastrectomy should ensure that the patient has a sufficiently large enteric reservoir to accommodate normal meals. Little is known about the transit of food after different methods of stomach reconstruction. The hypothesis of this trial was that food transit after gastrectomy is delayed by a pouch reconstruction compared with reconstructions without a pouch.

**Design:** Prospective.

**Setting:** University hospital.

**Patients and Methods:** A total of 27 patients underwent an interposition of a jejunal loop between the esophagus and the duodenum with (n = 19) or without (n = 8) a 7- or 15-cm proximal pouch reconstruction. Standardized scintigraphic measurements were performed to evaluate the food transit at fixed postoperative times.

**Main Outcome Measure:** Scintigraphically measured food transit time.

**Results:** The food transit time 1 year postoperatively was significantly prolonged in patients with the 15-cm pouch in comparison with those with the 7-cm pouch and those without a pouch reconstruction ( $P = .005$ ,  $P = .012$ ). Patients with a pouch reconstruction tended to have better eating habits.

**Conclusions:** Our results confirm the hypothesis and suggest that interposition of a large 15-cm jejunal pouch can lead to a prolonged food transit time with enteric reservoir function resulting in better patient nutritional status.

*Arch Surg.* 1999;134:1270-1273

**P**OSTPRANDIAL discomfort and malnutrition are common problems for patients after total gastrectomy. Since Schlatter performed the first successful total gastrectomy in 1897, numerous types of gastric replacements with various enteric reservoirs have been applied in an effort to improve symptoms and the nutritional status of patients following gastrectomy. The construction of a gastric substitute pouch has been proposed to ameliorate postprandial symptoms. The preservation of the duodenal passage—in contrast to the Roux-en-Y anastomosis—should result in better physiological enrichment of the chyme with bile and pancreatic juice and better physiological regulation of gastrointestinal hormones. The optimal pouch size and the functional effects of the jejunal pouch (JP) have not yet been determined.<sup>1-9</sup> Additionally, there is little known about food transit after different modes of reconstruction for gastrectomy.

Moreover, the development of the enteric reservoir, or “pouch,” function of gastric replacement has not yet been objectively compared with a jejunal segment interposition without a pouch. For this reason we evaluated the enteric reservoir function of a pouch reconstruction following a total gastrectomy by examining scintigraphic findings of the intestinal transit of a test meal. These results were compared with the development of body weight and food consumption patterns postoperatively.

## RESULTS

### SCINTIGRAPHIC MEASUREMENTS

Two weeks postoperatively, the mean half-emptying time in the JIP group was shorter than the times in the JIPP 7 cm and the JIPP 15 cm groups ( $P = .005$ , JIP vs JIPP 7 cm;  $P = .012$ , JIPP 7 cm vs JIPP 15 cm). While the food transit time for the JIP group remained constant for the initial 6

From the University Department of Surgery, Charité (Campus Mitte), Humboldt-University, Berlin, Germany.

## PATIENTS, MATERIALS, AND METHODS

From 1995 to April 1997, 27 patients in the Department of Surgery of the Charité, Humboldt-University, Berlin, Germany, were enrolled in the study after undergoing total gastrectomy owing to gastric cancer. After resection and D2-lymphadenectomy under curative intention (R0-resection), the patients were randomized intraoperatively to 1 of 3 different types of reconstructions: (1) esophagoduodenal interposition of a 40-cm isoperistaltic jejunal segment without a JP (jejunal interposition without pouch [JIP] group) (n = 8); (2) esophagoduodenal interposition of a 47-cm isoperistaltic jejunal segment with a proximal 7-cm JP (JIP with a 7-cm pouch [JIPP 7 cm] group) (n = 10); (3) and esophagoduodenal interposition of a 55-cm isoperistaltic jejunal segment with a proximal JP of 15 cm (JIP with a 15-cm pouch [JIPP 15 cm] group) (n = 9) (**Figure**).

The anastomoses between the esophagus and the jejunal loop and the jejunal loop and the duodenum were performed with a circular stapler (CEEA 25 Auto-Suture; United States Surgical Corp, Norwalk, Conn). The pouch itself was constructed using a GIA-60 stapler (Auto-Suture; United States Surgical Corp). The 3 groups were homogeneous regarding age, sex, and tumor stage (**Table 1**). The median operating time was 210 minutes (range, 122-335 minutes).

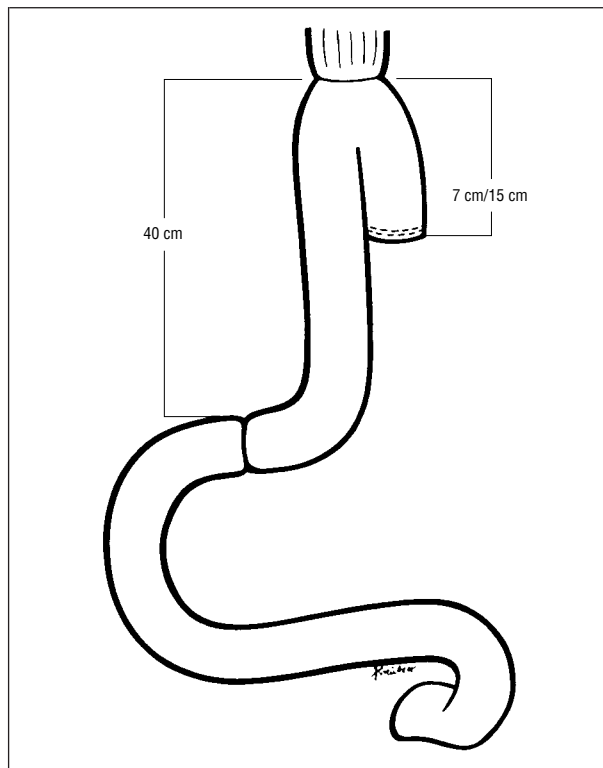
### SCINTIGRAPHIC MEASUREMENTS

Scintigraphy was performed in a standardized fashion: following an overnight fast, the patients consumed 60 mL of rice pudding labeled with technetium Tc 99m within 3 minutes. Each patient was placed in front of a gamma camera in a seated position, and the radioactivity was measured in the region of interest. The region of interest was defined as the area between the proximal and distal anastomosis of the interposed jejunal segment, which was marked by a pen on the skin after an x-ray film was taken of the segment. In each patient the half-emptying time was measured. Scintigraphic examinations were accomplished after preestablished postoperative periods of 14 days and 3, 6, and 12 months.

### BODY WEIGHT AND FOOD CONSUMPTION PATTERNS

In all groups body weight was measured at the time of scintigraphy. At each follow-up visit, the patients were questioned about their food habits using a special questionnaire module. These questions addressed the number and quantity of meals consumed and changes in dietary restrictions. All data were recorded with a score from 1 to 4 (1, satisfactory, no problems; 2, minor problems; 3, moderate problems; 4, major problems).

The level of significance was defined as  $P < .05$ ; for statistical tests, the Kruskal-Wallis, Mann-Whitney test, and the Wilcoxon rank sum test were used. Approval of the investigations had been given by the Ethics Commission of Humboldt-University.



Esophagoduodenal interposition of an isoperistaltic jejunal segment with pouch reconstructions of different sizes.

**Table 1. Information on Patients Undergoing Total Gastrectomy\***

Parameter	Patients Grouped by Operative Procedure (N = 27)		
	JIP	JIPP 7 cm	JIPP 15 cm
Age, y (range)	63.5 (45-74)	59.8 (26-71)	62.3 (43-73)
Sex			
M/F	5/3	4/6	5/4
Tumor stage, UICC			
I + II	6	7	6
III + IV	2	3	3

\*JIP indicates jejunal interposition without pouch; JIPP 7 cm, jejunal interposition with 7-cm pouch; JIPP 15 cm, jejunal interposition with 15-cm pouch; and UICC, International Union Against Cancer.

months, the half-emptying time increased in both pouch groups. Twelve months postoperatively, the JIPP 15 cm group had a significantly prolonged scintigraphically measured food transit time compared with the JIPP 7 cm and the JIP groups (**Table 2**).

### BODY WEIGHT

In all groups the body weight (percentage of preoperative weight) decreased until 6 months postoperatively. In the JIPP 15 cm group, body weight was clearly regained after 12 months. The JIPP 15 cm group nearly achieved their preoperative body weight after 1 year (**Table 3**).

**Table 2. Scintigraphy Measurements for Patients Following Reconstruction After Total Gastrectomy\***

Postoperative Measurement	Half-Emptying Time, min		
	JIP	JIPP 7 cm	JIPP 15 cm
14 d†	15.2 ± 9.8	29.1 ± 16.4	78.1 ± 52.8
3 mo	12.9 ± 7.6	42.4 ± 24.0	52.3 ± 30.8
6 mo‡	15.2 ± 10.4	49.7 ± 39.5	69.1 ± 49.0
12 mo‡	23.3 ± 18.2	27.3 ± 20.4	83.6 ± 32.4

\*JIP indicates jejunal interposition without pouch; JIPP 7 cm, jejunal interposition with 7-cm pouch; and JIPP 15 cm, jejunal interposition with 15-cm pouch. All values are given as mean ± SD.

†Significance ( $P < .05$ ) was seen between all 3 groups at 14 days postoperatively (JIP vs JIPP 7 cm,  $P = .048$ ; JIP vs JIPP 15 cm,  $P = .009$ ; JIPP 7 cm vs JIPP 15 cm,  $P = .04$ ).

‡No significance was seen between the JIP group and the JIP 7 cm group at 6 ( $P = .55$ ) and 12 ( $P = .38$ ) months postoperatively.

**Table 3. Development of Body Weight in Patients Following Reconstruction After Total Gastrectomy\***

Postoperative Measurement	JIP	JIPP 7 cm	JIPP 15 cm
14 d	95	94	95
3 mo	87	88	87
6 mo	81	84	87
12 mo	82	86	92

\*JIP indicates jejunal interposition without pouch; JIPP 7 cm, jejunal interposition with 7-cm pouch; and JIPP 15 cm, jejunal interposition with 15-cm pouch. All values are given as percentages.

## FOOD CONSUMPTION PATTERNS

In all groups the food consumption patterns changed postoperatively. The JIPP 15 cm group tended to have a better recovery to normal dietary patterns (4-5 meals of normal quantity per day) (**Table 4**).

### COMMENT

The best type of reconstruction after total gastrectomy remains controversial.<sup>7,10-14</sup> Because postprandial discomfort and malnutrition are common problems for patients following gastrectomy, the aim of all of the types of gastric replacements with various enteric reservoirs is improvement in the patient's quality of life. The construction of a substitute gastric pouch has been proposed by some authors as a means of ameliorating postprandial symptoms and enhancing nutritional intake.<sup>5,13-15</sup> The optimal pouch size and the functional effects of the JP have not yet been determined. To maintain the transit of food duodenally, some surgeons prefer the Longmire procedure with interposition of a jejunal segment between the esophagus and the duodenum.<sup>8,9,16,17</sup>

Examinations to evaluate food transit after different types of reconstruction following a total gastrectomy are difficult to reproduce. Radiographic tests conducted after patient ingestion of a barium meal (liquid barium, barium enteric-coated granules, or a barium burger) are not quantitative, and the barium is unsuitable for a quantitative evaluation because the weight of

**Table 4. Changes and Problems in Food Consumption Patterns in Patients Following Reconstruction After Total Gastrectomy\***

Postoperative Measurement	JIP	JIPP 7 cm	JIPP 15 cm
14 d	3.4	3.7	3.7
3 mo	3.2	3.0	3.1
6 mo	3.3	3.4	3.1
12 mo	3.3	2.8	2.0

\*JIP indicates jejunal interposition without pouch; JIPP 7 cm, jejunal interposition with 7-cm pouch; and JIPP 15 cm, jejunal interposition with 15-cm pouch. Changes and problems values were scored as follows: 1, no problems; 2, mild problems; 3, moderate problems; and 4, major problems.

the contrast medium is higher than that of normal food.<sup>18</sup> The most sensitive technique for determining abnormalities of gastric emptying is to use the gamma-emitting radionuclide <sup>99m</sup>Tc-test meal, which enables tight binding to occur between the radioactive tracer and solid food.<sup>18</sup> Isotopic methods were also used because they involve less radiation exposure for the patient compared with fluoroscopy and are well accepted by the patient.<sup>12,15,18-20</sup> To our knowledge, all published studies that evaluate food transit after gastrectomy and reconstruction with a JP refer to only 1 postoperative measurement, mostly taken 1 year postoperatively. No reliable continuous data exist analyzing the functional development of a gastric reservoir after pouch reconstruction over a period of time. Furthermore, to our knowledge, in all previous studies, different barium meals or radioactively labeled meals have been used for radiographic determinations, for instance rice, eggs, beef, or cake.<sup>16,18-20</sup>

Only a limited comparison between the results of various studies is possible. Takeshita et al<sup>12</sup> described the pouch examination with a barium meal and radiopaque markers. The authors revealed favorable retention of the barium meal in the JP and satisfactory bowel motility, as measured by the percentage of radiopaque markers that were expelled from the pouch. However, these examinations were performed only once—6 months or longer—postoperatively.

The scintigraphic examination results of our trial demonstrate the development of a possible enteric reservoir function of the JIPP 15 cm beginning after the sixth postoperative month. In the JIPP 7 cm and JIP groups, only a small or no enteric reservoir function was shown in the scintigraphic measurements compared with the JIPP 15 cm group. The findings of our trial support the results of Tanaka et al.<sup>21</sup> Their studies suggest that differences in JP length—even of only 5 cm—might play a role in postoperative food consumption patterns and thus influence postoperative symptoms and metabolism of patients who underwent gastrectomy.<sup>14,16,20</sup> The patients in the JIPP 7 cm group showed a decreased half-emptying time after 1 year compared with the examinations conducted 3 and 6 months postoperatively. This fact may be explained by disturbances of emptying of the interposed jejunal loop the first time postoperatively. Special measurements like manometry could be helpful in answering this question.

The scintigraphic measurements are not completely without mistakes and depend on many physiological alterations. This is a possible explanation of the great amount of SD in the different groups of our trial. Nakane et al<sup>20</sup> described different types of emptying patterns after pouch reconstruction: delayed, intermediate, and rapid type. Stier et al<sup>22</sup> reported that the emptying rate of a JP is delayed compared with that of patients with a normal stomach. In contrast, Pellegrini et al<sup>23</sup> described a slower bowel transit by a Roux-en-Y esophagojejunal anastomosis in patients who underwent total gastrectomy compared with normal controls.

Sufficient food intake is fundamental for patients who have undergone gastrectomy.<sup>13</sup> In our trial, patients in the JIPP 15 cm group are the only ones who nearly achieved their preoperative food consumption patterns (normal amount of meals, 4-5 per day). This was especially so for those patients with a large pouch who came close to their preoperative body weight after 1 year and had only minor nutritional problems, indicating that a smaller pouch (7 cm) does not suffice. In their study Troidl et al<sup>13</sup> described the development of food intake after gastrectomy and the recovery of the patients with a Hunt-Lawrence Rodino pouch compared with a Roux-en-Y reconstruction 6 months postoperatively. Patients who underwent a Roux-en-Y reconstruction did not exceed half of the preoperative food intake on average in contrast to patients with a pouch reconstruction. In the results of our trial, the better clinical outcome of the patients who underwent a large pouch reconstruction seems to be explained by the development of the pouch reservoir 6 months postoperatively. A large pouch can be assumed to considerably support the patient's nutritional needs after total gastrectomy.

This leads to the question, in which case should a pouch reconstruction be considered? Because an enteric reservoir function will show no significant yield before the sixth postoperative month, the chances of survival for the patient should be at least 1 year from the time of diagnosis. Only patients with a postoperative prognosis of at least 1 year will profit from an improved quality of life.<sup>13</sup> If the resection is considered to be palliative treatment, then a simple reconstructive procedure, such as a Roux-en-Y or loop jejunostomy, is a sensible option.

## CONCLUSIONS

Jejunal interposition between the esophagus and the duodenum with a 15-cm pouch reconstruction can lead to a prolonged food transit time with enteric reservoir function. Whether the pouch reconstruction should be considered as the treatment of choice for reconstruction after total gastrectomy for patients who have a chance of surviving for at least 1 year must be studied further and include more examination into the quality of life.

We thank Noga E. Meiri for preparing the manuscript.

Corresponding author: Beatrix Hokschi, MD, University Department of Surgery, Charité, Humboldt-University, Schumannstrasse 20/21, D-10117 Berlin, Germany.

## REFERENCES

1. Beese G, Fuchs KH, Thiede A. Experimentelle Untersuchungen zur Wertigkeit des Pouches nach Gastrektomie. *Zentralbl Chir.* 1994;119:904-910.
2. Bittner R. Pouch reconstruction after total gastrectomy. *Dig Surg.* 1996;13:194-200.
3. Buhl K, Schlag P, Herfarth C. Quality of life and functional results following different types of resection for gastric cancer. *Euro J Surg Oncol.* 1990;16:404-409.
4. Buhl K, Lehnert T, Schlag P, Herfarth C. Reconstruction after gastrectomy and quality of life. *World J Surg.* 1995;19:558-564.
5. Cuschieri A. Jejunal pouch reconstruction after total gastrectomy for cancer: experience in 29 patients. *Br J Surg.* 1990;77:421-424.
6. Hays RP, Clark DA. Nutrition in patients with total gastrectomy and jejunal food pouch. *Ann Surg.* 1960;152:864-870.
7. Herfarth C, Schlag P, Buhl K. Surgical procedures for gastric substitution. *World J Surg.* 1987;11:689-698.
8. McCorkle HJ, Harper HA. The problem of nutrition following complete gastrectomy. *Ann Surg.* 1954;140:467-473.
9. Schmitz R, Moser KH, Treckmann J. Lebensqualität nach prograder Jejunuminterposition mit und ohne Pouch. *Chirurg.* 1994;65:326-332.
10. Fuchs K-H, Thiede A, Engemann R, Deltz E, Stremme O, Hamelmann H. Reconstruction of the food passage after total gastrectomy: randomized trial. *World J Surg.* 1995;19:698-706.
11. Korenaga D, Orita H, Okuyama T, Moriguchi S, Maehara Y, Sugimachi K. Quality of life after gastrectomy in patients with carcinoma of the stomach. *Br J Surg.* 1992;79:248-250.
12. Takeshita K, Saito N, Habu H, et al. Technical devices in jejunal pouch reconstruction following total gastrectomy, including postoperative results. *Hepatogastroenterology.* 1997;44:588-598.
13. Troidl H, Kusche J, Vestweber K-H, Eypasch E, Maul U. Pouch versus esophagojejunostomy after total gastrectomy: a randomized clinical trial. *World J Surg.* 1987;11:699-712.
14. Svedlund J, Sullivan M, Liedman B, Lundell L, Sjödin I. Quality of life after gastrectomy for gastric carcinoma: controlled study of reconstructive procedures. *World J Surg.* 1997;21:422-433.
15. Schwarz A, Büchler M, Usinger K, et al. Importance of the duodenal passage and pouch volume after total gastrectomy and reconstruction with the Ulm pouch: prospective randomized clinical study. *World J Surg.* 1996;20:60-67.
16. Nakane Y, Okumura S, Akehira K, et al. Jejunal pouch reconstruction after total gastrectomy for cancer. *Ann Surg.* 1995;222:27-35.
17. Tittel A, Schumpelick V. History of gastric replacement. *Hepatogastroenterology.* 1989;36:57-62.
18. McAleese P, Calvert H, Ferguson WR, Laird J. Evaluation of gastric emptying time in the J pouch compared with a standard esophagojejunal anastomosis. *World J Surg.* 1993;17:595-600.
19. Miholic J, Meyer HJ, Kotzerke J, et al. Emptying of the gastric substitute after total gastrectomy. *Ann Surg.* 1989;210:165-172.
20. Nakane Y, Akehira K, Okumura S, et al. Emptying of the jejunal pouch as a gastric substitute after total gastrectomy for cancer. *Hepatogastroenterology.* 1997;44:901-906.
21. Tanaka T, Kusunoki M, Fujiwara Y, Nakagawa K, Utsunomiya J. Jejunal pouch length influences metabolism after total gastrectomy. *Hepatogastroenterology.* 1997;44:891-896.
22. Stier A, Hölscher AH, Schwaiger M, Siewert JR. Jejunumpouch nach totaler Gastrektomie: Klinische und szintigrafische Untersuchungen zu Funktion und Befindlichkeit. *Zentralbl Chir.* 1994;119:838-884.
23. Pellegrini CA, Deveney CW, Patti MG, Lewin M, Way LW. Intestinal transit of food after total gastrectomy and Roux-en-y esophagojejunostomy. *Am J Surg.* 1986;151:117-124.