

Colostomy vs Tube Cecostomy for Protection of a Low Anastomosis in Rectal Cancer

Joerg Tschmelitsch, MD; Heinz Wykypiel, MD; Rupert Prommegger, MD; Ernst Bodner, MD

Background: Symptomatic anastomotic leakage is the most important surgical complication following rectal resection with intestinal anastomosis. Therefore, the routine use of a protective stoma is suggested by several authors. In our department 2 different techniques are performed to protect the anastomosis. Patients receive either a loop colostomy/ileostomy (C/I) or a tube cecostomy (TC).

Hypothesis: No significant difference is noted between C/I and TC for protection of a low anastomosis regarding clinical anastomotic leakage rate, reoperation rate for anastomotic leaks/fistulas, postoperative mortality, and permanent colostomy rate. By avoiding a second operation (for colostomy closure), median hospital stay should be significantly reduced.

Design: A retrospective review during 1985 to 1997.

Setting: Tertiary care center

Patients: One hundred fifty-eight patients who had undergone anterior resections for rectal cancer were studied. Protective C/Is were used in 19 patients; a TC was fashioned in 30 patients.

Main Outcome Measures: Clinical anastomotic leakage rate, reoperation rate for anastomotic leaks/fistulas, postoperative mortality, permanent colostomy rate, and median hospital stay.

Results: The rate of anastomotic leaks (C/I, 16%; TC, 17%), fecal peritonitis (C/I, 0%; TC, 10%), reoperation for anastomotic leaks/fistulas (C/I, 0%; TC, 13%), permanent colostomies (C/I, 0%; TC, 7%), and postoperative mortality (C/I, 5%; TC, 0%) did not differ significantly in both groups. Median hospital stay was significantly reduced in patients with TC (C/I, 28 days; TC, 15 days).

Conclusion: In our patients with low resections for rectal cancer, a C/I for protection of the anastomosis did not improve outcome significantly as compared with a TC. With a properly fashioned TC and adequate postoperative management a second operation (for colostomy closure) can be avoided and the overall hospital stay is significantly reduced.

Arch Surg. 1999;134:1385-1388

IN PATIENTS with rectal cancer a radical resection is the cornerstone of treatment. Symptomatic anastomotic leakage is the most important surgical complication following rectal resection with intestinal anastomosis. The clinical leakage rate after anterior resection varies from 1% to 19%.¹⁻⁵ The mortality rate and risk of permanent stoma after clinical leakage are 6% to 22%,⁶⁻¹³ and 10% to 100%, respectively.⁸⁻¹²

Fecal diversion seems to offer protection against the complications of anastomotic dehiscence. Proponents of the defunctioning colostomy maintain that it is impossible to predict which anastomosis will leak although the probability seems greatest for the lowest anastomoses,² after total mesorectal excision,⁴ and after

neoadjuvant radiochemotherapy.⁸ In these patients routine use of a protective stoma is suggested by several authors.^{1,2,4,5}

See Invited Critique at end of article

Concerns about the routine use of defunctioning colostomies are the morbidity and mortality associated with their closure^{10,14,15} and the prolonged overall hospitalization and convalescence.¹⁶

In our department 2 different techniques are performed for defunctioning anastomosis. Patients receive either a loop colostomy/ileostomy (C/I) or a tube cecostomy (TC).

The aim of this retrospective study was to review our results after C/I as com-

From the Department of Surgery, University of Innsbruck, Innsbruck, Austria.

PATIENTS AND METHODS

One hundred fifty-eight patients (94 men, 64 women; mean [SD] age, 66 [11] years) had anterior resections for rectal cancer performed in our department between 1985 and 1997. A C/I was used in 19 patients (group 1). A TC was fashioned in 30 patients (group 2). The technique used was at the surgeon's discretion. Anastomotic protection by either technique was performed on a selective basis where there was a particular concern about the anastomosis (eg, difficulty in dissection, incomplete doughnuts, or tension on the anastomosis).

Routine contrast enema was not performed after the operation. Anastomotic leakage was suspected if the patient had fever; leukocytosis; persistent ileus; gas, pus, or fecal discharge from the drain; pelvic abscess; or peritonitis. In these cases a water-soluble contrast enema was performed.

Patients and tumor characteristics, clinical anastomotic leak rates, reoperation rates, postoperative mortality, permanent colostomy rates, and median hospital stay were documented (**Table 1** and **Table 2**).

SURGICAL PROCEDURE

Resection and Anastomosis

The day before the operation, bowel lavage with 3 to 4 L of polyethylene glycol was carried out. All patients received perioperative antibiotic prophylaxis. A midline abdominal incision was performed. The inferior mesenteric artery was ligated at its origin either flush with the aorta or just below the ascending left colic artery. The descending colon and the splenic flexure were mobilized in most low anterior resections to achieve anastomosis without tension. The sigmoid colon was transected. The mesorectum and the lateral perirectal tissue were removed with the specimen, and a distal margin of clearance of at least 1.5 cm was always obtained.

Anastomoses were either hand sewn or stapled.

For stapled anastomoses the double-stapling technique was performed.

A linear stapler was used to divide the distal rectum (Autosuture TA 55; US Surgical Corp, Norwalk, Conn; or RL60; Ethicon, Somerville, NJ). A purse-string suture was placed in the proximal segment, and the anastomosis was completed by passing the circular stapler per anum. The end-to-end anastomosis (US Surgical Corp), Premium curved end-to-end anastomosis (US Surgical Corp), or intraluminal (Ethicon) staplers were used for circular stapling. The tissue doughnuts were carefully inspected for completeness.

Hand-sewn anastomoses were carried out using interrupted 3-0 polyglactin sutures in an inverting double-layer technique.

Perianastomotic drainage was routinely performed. Some patients received preoperative radiotherapy or radiochemotherapy.

C/I and TC

The C/Is were performed in the usual technique. For a TC the cecum is mobilized and a double row of concentric purse-string sutures is placed into the lateral cecal wall. A small incision is made within the inner purse-string and a 34F or 36F Pezzer mushroom catheter (Rusch AG, Kernen i. R., Germany) with enlarged tip openings in the bulge of the mushroom is then inserted into the lumen using an obturator. The inner purse-string suture is then tied, followed by the outer purse string. A generous purse-string suture must be made, with enough tissue invaginated around the TC to prevent leakage.

A small stab incision is then made in the lateral abdominal wall and the distal end of the catheter is drawn through. The incision site in the cecum (exit of the catheter from the colon) is approximated to the inner abdominal wall (where the catheter exits the abdominal wall) and extraperitonealized by fixing the mobilized cecal wall around the catheter to the inner abdominal wall. This can easily be accomplished with 3 to 4 interrupted sutures (**Figure**).

A skin suture tied around the catheter at its exit from the abdominal wall is desirable. The catheter is immediately attached to gravity drainage and allowed to stay open. After 24 hours gentle irrigation through the catheter (to keep it open) may be started. In the first 3 to 4 postoperative days, parenteral nutrition is administered. The next 2 to 3 days patients are given a liquid diet.

On day 11 or 12, after the TC has served its purpose, the tube can be withdrawn easily. Although it is not essential, an obturator may be inserted through the cutoff catheter, thereby stretching out the mushroom bulge, and thus lessening the discomfort of removal. Drainage of feces through the catheter site is minimal and usually stops entirely within a few hours. The small stab incision is allowed to heal by secondary intention.

STATISTICAL ANALYSIS

Differences between both treatment groups were examined by means of frequency tables or medians and ranges. Nonparametric tests (χ^2 for nominal data, Mann-Whitney test for ordinal data) were used for statistical comparisons. $P < .05$ was considered to be statistically significant.

pared with TC for the clinical anastomotic leakage rate, reoperation rate for anastomotic leaks/fistulas, postoperative mortality, permanent colostomy rate, and median hospital stay.

RESULTS

The rate of clinical anastomotic leakage was 11% (17 of 158 patients) in the overall population of patients hav-

ing rectal resections. Leakage rate in the nondefunctioned patients was 8% (9 of 109 patients).

In defunctioned patients clinical anastomotic leaks occurred in 3 (16%) of 19 patients in group 1 (C/I) and in 5 (17%) of 30 patients in group 2 (TC).

Patients and tumor characteristics were comparable in groups 1 and 2 (Table 1).

In all patients with clinical leaks in group 1, healing of the anastomotic leak occurred spontaneously af-

Table 1. Characteristics of Study Population*

	Group 1† (n = 19)	Group 2† (n = 30)
Male/female	11/8	19/11
Mean age (SD), y	65.4 (11.2)	67.2 (12.1)
Tumor stage		
T1 + T2	8 (42)	9 (30)
T3 + T4	11 (58)	21 (70)
Quality of resection		
Curative	17 (90)	26 (87)
Palliative	2 (10)	4 (13)
Level of anastomosis		
≤6 cm	16 (84)	24 (80)
>6 cm	3 (16)	6 (20)
Type of anastomosis		
Hand sewn	9 (47)	15 (50)
Stapled	10 (53)	15 (50)
Preoperative radiotherapy	2 (10)	7 (23)

*Values are expressed as number (percentage) unless otherwise indicated.

†Group 1 indicates patients with loop colostomy/ileostomy; group 2, patients with tube cecostomy.

ter deferring colostomy closure. The colostomies were closed 4, 5, and 8 months after the primary operation. In 15 patients without clinical leaks the stomas were successfully closed without mortality. Two patients subsequently developed an incisional hernia at this site.

One patient died of myocardial infarction 29 days after rectal resection before colostomy closure could be performed.

In group 2, three of 5 patients with leakage developed fecal peritonitis that necessitated emergency laparotomy. Peritoneal toilet, removal of the TC, and a colostomy were performed in 2 patients. In one patient the colostomy was closed after 4 months; in the other patient early local recurrence of an advanced tumor precluded colostomy closure. This patient died of local and distant recurrence 6 months after the primary operation. In the third patient who required an emergency relaparotomy, an abdominoperineal excision had to be performed.

In the fourth patient an anastomotic fistula into the vagina was diagnosed 3 months after the primary operation. To facilitate healing of the fistula an end colostomy using the descending colon was performed, thereby leaving the rectal stump in place. This colostomy was never closed due to persistent fistula. The fifth patient with an anastomotic leak did not develop peritonitis and recovered with antibiotic treatment and transperineal drainage of a pelvic abscess. In all other patients (25 of 30) the postoperative course was uneventful and the TC was removed between day 12 and day 14.

Patients in group 1 (primary operation and colostomy closure) stayed significantly longer in hospital than those of group 2 (28 vs 15 days, $P < .001$).

Postoperative mortality was 5% in group 1 and 0% in group 2 (Table 2).

COMMENT

The high rate of clinical anastomotic leaks in this series is due to the fact that most anastomoses were very low, situ-

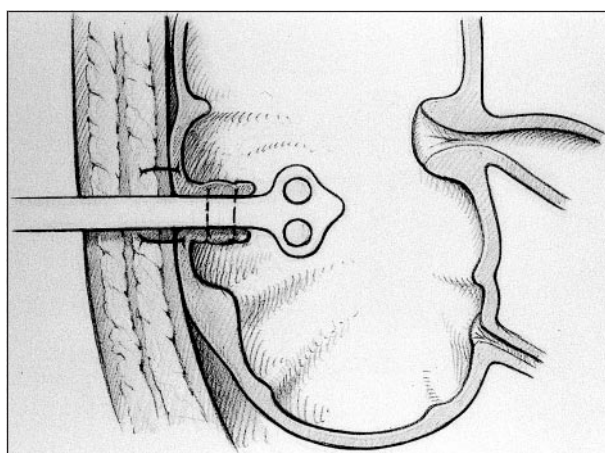
Table 2. Results of Group 1 and Group 2 for Anastomotic Protection in Rectal Cancer*

	Group 1 (n = 19)	Group 2 (n = 30)
Anastomotic leakage	3 (16)	5 (17)
Fecal peritonitis	0 (0)	3 (10)
Reoperation for anastomotic leakage/fistula	0 (0)	4 (13)
Permanent colostomy	0 (0)	2 (7)
Complications after colostomy closure	2 (10)	...
Median hospital stay, d†	28	15‡
Mortality	1 (5)	0 (0)

*Group 1 indicates patients with loop colostomy/ileostomy; group 2, patients with tube cecostomy. Values are expressed as number (percentage) unless otherwise indicated.

†Median hospital stay in group 1: stay for primary operation and colostomy closure.

‡ $P < .05$, Mann-Whitney test.



The tube is secured in the cecum by a double row of concentric purse-string sutures. The mobilized cecal wall around the catheter is fixed to the inner abdominal wall with 3 to 4 interrupted sutures.

ated 6 cm or less from the anal verge, and because sphincter-saving resection for an obese patient or because of a narrow pelvis was rarely avoided. When a stoma was in place, the anastomotic leakage rate was higher than when it was not. This finding is also reported by others^{16,17} and might be explained by the fact that only anastomoses were defunctioned where there was a particular surgical concern.

Many surgeons believe that a defunctioning colostomy reduces the incidence of anastomotic breakdown and minimizes the consequences if it occurs. In other series,^{12,18} no benefit has been found from defunctioning colostomy and thus it has been considered unnecessary. In conclusion, the possible benefits of a stoma must be weighed against the morbidity and disability conferred on most patients who would recover without complications.

However, several authors recommend a protective stoma, after sphincter-saving resections for rectal cancer, for anastomoses situated at or less than 5 to 6 cm from the anal verge,¹³ and particularly for men and obese patients⁵ after either total mesorectal excision^{2,4} or preoperative radiochemotherapy.⁸

In our hospital we routinely use a TC for protection of rectal anastomoses. The leakage rate in patients with TCs did not differ from patients with C/Is.

When an anastomotic dehiscence occurred emergency relaparotomy due to fecal peritonitis was necessary in 3 patients with TCs as compared with 0 patients with C/Is. However, mortality from fecal peritonitis and relaparotomy was 0. In 2 patients in group 2 (after relaparotomy and colostomy for anastomotic leakage), the stomas were never closed (1 patient with an abdominoperineal excision and 1 patient with a persistent fistula), no patient in group 1 received a permanent colostomy. Hospital mortality rates were 5% in group 1 and 0% in group 2.

CONCLUSION

The rates of clinical anastomotic leaks, emergency relaparotomies, fecal peritonitis, reoperations for anastomotic leaks/fistulas, postoperative mortality, and permanent colostomies did not differ significantly in either group. With a properly fashioned TC and adequate postoperative management, a second operation (for colostomy closure) with its associated morbidity can be avoided and the overall hospital stay is significantly reduced.

Corresponding author: Joerg Tschmelitsch, MD, Department of Surgery, University of Innsbruck, Anichstrasse 35, A-6020 Innsbruck, Austria (e-mail: joerg.tschmelitsch@uibk.ac.at).

REFERENCES

1. Grabham JA, Moran BJ, Lane RHS. Defunctioning colostomy for low anterior resection: a selective approach. *Br J Surg*. 1995;82:1331-1332.
2. Karanjia ND, Corder AP, Holdsworth PJ, Heald RJ. Risk of peritonitis and fatal

3. septicaemia and the need to defunction the low anastomosis. *Br J Surg*. 1991;78:196-198.
3. Dixon AR, Maxwell WA, Holmes JT. Carcinoma of the rectum: a 10-year experience. *Br J Surg*. 1991;78:308-311.
4. Carlsen E, Schlichting E, Guldvog I, Johnson E, Heald RJ. Effect of the introduction of total mesorectal excision for the treatment of rectal cancer. *Br J Surg*. 1998;85:526-529.
5. Rullier E, Laurent C, Garrelon JL, Michel P, Saric J, Parneix M. Risk factor for anastomotic leakage after resection of rectal cancer. *Br J Surg*. 1998;85:355-358.
6. Fielding LP, Stewart-Brown S, Blesovsky L, Kearney G. Anastomotic integrity after operations for large-bowel cancer: a multicentre study. *BMJ*. 1980;281:411-414.
7. Antonsen HK, Kronborg O. Early complications after low anterior resection for rectal cancer using the EEA stapling device: a prospective trial. *Dis Colon Rectum*. 1987;30:579-583.
8. Graf W, Glimelius B, Bergström R, Pahlman L. Complications after double- and single-stapling in rectal surgery. *Eur J Surg*. 1991;157:543-547.
9. Bozzetti F, Bertario L, Bombelli L, et al. Double- versus single-stapling, technique in rectal anastomosis. *Int J Colorectal Dis*. 1992;7:31-34.
10. Mealy K, Burke P, Hyland J. Anterior resection without a defunctioning colostomy: questions of safety. *Br J Surg*. 1992;79:305-307.
11. Karanjia ND, Corder AP, Bearn P, Heald RJ. Leakage from stapled low anastomosis after total mesorectal excision for carcinoma of the rectum. *Br J Surg*. 1994;81:1224-1226.
12. Pakkaste TE, Luukkonen PE, Järvinen HJ. Anastomotic leakage after anterior resection of the rectum. *Eur J Surg*. 1994;160:293-297.
13. Laxamana A, Solomon MJ, Cohen Z, Feinberg SM, Stern HS, McLeod RS. Long-term results of anterior resection using the double-stapling technique. *Dis Colon Rectum*. 1995;38:1246-1250.
14. Knox AJ, Birkett FD, Collins CD. Closure of colostomy. *Br J Surg*. 1971;58:669-672.
15. Bozzetti F, Nava M, Bufalino R, et al. Early local complications following colostomy closure in cancer patients. *Dis Colon Rectum*. 1983;26:25-29.
16. Fielding L, Stewart-Brown S, Hittinger R, Blesovsky L. Covering stoma for elective anterior resection of the rectum: an outmoded operation? *Am J Surg*. 1981;147:524-530.
17. Friedmann P, Garb JL, McCabe DP, et al. Intestinal anastomosis after preoperative radiation therapy for carcinoma of the rectum. *Surg Gynecol Obstet*. 1987;164:257-260.
18. Bolton RA, Britton DC. Restorative surgery of the rectum with a circumferential stapler. *Lancet*. 1980;1:850-851.

Invited Critique

This article by Tschmelitsch et al is more memorable for what it does not say than for what it does. A group of patients requiring low rectal anastomosis after cancer resection has been selected for proximal protective procedures, either a loop stoma or a tube cecostomy. The article does not state the criteria used to establish the selection of these patients. Three patients, in the group who underwent tube cecostomy (group 2), are noted to have developed fecal peritonitis. The article does not state the source of the peritonitis; one is left to assume that it came from an anastomotic leak rather than the tube cecostomy. Mortality, complications, reoperations, and anastomotic leaks were not statistically different in the 2 groups. After a good deal of analysis, the article presents us with one statistically proven fact: individuals having a tube cecostomy rather than a proximal stoma spent less time in the hospital after the operation. The study does indicate that the establishment of such proximal protective procedures did not help the overall group of patients. In fact, those patients undergoing low anastomosis who did not have proximal protective manipulations fared better than those who did. The failure of the authors to provide definite and specific criteria for the selection of patients for proximal protective operations is a major flaw.

My bias is that proximal protective operations should not be done unless they are totally diverting and clearly needed. Neither tube cecostomy nor loop colostomy/ileostomy is a completely diverting procedure. A completely diverting ileal stoma can be accomplished as easily as a loop colostomy/ileostomy and can require little operative manipulation for closure. Their results unfortunately add few, if any, facts to our decisions to perform such procedures.

Arthur S. McFee, MD
San Antonio, Tex