ORIGINAL ARTICLE

Internal Drainage of Giant Acute Pseudocysts

The Role of Video-Assisted Pancreatic Necrosectomy

Alejandro Oría, MD; Carlos Ocampo, MD; Hugo Zandalazini, MD; Luis Chiappetta, MD; Carlos Morán, MD

Background: Internal drainage of giant pancreatic pseudocysts secondary to acute pancreatitis is frequently complicated with postoperative retroperitoneal infection and hemorrhage. Recent data suggest that the risk factor is unrecognized pancreatic necrosis; presumably, pancreatic necrosis becomes infected with bacteria introduced by the cystoenteric anastomosis.

Hypothesis: Video-assisted pancreatic necrosectomy, performed at the time of internal drainage, may prevent postoperative retroperitoneal complications in patients with giant acute pseudocysts.

Design: A consecutive case-series.

Setting: An urban, university-affiliated, tertiary referral center.

Patients: Ten consecutive patients with acute pseudocysts measuring 10 cm or more in major diameter. The mean extent of pancreatic necrosis, as shown by contrast-enhanced computed tomography, was 50%. All patients were operated on electively, at an average time of 7.7 weeks from onset of the attack to surgical treatment.

Intervention: Through a midline incision, a 4-cm opening is made at the base of the pseudocyst. Standard laparoscopic instruments are introduced into the pseudocyst and video-assisted pancreatic necrosectomy is performed. The opening is then anastomosed to a Roux-en-Y limb of the jejunum.

Main Outcome Measures: Feasibility and safety of video-assisted pancreatic necrosectomy, postoperative morbidity and mortality, hospital stay, and resolution of pseudocysts.

Results: Complete necrosectomy was safely performed throughout. There were neither postoperative retroperitoneal complications nor mortality. Mean hospital stay was 8.2 days and all pseudocysts resolved at a mean follow-up of 6.9 months.

Conclusions: Video-assisted pancreatic necrosectomy at the time of internal drainage seems to prevent postoperative retroperitoneal complications in patients with giant acute pseudocysts. Depending on appropriate surgical timing, video-assisted necrosectomy is a feasible and safe procedure.

Arch Surg. 2000;135:136-140

From the Department of Surgery, Cosme Argerich Hospital (Drs Oría, Ocampo, Zandalazini, and Chiappetta) and the Department of Medicine, Bonorino Udaondo Hospital (Dr Morán), Buenos Aires, Argentina.

GIANT ACUTE pancreatic pseudocysts are those occurring after acute pancreatitis and measuring 10 cm or more in major diameter. In recent reports,[1,2] internal drainage of giant acute pseudocysts has led to significant morbidity and mortality due to postoperative retroperitoneal infection and hemorrhage. It has become clear that large acute pseudocysts usually evolve from severe attacks of acute pancreatitis[2] and are frequently associated with extensive pancreatic necrosis.[3] Furthermore, it has been shown that internal or external drainage of acute pseudocysts associated with sterile pancreatic necrosis may result in retroperitoneal infection when necrotic tissue is not removed.[4] Thus, surgical treatment of giant acute pseudocysts should pursue 2 major goals: first, pancreatic necrosis, when present, should be removed to prevent postoperative retroperitoneal complications; second, effective dependent drainage should be provided to prevent stasis and pseudocyst recurrence.

See Invited Critique at end of article

At the time of standard internal drainage, necrosectomy is performed by probing at the small opening in the pseudocyst wall.[4,5] Because maneuvers are performed blindly, this technique is hazardous and unreliable. However, unroofing the pseudocyst to obtain adequate exposure renders

©2000 American Medical Association. All rights reserved.
Downloaded From: http://archsurg.jamanetwork.com/ on 04/24/2017

PATIENTS AND METHODS

From September 3, 1997, to November 13, 1998, 10 consecutive patients with giant acute pseudocysts were operated on electively, using a procedure as outlined below. A giant acute pseudocyst was defined as a collection of pancreatic juice 10 cm or more in major diameter, of more than 4 weeks' duration, enclosed by a well-defined wall, and occurring after an episode of acute pancreatitis. There were 7 men and 3 women with a mean age of 35.9 years (age range, 21-60 years). Because 9 of the 10 patients were initially hospitalized elsewhere and then transferred to Cosme Argerich Hospital, Buenos Aires, Argentina, Ranson criteria could not be evaluated at the onset of the attack. On admission to our hospital, the most common symptoms were epigastric fullness, nausea, and abdominal pain. An epigastric mass was felt in all patients; 7 had a weight loss exceeding 5 kg since the onset of the attack. One patient reported low-grade intermittent fever, and another had insulin-dependent diabetes develop 10 days after the onset of the attack. All patients underwent contrast-enhanced computed tomography (CT) preoperatively. Pancreatic necrosis was defined as a nonenhanced zone of pancreatic parenchyma involving 30% or more of the pancreas.[6]

PROCEDURE

The abdomen is entered through a midline incision 5 cm above and 2 cm below the umbilicus. As the transverse colon is retracted upward, the pseudocyst wall is usually identified by its protrusion through the transverse mesocolon; otherwise, the base of the pseudocyst is readily identified using intraoperative ultrasonography. A 4-cm incision is made in the pseudocyst wall at the left of the middle colic vessels. After evacuation and culture of fluid contents, videoendoscopic inspection of the cavity is undertaken (**Figure 1**). Video-assisted necrosectomy is usually started at the pancreatic body level. If the surgical timing is adequate, vascular thrombosis has created an avascular plane between the necrotic pancreas and the splenic vessels that is entered bluntly. This plane is further extended to the right and to the left, using blunt dissection and gentle traction. Detachment of viable from nonviable pancreatic tissue may have occurred spontaneously during the preoperative period; otherwise, it must be induced by gentle traction. Debridement of necrotic tissue at the anterior pseudocyst wall is then performed, and ramifications of the pseudocyst are examined for residual necrotic tissue. Hemostasis is achieved by electrocoagulation and the cavity irrigated with 1 L of isotonic saline solution. The opening at the pseudocyst wall is then anastomosed to a Roux-en-Y limb of jejunum. A drain is left near the anastomosis, but the pseudocyst cavity is not drained. Biliary surgery, if necessary, is then undertaken. Intravenous administration of broad-spectrum antibiotics is started before the procedure and discontinued 24 hours after.

FOLLOW- UP

Contrast-enhanced CT was repeated during the first postoperative month to correlate the amount of remaining pancreas with preoperative estimation of pancreatic necrosis. Follow-up data were obtained through office visits. Abdominal ultrasound was performed monthly, and pseudocyst resolution was defined as the absence of a residual collection.

the pseudocyst cavity unsuitable for internal drainage. The advent of videoendoscopic technology offers a new approach for dealing with pancreatic necrosis at the time of internal drainage. Because the large cavity of a giant pseudocyst provides an adequate chamber for videoendoscopic maneuvers, pancreatic necrosectomy can now be performed through the conventional opening required for cystoenteric anastomosis.

This study assessed the efficacy of video-assisted pancreatic necrosectomy, performed at the time of internal drainage, to prevent postoperative retroperitoneal complications in patients with giant acute pseudocysts.

RESULTS

Clinical data on the 10 patients are summarized in the **Table**. The causes of acute pancreatitis were gallstones in 7 patients, alcohol in 2, and idiopathic in 1. The mean time from onset of the attack to internal drainage was 7.7 weeks (range, 5-15 weeks). The degree of pancreatic necrosis, as calculated from preoperative and postoperative contrast-enhanced CT, ranged from 30% to 50% in 6 patients and exceeded 50% in the remaining 4 patients. Necrosis involved the pancreatic body alone in 3 patients and the pancreatic body and tail in another 3 patients; in the remaining 4 patients, necrosis involved the pancreatic body, tail, and part of the pancreatic head (**Figure 2**).

Fluid obtained on entry into the pseudocyst appeared dark in 6 patients, gray in 3, and purulent in 1. Bacterial cultures were negative for organisms in 8 patients and positive in 2 patients. Organisms cultured were *Klebsiella* species in one and *Candida* species in the other. Complete pancreatic necrosectomy was achieved throughout. In 2 patients, necrotic pancreatic tissue was found floating freely inside the pseudocyst. Mean time for pancreatic necrosectomy was 30 minutes (range, 8-45 minutes). In 1 patient, intracystic bleeding was observed at the end of necrosectomy, and videoendoscopic exploration localized the source of bleeding in a ramification of the pseudocyst, in which residual necrosis was disclosed. Hemostasis was definitely achived once necrosectomy was completed. A pseudocyst wall sufficiently thick to hold sutures was found throughout. Cystojejunostomy was performed in 9 cases, and cystogastrostomy was performed for a 10-cm pseudocyst located high in the lesser sac. In this latter case, video-assisted necrosectomy was performed through the opening in the posterior gastric wall. Of the 7 patients who had gallstone pancreatitis, 4 underwent concurrent cholecystectomy; 1 underwent cholecystostomy due to a severe inflammatory reaction in the hepatoduodenal ligament; while in the remaining 2 patients, early cholecystec-

©2000 American Medical Association. All rights reserved.
Downloaded From: http://archsurg.jamanetwork.com/ on 04/24/2017

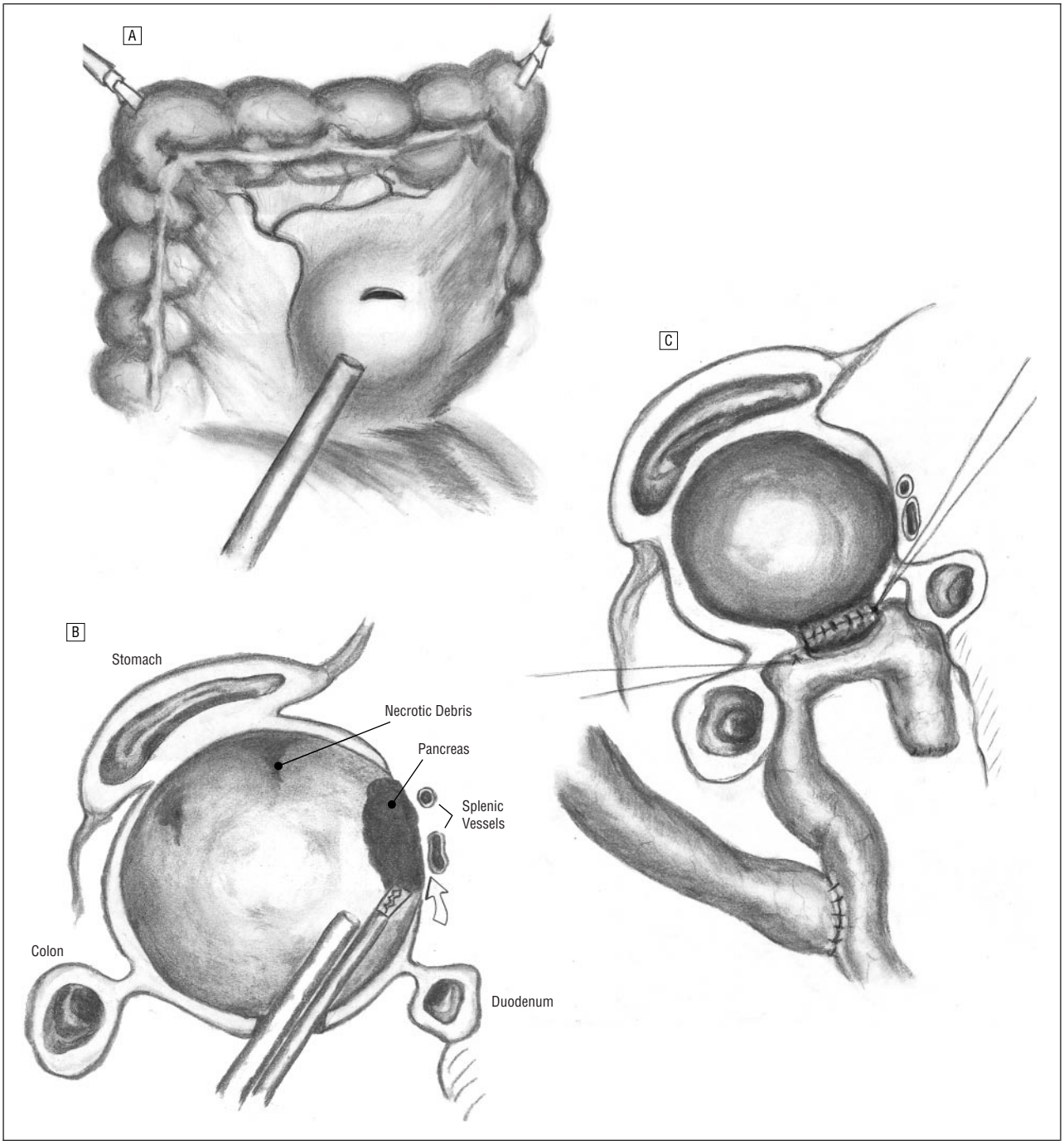

Figure 1. *Technique of cystojejunostomy with video-assisted pancreatic necrosectomy. A, Laparoscopic instruments are advanced through an opening in the pseudocyst. B, The avascular plane behind the necrotic pancreas (arrow) is opened and necrosectomy is performed using grasping forceps. Note the absence of pseudocyst wall in the area of necrotic pancreatic tissue and the presence of small extrapancreatic necrotic debris. C, After necrosectomy, the opening is anastomosed to a Roux-en-Y limb of the jejunum.*

tomy had been performed at the initial hospital admission. A case of superficial wound infection was the only postoperative complication in the entire case-series. In the same patient, a cholangiogram obtained through a cholecystostomy tube disclosed a stone at the distal biliary duct. Endoscopic sphincterotomy was carried out on the 16th postoperative day, and the patient was discharged from the hospital 4 days later. Overall, mean postoperative hospital stay was 8.2 days (range, 5-20 days).

Pseudocyst resolution was achieved throughout at a mean follow-up of 6.9 months (follow-up range, 2-14 months), and all patients regained weight to their baseline level without clinical evidence of exocrine insufficiency. The one patient in whom insulin-dependent diabetes developed during the preoperative period is receiving a regimen of oral medication and diet maintenance alone. Overt diabetes developed in another patient 3 months after surgery.

©2000 American Medical Association. All rights reserved.
Downloaded From: http://archsurg.jamanetwork.com/ on 04/24/2017

Results of Video-Assisted Necrosectomy and Internal Drainage for Giant Acute Pancreatic Pseudocysts

No. of Patient/ Age, y/Sex	Size, cm*	Necrosis, %	Timing, wk†	Bacteriology	Drainage‡	Complications	Length of Hospital Stay, d
1/26/M	16	60	8	Negative	CJ	None	7
2/21/F	18	80	5.5	Positive	CJ	None	7
3/26/M	11	40	5	Negative	CJ	None	7
4/25/F	12	50	4.5	Negative	CJ	None	8
5/42/F	10	60	5	Positive	CJ	Wound infection	20
6/37/M	13	60	12	Negative	CJ	None	7
7/60/M	11	40	15	Negative	CJ	None	6
8/44/M	10	40	8	Negative	CG	None	5
9/25/M	11	40	6	Negative	CJ	None	7
10/53/M	12	30	8	Negative	CJ	None	8

*Size indicates the major diameter of the pseudocyst.
†Timing indicates the interval between onset of the attack and internal drainage.
‡CJ indicates cystojejunostomy; CG, cystogastrostomy.

COMMENT

A major factor limiting our understanding of pancreatic pseudocysts is the lack of a precise terminology. The Atlanta Classification[6] makes a useful clinical distinction between acute pseudocysts and acute fluid collections; however, it fails to address the wide spectrum of pancreatic lesions associated with acute pseudocysts. Acute fluid collections may originate in interstitial and in necrotizing acute pancreatitis.[7,8] In necrotizing acute pancreatitis, fluid collection and necrotic pancreas become contained by surrounding structures and, 4 to 8 weeks after onset of the attack, develop a wall sufficiently thick to be recognized as a pseudocyst.[3] In our study, preoperative and postoperative contrast-enhanced CT showed that giant acute pseudocysts had evolved from fluid collections associated with full-segment pancreatic necrosis.

Several articles have documented that the presence of pancreatic necrosis is a major factor leading to postoperative complications in sterile acute pseudocysts.[9-12] Surgical or nonsurgical drainage may result in postoperative retroperitoneal sepsis and hemorrhage when the drainage procedure fails to remove the underlying necrotic material. These complications have been related to contamination of pancreatic necrosis with bacteria introduced by internal or external drainage.[4,13] Likewise, elective internal drainage of giant acute pseudocysts has resulted in high morbidity and mortality rates due to postoperative retroperitoneal sepsis and hemorrhage.[1,2] Behrman et al[2] reported a 42% reoperation rate in 7 patients with giant acute pseudocysts treated with internal drainage. Although this study is difficult to interpret, due to the lack of data concerning pancreatic necrosis, it is conceivable that unrecognized pancreatic necrosis may have played a major role in postoperative complications. Thus, available data suggest that pancreatic necrosis should be dealt with at the time of acute pseudocyst drainage.

This contention is further supported by the absence of major postoperative complications in our series. None of our patients developed postoperative retroperitoneal sepsis or hemorrhage, including 2 patients with fluid cultures positive for organisms. However, we also attribute our low morbidity and definite resolution of pseudocysts to the use of effective dependent drainage. Because giant acute pseudocysts usually extend downward through the transverse mesocolon, cystojejunostomy is commonly the only procedure that can provide dependent drainage. In our series, cystogastrostomy was used in only one patient with a 10-cm acute pseudocyst with a high location. Finally, the results of our study compare favorably with our 25% reoperation rate in the previous 20 months. During this period, of 8 patients with giant acute sterile pseudocysts who underwent standard cystojejunostomy, 2 developed severe postoperative complications: 1 died of multiorgan system failure due to massive retroperitoneal hemorrhage, and 1 survived after open-packing for retroperitoneal sepsis. In both cases, wide opening of the pseudocyst cavity at reoperation disclosed a large amount of pancreatic necrosis that had been overlooked at the initial operation.

The success of video-assisted pancreatic necrosectomy depends on appropriate timing of intervention, accurate preoperative estimation of pancreatic necrosis, and the presence of a large pseudocyst cavity. Timing of intervention exceeding 4 weeks after the onset of the attack allows clear demarcation of nonviable tissue, detachment of pancreatic necrosis from vascular structures, and maturation of the pseudocyst wall. Preoperative estimation of pancreatic necrosis in acute pseudocysts can be made using contrast-enhanced CT and ultrasonography or magnetic resonance imaging.[11,14] Contrast-enhanced CT alone proved efficacious in our study, but magnetic resonance imaging has been reported to be more sensitive for detecting peripancreatic solid debris.[11] Finally, only a large pseudocyst cavity can provide sufficient exposure for video-assisted necrosectomy.

Our study has several limitations. Because almost all patients were referred to our hospital specifically to undergo surgery, a bias may have been created toward greater inclusion of large pseudocysts not amenable to alternative drainage methods due to the presence of extensive pancreatic necrosis. However, our population does not mirror the natural history of giant acute pseudocysts since all were operated on electively, more than 4 weeks after the onset of the attack. In contrast, it has been

©2000 American Medical Association. All rights reserved.
Downloaded From: http://archsurg.jamanetwork.com/ on 04/24/2017

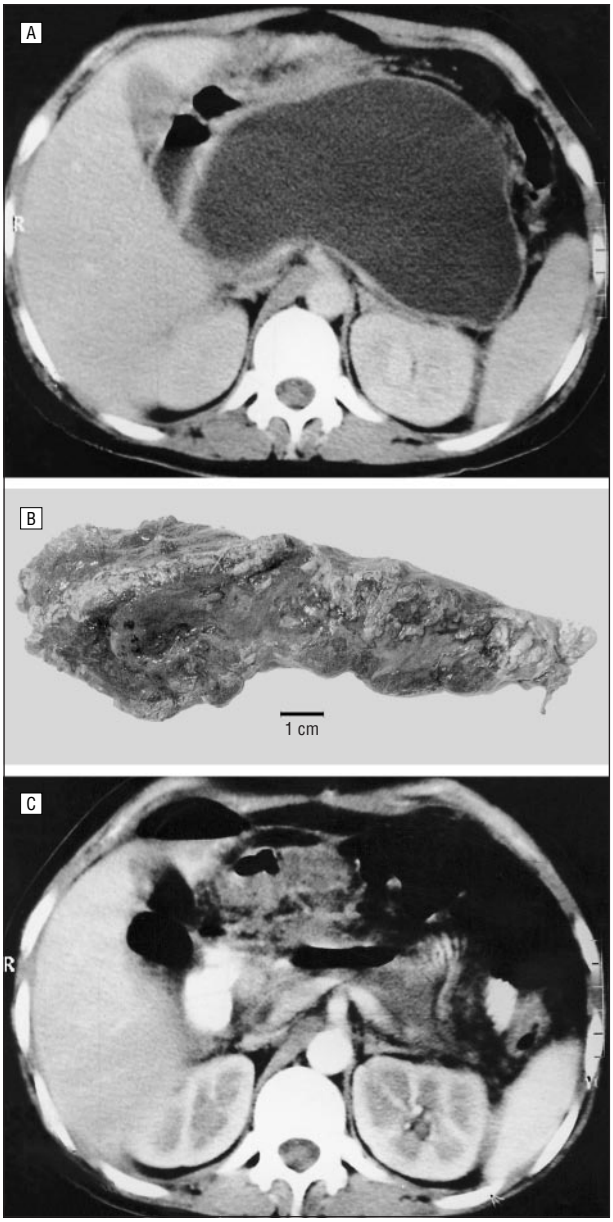

Figure 2. *Patient 2. A, Computed tomographic scan showing a giant acute pseudocyst and lack of contrast enhancement of pancreatic body and tail. B, View of the necrosectomy specimen. C, Postoperative computed tomographic scan showing absence of pancreatic body and tail. Gas at the pancreatic bed is due to the cystoenteric anastomosis.*

shown that, in nonselected series, more than 50% of giant acute pseudocysts develop early life-threatening complications.[2,7] Thus, the spectrum of giant acute pseudocysts represented in this case-series is not truly representative of that seen in other institutions.

In conclusion, our study shows that, in patients with giant acute pseudocysts associated with extensive pancreatic necrosis, complete pancreatic necrosectomy at the time of internal drainage seems to prevent postoperative retroperitoneal complications. Provided surgical timing is appropriate, video-assisted necrosectomy is a feasible and safe procedure.

We thank Angeles Petersen, MD, for drawing the medical illustrations.

Corresponding author: Alejandro Oría, MD, Av Alvear 1583, 4 Piso B, 1014 Capital Federal, Buenos Aires, Argentina (e-mail: cbazterrica@abaconet.com.ar).

REFERENCES

1. Johnson LB, Rattner DW, Warshaw AL. The effect of the size of giant pancreatic pseudocysts on the outcome of internal drainage procedures. *Surg Gynecol Obstet.* 1991;773:171-174.
2. Behrman SW, Melvin S, Ellison C. Pancreatic pseudocysts following acute pancreatitis. *Am J Surg.* 1996;172:228-231.
3. Frey CF. Peripancreatic fluid collections. In: Beger HG, Warshaw AL, Büchler MW, et al, eds. *The Pancreas.* Vol 1. London, England: Blackwell Science Ltd; 1998: 423-437.
4. Hariri H, Slivka A, Carr-Locke DL, Banks PA. Pseudocyst drainage predisposes to infection when pancreatic necrosis is unrecognized. *Am J Gastroenterol.* 1994; 89:1781-1784.
5. Wilson C, McArdle CS, Carter DC, Imrie CW. Surgical treatment of acute necrotizing pancreatitis. *Br J Surg.* 1988;75:1119-1123.
6. Bradley EL III. A clinically based classification system for acute pancreatitis: summary of the Atlanta International Symposium. *Arch Surg.* 1993;129:586-590.
7. Agha FP. Spontaneous resolution of acute pancreatic pseudocysts. *Surg Gynecol Obstet.* 1984;158:22-26.
8. Tenner SM, Banks PA. Treatment of interstitial pancreatitis. In: Beger HG, Warshaw AL, Büchler MW, et al, eds. *The Pancreas.* Vol 1. London, England: Blackwell Science Ltd; 1998:503-507.
9. Baron TH, Thaggard WC, Morgan DE, Stanley RJ. Endoscopic therapy for organized pancreatic necrosis. *Gastroenterology.* 1996;111:755-764.
10. Mainwaring R, Kern J, Scheink WG, Rudolf LE. Differentiating pancreatic pseudocysts and pancreatic necrosis using computerized tomography. *Ann Surg.* 1989; 209:562-568.
11. Morgan DE, Baron TH, Kevin-Smith J, Robbin ML, Kenney PJ. Pancreatic fluid collections prior to intervention: evaluation with MR imaging compared with CT and US. *Radiology.* 1997;203:773-778.
12. Feig BW, Pomeranz RA, Vogelzang R, Rege RV, Nahrwold DL, Joehl RI. Treatment of peripancreatic fluid collections in patients with complicated acute pancreatitis. *Surg Gynecol Obstet.* 1992;175:429-436.
13. Kozarek RA. Endotherapy for organized pancreatic necrosis: perspective on skunk-poking. *Gastroenterology.* 1996;111:820-822.
14. Balthazar EJ. Contrast-enhanced tomography in severe acute pancreatitis. In: Bradley EL III, ed. *Acute Pancreatitis: Diagnosis and Therapy.* New York, NY: Raven Press; 1994:57-68.

©2000 American Medical Association. All rights reserved.
Downloaded From: http://archsurg.jamanetwork.com/ on 04/24/2017