

Minimally Invasive Surgery for Primary Hyperparathyroidism

Systematic Review

Thomas S. Reeve, MB, FRACS, FACS[Hons]; Wendy J. Babidge, BAppSci[Hons], PhD; Robert F. Parkyn, FRACS; Anthony J. Edis, MD, FACS, FRACS; Leigh W. Delbridge, MD, FRACS; Peter G. Devitt, MS, FRCS, FRACS; Guy J. Maddern, PhD, MS, FRACS

Hypothesis: Use of minimally invasive parathyroidectomy techniques, either unilateral or endoscopic, will result in the same or improved safety and efficacy outcomes as those of the bilateral open neck exploration technique in patients with primary hyperparathyroidism.

Data Sources: Studies on minimally invasive parathyroid surgery were identified using MEDLINE (January 1984 to August 1998), EMBASE (January 1974 to August 1998), and Current Contents (week 1 of 1993 to week 34 of 1998). The search terms were as follows: ((endoscop* or (minimal* and invasive) or unilateral) and parathyroid). The Cochrane Library was searched from issue 1 of 1966 to issue 3 of 1998, using the search terms “parathyroidectomy or parathyroid resection.”

Study Selection: Human studies of patients with primary hyperparathyroidism using unilateral or endoscopic exploration were included. Animal studies describing minimally invasive technique development were also included. A surgeon (R.F.P.) and researcher (W.J.B.) independently assessed the retrieved articles for their inclusion in the review.

Data Extraction: Studies directly comparing the unilateral method with bilateral open neck exploration were used to analyze outcomes.

Data Synthesis: Analysis of data using odds ratios and 95% confidence intervals indicated a tendency to favor the unilateral technique. However, these individual studies generally had large confidence intervals; therefore, preference to the unilateral procedure cannot be espoused with certainty. There is also a selection bias due to the strict enrollment criteria for unilateral surgery.

Conclusions: The proposed role of minimally invasive parathyroid surgery is for patients with primary hyperparathyroidism who have unilateral parathyroid pathological features. To assess the safety and efficacy of minimally invasive techniques, it is suggested that their introduction be monitored as part of a trial in Australia, from which data should be accrued to a register.

Arch Surg. 2000;135:481-487

From the Australian Cancer Network (Dr Reeve) and the Department of Surgery, University of Sydney, Royal North Shore Hospital (Dr Delbridge), Sydney, New South Wales; the Australian Safety and Efficacy Register of New Interventional Procedures—Surgical, Royal Australasian College of Surgeons (Drs Babidge and Maddern), and the Departments of Surgery, University of Adelaide, The Queen Elizabeth Hospital (Drs Parkyn and Maddern), and University of Adelaide, Royal Adelaide Hospital (Mr Devitt), Adelaide, South Australia; and Mount Hospital, Perth, Western Australia (Dr Edis).

THE FIRST SURGERY of the parathyroid gland was in Vienna, Austria, in 1925.¹ The procedures for investigation and management of parathyroid disease have been carefully developed and incorporated as an integral part of surgical practice.^{2,3} A surgical procedure has been developed over time, which produces a satisfactory outcome in 95% to 98% of patients operated on.³⁻⁵ To achieve this level of success, experienced parathyroid surgeons are necessary. The diagnosis also needs to be clearly established, and criteria for patient inclusion followed, such as those developed from the National Institutes of Health Consensus Development Conference in 1990.⁶

The approach to surgery for primary hyperparathyroidism (PHPT) has been to proceed through a collar inci-

sion, to bilaterally explore the neck, to locate abnormal parathyroid tissue, and to remove it. In about 80% of cases, only 1 enlarged gland requires excision,³ and its removal results in 100% cure. Surgical failure is generally due to ectopic glands, multiglandular disease, supernumerary glands, or lack of surgical experience.⁷

The aim to improve and simplify surgical practice is accepted, and the newer methods of less invasive surgery are being explored in many anatomical locations of the body. Preoperative localization of abnormal parathyroid tissue has not been deemed necessary for the conventional surgical approach.^{3,8} The initial approach to unilateral surgery for PHPT by Tibblin and coworkers in 1982⁹ was that if a single diseased gland was found on the first side explored then the contralateral side could be left alone. The excised tis-

MATERIALS AND METHODS

ASERNIP-S REVIEW PROCESS

A surgeon (R.F.P.) familiar with the topic of review (protocol surgeon) and an ASERNIP-S researcher (W.J.B.) worked together to draft the protocol for the review and determined the studies to be included. The review surgeon assessed these publications and produced a narrative review. The ASERNIP-S researcher conducted a methodological assessment of the literature. The protocol, review, and methodological assessment report formed the review documentation, which was considered by the review group. The review group was made up of the review (T.S.R.) and protocol surgeons (R.F.P.); a nominated surgeon from the Section of Endocrine Surgery, Royal Australasian College of Surgeons (RACS) (A.J.E.), Melbourne, Victoria; an invited surgeon (L.W.D.); a surgeon from another specialty (P.G.D.); and an ASERNIP-S researcher (W.J.B.). The review group considered the review documentation, recommendations, and ASERNIP-S classification put forward by the review surgeon. The surgical director (G.J.M.) of ASERNIP-S oversaw this process and chaired the review group. Consensus was reached on the recommendations and classification, which were put forward to the ASERNIP-S management committee for ratification before being considered by the RACS council for endorsement.

SEARCH STRATEGY

Studies on minimally invasive parathyroid surgery by either the endoscopic technique or the unilateral approach were identified by searching MEDLINE between January 1984 and August 1998, Current Contents between week 1 of 1993 and week 34 of 1998, and EMBASE between January 1974 and August 1998. Review articles on the comparative intervention (bilateral open neck exploration for PHPT) were identified by searching the same databases from 1993 onward. These articles were used for a consensus opinion on the safety and efficacy of bilateral open neck exploration, when no comparison with the new intervention was made in some studies. The Cochrane Library was searched for minimally invasive procedures and bilateral open neck exploration, from issue 1 of 1966 to issue 3 of 1998. The search terms used for the minimally invasive technique were as follows: ((endoscop* or (minimal* and invasive) or unilateral) and parathyroid); and for the comparative intervention: (parathyroid* and ((surg* or management) in citation) and review in publication type) and English in language) (since 1993). The truncation symbol (“*”) differs in each database and allows retrieval of all possible suffix variations of a root word. The search terms for the Cochrane Library were “parathyroidectomy or parathyroid resection.” Only English-language articles were included for review.

INCLUSION CRITERIA

The types of studies to be included in the review of minimally invasive procedures included randomized controlled trials, controlled clinical trials (historical and nonrandomized), case series, and case reports. Human studies, specifically of patients with PHPT, and animal studies were considered. Those assessing the minimally invasive techniques, specifically endoscopic (either total or video-scopic-assisted) or unilateral techniques with preoperative imaging, were included. Studies for inclusion also required information on at least 1 of the following outcomes: preoperative and postoperative serum calcium and parathyroid hormone levels; postoperative morbidity, including recurrent nerve palsy and postoperative hemorrhage; conversion rate to standard operation; failed exploration; parathyroid capsule breach; recurrent hyperparathyroidism; incision length or scar; use of analgesics; length of hospital stay; or costs and postoperative mortality. Particular emphasis was placed on outcomes relating to safety and efficacy aspects of the procedures.

DATA EXTRACTION

Articles were assessed by the protocol surgeon and the ASERNIP-S researcher for their suitability for review based on the inclusion criteria specified in the protocol. Studies that clearly did not meet the inclusion criteria were marked for deletion by the ASERNIP-S researcher. All studies were assessed by the protocol surgeon, and a consensus was reached on articles for inclusion.

DATA ANALYSIS

Data were analyzed from each of the comparative studies by calculating odds ratios (ORs). A meta-analysis was not performed as the studies varied widely in outcome measures and study design, and the quality of studies was poor. **Table 1** contains the guidelines used for assessing the level of evidence of the studies. A summary of comparative studies appears in **Table 2**. A graphical representation of ORs with 95% confidence intervals from studies reporting adverse outcomes appears in the **Figure**. The OR was calculated using Review Manager, version 3.1, software³¹ and is a ratio of the odds for an outcome with the new intervention (unilateral exploration) divided by the odds for the same outcome with bilateral open neck exploration. For rare outcomes, such as seen in these studies, the OR and relative risks are considered equivalent for practical purposes. Because of the small number of comparative studies and the fact that most did not report similar outcomes, the data were not combined. All studies reporting on the endoscopic procedure were not comparative and thus outcomes could not be analyzed.

sue was studied microscopically during surgery with oil red O, and the decision to stop surgery at this stage was based on a reduction in intracytoplasmic fat droplets in the excised parathyroid tissue. Other groups have used imaging before surgery. Ultrasonography has been used successfully by Pyrttek and McClelland,¹⁰ with a sensitivity of correct localization of 80%, a specificity of 95%, and a diagnostic accuracy of 91%. Shen and colleagues¹¹

used technetium Tc 99m sestamibi scanning before first-time surgery, achieving correct identification of 71% of patients with a single adenoma. In this study,¹¹ unilateral exploration based on such imaging was not considered beneficial compared with the traditional bilateral method.

A high degree of experience is required for all imaging procedures, especially if a minimally invasive ap-

Table 1. Designation of Levels of Evidence*

- I. Evidence obtained from a systematic review of all relevant randomized controlled trials.
- II. Evidence obtained from at least 1 properly designed randomized controlled trial.
- III-1. Evidence obtained from well-designed pseudorandomized controlled trials (alternate allocation or some other method).
- III-2. Evidence obtained from comparative studies with concurrent controls and allocation not randomized (cohort studies), case-control studies, or interrupted time series with a control group.
- III-3. Evidence obtained from comparative studies with a historical control, 2 or more single-arm studies, or an interrupted time series without a parallel control group.
- IV. Evidence obtained from case series, either posttest or pretest and posttest.

*Data from the National Health and Medical Research Council.²²

Table 2. Summary of Comparative Studies of Unilateral and Bilateral Open Neck Exploration

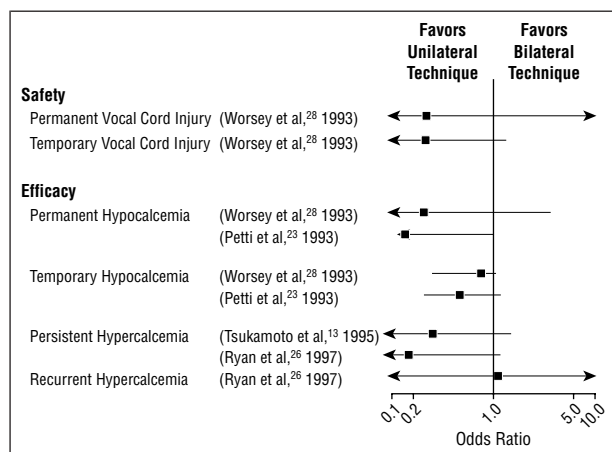
Source, y	Level of Evidence*	Imaging Technique†
Denham and Norman, ²⁵ 1998	I	Tc-sestamibi
Tsukamoto et al, ¹³ 1995	III-2	Th-Tc
van Vroonhoven and van Dalen, ³⁰ 1998	III-2	US and CT
Petti et al, ²³ 1993	III-2	Th-Tc
Ryan et al, ²⁶ 1997	III-2	US and Th-Tc
Vogel et al, ²⁴ 1998‡	III-2	US and/or Tc-sestamibi
Wei and Burke, ²⁷ 1995	III-2	Tc-sestamibi
Worsey et al, ²⁸ 1993	III-2	US and/or Th-Tc
Norman et al, ²⁹ 1998	III-3	Tc-sestamibi

*Table 1 provides an explanation of each level.

†Tc-sestamibi indicates technetium Tc 99m sestamibi;

Th-Tc, thallium-technetium subtraction scanning; US, ultrasonography; and CT, computed tomography.

‡Excluded from review.



Odds ratio and 95% confidence intervals for outcomes of comparative studies on unilateral vs bilateral neck exploration for primary hyperparathyroidism.

proach is planned. High-resolution ultrasonography has been widely used and has yielded satisfactory localization of parathyroid adenomas.¹² To achieve adequate results, however, ultrasonography requires a high level of operator skill. Thallium-technetium subtraction scintigraphy was introduced with the aim of improving the accuracy of localization, reducing surgical time, improving cosmesis, and being more cost-effective. Accuracy was dependent on the size of the adenoma¹³; however, as with ultrasonographic scanning, if a lesion was clearly identified and lateralized, then unilateral exploration was supported.¹⁴ Chapuis and coworkers,¹⁵ in looking for more accurate localization, assessed intraoperative monitoring of the parathyroid hormone to demonstrate persistence of PHPT. This, along with a combination of imaging expertise and strict patient enrollment criteria, provided an acceptable setting for the unilateral approach. Technetium Tc 99m sestamibi scanning is a newer and more accurate method of preoperative localization. For single gland pathological features, the technetium Tc 99m sestamibi scan results in a high level of accuracy, reported by several groups to be at least 96%.^{16,17} Norman and Chheda¹⁸ have advanced further with this technology and incorporated intraoperative scanning with

a handheld gamma counter (Neoprobe), 2 to 3 hours after administration of the isotope. This time delay allows for a reduction in the levels of background irradiation.

Few studies have been reported using the endoscopic approach to minimally invasive surgery for PHPT. The first case was reported by Gagner¹⁹ in 1996 for a patient in whom 3.5 abnormal glands were removed. Yeung²⁰ describes experience with this procedure in 4 patients. The largest series of cases was reported by Miccoli and colleagues,²¹ in which ultrasonography was used to locate a single adenoma. The quick parathyroid hormone (QPTH) assay was carried out to determine successful removal of the diseased gland. Along with careful patient selection, accurate localization, and a short period of carbon dioxide insufflation, this procedure appears highly successful in their hands.

This review is a précis of information produced during the process of assessment of minimally invasive parathyroid surgery for the Australian Safety and Efficacy Register of New Interventional Procedures—Surgical (ASERNIP-S). This review compares the outcomes of minimally invasive techniques with those of bilateral open neck exploration. The aims of ASERNIP-S reviews are to assess the safety and efficacy information on a new surgical procedure and to determine whether it is appropriate for widespread use or requires further evaluation in the form of an audit or a controlled clinical trial.

RESULTS

SAFETY

Forty-one studies were deemed to meet the inclusion criteria for the new intervention of minimally invasive parathyroidectomy in patients with PHPT. Of these, 8 were controlled studies (level III evidence) of the unilateral procedure with preoperative imaging, and 1 was a meta-analysis (level I evidence) assessing cost-effectiveness. One study was excluded because of perceived bias, as a single operator was used for all radiological assessments.²⁴ A summary of comparative studies appears in Table 2, and

Table 3. Reported Benefits and Harms of the Minimally Invasive Techniques Compared With Bilateral Open Neck Exploration for Parathyroidectomy

Technique*	Benefits	Harms
Unilateral exploration (level III evidence)	Smaller incision (improved cosmesis) Possible local anesthesia Shorter operating time Other side of neck left untouched	Possible rupture of the adenoma (removal through a small incision)
Endoscopic procedure (level IV evidence)	Smaller incision (improved cosmesis) Good visualization of the laryngeal nerve Less pain or discomfort	Possible rupture of the adenoma (removal through a small port); subcutaneous emphysema (due to lengthy carbon dioxide insufflation time); difficult visualization (due to bleeding) and operating space problems

*Table 1 provides an explanation of each level.

the Figure summarizes the ORs (95% confidence intervals) for various morbidities. There was no report of mortality in these studies.

An OR of more than 1 indicates superiority of the bilateral technique, while an OR of less than 1 suggests superiority of the unilateral technique (Figure). For most outcomes, it appeared that there was less risk using the unilateral technique for the outcomes measured. Most, however, have large confidence intervals and cover an OR of 1; therefore, it cannot be stated with certainty that the outcomes are not a product of chance. Results of the comparison between unilateral and bilateral techniques may be due to selection bias, ie, the patients undergoing unilateral surgery have been selected by stricter inclusion criteria, and thus the 2 patient populations may differ.

For the endoscopic procedure, no controlled studies were found, so case reports and case series were used (level IV evidence). There were 3 case reports^{19,32,33} that appeared to describe the same patient. Another group reported 3 studies, 1 article on technique development and 2 publications that appeared to relate to the same patients.^{20,34,35} Two other groups described technique development, one³⁶ in dogs and cadavers and the other³⁷ in dogs and patients. There were 2 reports^{21,38} of video-scopic-assisted surgical success in 6 and 39 patients, with a single adenoma. In these studies, no mortality was reported. Adverse outcomes were generally transient and often related to high insufflation pressures and lengthy operative times.^{19,32,33} Reported complications include subcutaneous emphysema and hypercapnia,^{19,32,33} temporary laryngeal nerve paresis,³⁹ and tachycardia.³²

EFFICACY

Operative times were shorter for the unilateral procedure when compared with bilateral open neck exploration.^{13,25-28} In 1 study,²⁷ operative success was 100% for the unilateral and bilateral techniques, while others^{13,28,29} have found higher success rates in unilateral compared with bilateral surgery; van Vroonhoven and van Dalen³⁰ found the reverse to be true. Hospital stay was shorter for the unilateral procedure than for bilateral open neck exploration.²⁹ The endoscopic technique was reported as being feasible but technically difficult. The totally endoscopic technique^{19,32,33} required long operating times, while the video-scopic-assisted technique^{21,38} was considerably shorter.

A summary of the perceived benefits and harms of the minimally invasive procedures compared with bilateral open neck exploration is given in **Table 3**.

Both procedures have strict inclusion and exclusion criteria that must be adhered to if a high success rate is to be achieved. Imaging before surgery by minimally invasive techniques is essential. These procedures are considered most applicable for removal of solitary adenomas. A surgeon experienced in endocrine surgery is also essential.

COMMENT

Assessment of morbidities associated with the techniques of unilateral and bilateral exploration for minimally invasive parathyroidectomy has shown no clear benefits by either technique.

In general, the quality of studies in the area of minimally invasive parathyroid surgery has been poor. It is understood that difficulties associated with performing randomized, controlled trials may preclude their use for this procedure. It is important, however, for unilateral neck exploration and endoscopic parathyroid surgery, that an appropriate assessment by well-designed studies is made before the widespread introduction of the technique in Australia. Following are recommendations made by the review surgeon regarding safety and efficacy and suggested future directions for the technique of minimally invasive parathyroidectomy.

SAFETY OF THE MINIMALLY INVASIVE TECHNIQUE

No evidence of mortality was found in any report in relation to bilateral or unilateral neck exploration or to any of the described "minimally invasive" procedures.

In the articles reviewed, only minimal morbidity was reported. Transient recurrent laryngeal nerve palsy was reported when removing an adenoma that had been located by ultrasonography³⁰ and with a video-scopic-assisted approach in 2 of 24 cases.³⁹ In the latter study, 4 cases required conversion of the procedure to a conventional approach. The reasons for conversion were as follows: 1 case of inability to visualize the adenoma, 1 case of bleeding, and 2 cases of incorrect localization by the technetium Tc 99m sestamibi scan.

The removal of a parathyroid adenoma through a small incision or through an endoscopic port or cannula provides a situation of risk for rupture of the

adenoma. Cell spillage, leading to parathyromatosis, could result. Great care should be exercised in removing parathyroid lesions through limited exits, even in a specimen bag.

A more immediately serious problem was reported with endoscopic parathyroidectomy, in association with carbon dioxide insufflation,^{19,32,33} where extensive subcutaneous emphysema of the “eyelids to the scrotum and anteriorly on the thorax and abdomen”^{19(p875)} occurred. Hypercapnia and tachycardia persisted throughout the procedure, which reportedly took between 5 and 7 hours. The problem resolved in 3 days. The insufflation pressure was recorded as 15,¹⁹ 20,³² and 15 mm Hg,³³ yet all appeared to be the same patient.

Miccoli and associates^{21,38} have used carbon dioxide insufflation under the strap muscles for 3 to 4 minutes at 12 mm Hg without complication. There has been no recorded instance of carbon dioxide embolism in any of the published case reports or case series. Adherence to the approach used by Miccoli and coworkers could ensure a low risk for this possible complication. It would appear from their reports that the method they have used is safe. This method should be considered by all those intending to undertake this type of surgery who plan to use carbon dioxide insufflation.

As seen from articles published in this review, the newer technical approaches require a sound knowledge of parathyroid pathological features and anatomy and the vagaries of both. This knowledge is built on sound surgical training and ongoing experience⁴⁰ or surgery by trainees under the close supervision of experienced surgeons.⁴¹ Surgeons undertaking parathyroid surgery would be expected to have such a background if successful outcomes and not moderately morbid procedures are to be expected.⁴⁰

EFFICACY OF MINIMALLY INVASIVE PARATHYROIDECTOMY

The classic surgical approach to PHPT has provided satisfactory results that have resulted from meticulous attention to diagnosis and operative care. In Australia, the surgery has been performed by surgeons well trained and experienced in this field.

To focus attention on the surgery only overlooks the importance of clearly establishing the diagnosis before operation. Surgeons caring for patients with PHPT should be expected to have a good understanding of the disease and its pathological and anatomical vagaries. A decision should be made before surgery as to what approach should be taken and clearly discussed with the patient.

The original approach offers 95% to 98% success at the initial operation, a cost-effective procedure without the need for routine localization studies, a hospital stay of 1 to 2 days, a major complication rate of less than 1%, and a cosmetically acceptable “collar” scar (Section of Endocrine Surgery, RACS, unpublished data, 1998).

The desire to cause less pain, provide a smaller scar, and leave one side of the neck pristine after surgery has been worked at by devoted endocrine surgeons for nearly 20 years, beginning with Tibblin and coworkers⁹ in 1982. Two groups of approaches for minimally invasive sur-

gery have evolved from this. It is necessary to see if these procedures measure up to the efficacy of the conventional approach. One group aims to define the cause of PHPT and, if clearly definable, approach it by a lesser surgical approach. Once the single site of the disease is identified, a limited incision can be used for removal of the affected gland or a nuclear probe can intraoperatively guide the surgery.¹⁸ Another group isolates unitary pathological features by ultrasonography and approaches them endoscopically. Measurement of QPTH intraoperatively monitors removal of the diseased gland.²¹ Both groups report satisfactory results.

Some groups use an endoscopic approach only,^{19,34} and the addition of a QPTH assay has occurred in one such major group. Another technique is to localize the unilateral pathological features, approach through a mini incision, and use a lateral probe to provide “superior visualization” through video assistance.⁴² The extra visual information may have significant value during dissection, especially in relation to the recurrent laryngeal nerve, although bleeding can still cause difficulty.

RECOMMENDATIONS

From this review, it has been observed that the most effective role of minimally invasive surgery is for the management of unilateral parathyroid pathological features. This would in effect mean that when all matters concerning the clinical presentation are considered, about 65% of patients with PHPT, at most, would be suitable for consideration of a minimalist approach, but other criteria would need to be taken into account.

To achieve results that parallel those of conventional neck exploration requires careful selection. Selection criteria have been advanced from the serendipitous in relation to the early unilateral approach,⁵ to criteria aimed at producing 100% outcomes from highly focused approaches.²¹ To not take notice of the following criteria may increase the risk of failure when performing minimally invasive parathyroid surgery.

Criteria to be taken into account when planning minimally invasive surgery for PHPT include the following.^{15,30}

1. It is an assumption, and a recommendation, that patients will have had an appropriate and informative discussion with the surgeon. It is also assumed that they will be made aware that they may be progressed from whichever minimal approach is planned to open surgery, if required.

2. Identification of a presumed solitary adenoma, being unequivocal at a single site. The means of identification is by technetium Tc 99m sestamibi and/or ultrasonographic scanning.

3. Exclude all patients with apparent multiple gland disease.

4. Exclude, as far as possible, all likelihood of hyperplasia of the parathyroids or multiple gland disease of any kind: nephric disease, family history of parathyroid disease, or suspected multiple endocrine neoplasia syndrome.

5. Exclude all patients with goiter, previous neck surgery or irradiation of the neck, lithium-associated

PHPT, or abnormal neck structure (skeletal or soft tissue).

6. One group excludes patients with significant heart disease because of the use of carbon dioxide in some endoscopic techniques (Arthur Aufses, MD, FACS, e-mail, November 1998); however, this could be the type of patient benefiting from a minimal approach. It would probably be better to exclude carbon dioxide and use a lifting device in this situation.

7. A surgeon experienced in the conventional technique, who can readily progress to it during a minimalist operation if necessary, should be present at surgery.

8. The use of a QPTH assay is promoted by some as being a useful adjunct in improving specificity and will probably become more widely used in assessing successful removal of the prime pathological features.

Observation of the criteria given would lead to a significant number of patients being candidates for one of the approaches being put forward at this time, probably 15% to 25% of all patients referred for parathyroid surgery. No doubt patient demand will cause this to increase over time.

As the techniques are as yet unproved, it is suggested that the techniques be espoused in trial mode across Australia.

REPORTING AND EVALUATION

To obtain a wide review of the methods in a reasonable time, individual units could adopt different techniques. Randomization would be the ideal, but it may take more patients than are available to complete a study in reasonable time.⁴³

The data to be collected should include the following: (1) total number of patients referred for parathyroidectomy; (2) number of patients meeting the criteria for minimally invasive parathyroidectomy; (3) total number of patients undergoing minimally invasive surgery; (4) newer exclusionary criteria developed based on ongoing experience; (5) operative complications to be recorded and reported, bleeding or hematoma, infection, recurrent laryngeal nerve injury (transient and permanent), temporary or permanent hypocalcemia (a highly unlikely complication), persistent or recurrent hyperparathyroidism, or death; (6) the wound and its length; (7) the cosmetic result; (8) type of anesthesia used during surgery; (9) level of pain described by the patient; (10) length of hospital stay; (11) surgeon's views about the procedure, its safety, and its efficacy; and (12) patient satisfaction.

The careful (graded) collection and comparison of these data against known Australian data for the conventional procedure should assist in determining the rightful role of these newer approaches, providing a minimal data set of information.

The reviewer further suggests that one group use technetium Tc 99m sestamibi mapping and another QPTH estimation in their protocols. Both techniques are coming into wider use in the United States and Europe, and pilot studies would allow Australian surgeons to have local information rather than be "flat footed" at the next level of assessment.

Until such nationwide review and evaluation is completed, the procedure should be put on hold as far as its performance in the community is concerned. The RACS has endorsed ASERNIP-S's recommendation that minimally invasive techniques for PHPT are classified as a level 2.2 procedure, ie, the safety and/or efficacy of the procedure cannot be determined due to an incomplete and/or poor evidence-base. A controlled clinical trial is required (to assess safety and efficacy). The Section of Endocrine Surgery, RACS, has added the caveat that the procedures can only be undertaken in the setting of a controlled study under their supervision. In addition, there are numerous types of minimally invasive parathyroidectomy procedures, and as yet no firmly established method has been accepted as the standard technique. Ongoing monitoring and further studies need to be performed and reported to ensure that minimally invasive parathyroidectomy reaches the high degree of satisfaction noted with bilateral open neck exploration for hyperparathyroidism.

We thank the Australian Commonwealth Department of Health and Family Services, Canberra, for their support of the Australian Safety and Efficacy Register of New Interventional Procedures—Surgical project.

Reprints: Guy J. Maddern, PhD, MS, FRACS, Australian Safety and Efficacy Register of New Interventional Procedures—Surgical, PO Box 688, North Adelaide, South Australia 5006, Australia (e-mail: admin.asernip@racs.edu.au).

REFERENCES

1. Mandl F. Therapeutischer Versuch bei Ostitis fibrosa generalisata mittels Exstirpation eines Epithelkörperchentumors. *Wien Klin Wochenschr.* 1925;50:1343-1344.
2. Allerheiligen DA, Schoeber J, Houston RE, Mohl VK, Wildman KM. Hyperparathyroidism. *Am Fam Physician.* 1998;57:1795-1802.
3. Clark OH. Surgical treatment of primary hyperparathyroidism. *Adv Endocrinol Metab.* 1995;6:1-16.
4. Rude RK. Hyperparathyroidism. *Otolaryngol Clin North Am.* 1996;29:663-679.
5. Delbridge LW, Younes NA, Guinea AI, Reeve TS, Clifton-Bligh P, Robinson BGA. Surgery for primary hyperparathyroidism 1962-1996: indications and outcomes. *Med J Aust.* 1998;168:153-156.
6. Consensus Development Conference statement. *J Bone Miner Res.* 1991;6 (suppl 2):S9-S13.
7. Levin KE, Clark OH. The reasons for failure in parathyroid operations. *Arch Surg.* 1989;124:911-915.
8. Clark OH. Current management of patients with hyperparathyroidism. *Adv Surg.* 1996;30:179-187.
9. Tibblin S, Bondeson AG, Ljungberg O. Unilateral parathyroidectomy in hyperparathyroidism due to single adenoma. *Ann Surg.* 1982;195:245-252.
10. Pyrtok LJ, McClelland AD. Primary surgery for hyperparathyroidism: the lateral approach after preoperative ultrasonographic localization. *Am J Surg.* 1983;145: 503-507.
11. Shen W, Sabanci U, Morita ET, Siperstein AE, Duh QY, Clark OH. Sestamibi scanning is inadequate for directing unilateral neck exploration for first-time parathyroidectomy. *Arch Surg.* 1997;132:969-974.
12. Koslin DB, Adams J, Andersen P, Everts E, Cohen J. Preoperative evaluation of patients with primary hyperparathyroidism: role of high-resolution ultrasound. *Laryngoscope.* 1997;107:1249-1253.
13. Tsukamoto E, Russell CF, Ferguson WR, Laird JD. The role of pre-operative thallium-technetium subtraction scintigraphy in the surgical management of patients with solitary parathyroid adenoma. *Clin Radiol.* 1995;50:677-680.
14. Thompson CT, Bowers J, Broadie TA, Glover JL, Prinz RA, McHenry C. Preoperative ultrasound and thallium-technetium subtraction scintigraphy in localizing parathyroid lesions in patients with hyperparathyroidism. *Am Surg.* 1993; 59:509-512.
15. Chapuis Y, Fulla Y, Bonnichon P, et al. Values of ultrasonography, sestamibi scintigraphy, and intraoperative measurement of 1-84 PTH for unilateral neck exploration of primary hyperparathyroidism. *World J Surg.* 1996;20:835-840.
16. Borley NR, Collins RE, O'Doherty M, Coakley A. Technetium-99m sestamibi parathyroid localization is accurate enough for scan-directed unilateral neck exploration. *Br J Surg.* 1996;83:989-991.

17. Carty SE, Worsley J, Virji MA, Brown ML, Watson CG. Concise parathyroidectomy: the impact of preoperative SPECT 99mTc sestamibi scanning and intraoperative quick parathormone assay. *Surgery*. 1997;122:1107-1116.
18. Norman J, Chheda H. Minimally invasive parathyroidectomy facilitated by intraoperative nuclear mapping. *Surgery*. 1997;122:998-1004.
19. Gagner M. Endoscopic subtotal parathyroidectomy in patients with primary hyperparathyroidism [letter]. *Br J Surg*. 1996;83:875.
20. Yeung GC. Endoscopic surgery of the neck: a new frontier. *Surg Laparosc Endosc*. 1998;8:227-232.
21. Miccoli P, Bendinelli C, Vignali E, et al. Endoscopic parathyroidectomy: report of an initial experience. *Surgery*. 1998;124:1077-1080.
22. National Health and Medical Research Council. A designation of levels of evidence. In: *Guide to the Development, Implementation and Evaluation of Clinical Practice Guidelines: Commonwealth of Australia*. Appendix B. Canberra, Australia: ACT; 1999:56. Available at: <http://www.nhmrc.health.gov.au/publicat/pdf/cp30.pdf>. Accessed February 2, 2000.
23. Petti GHJ, Chonkich GD, Morgan JW. Unilateral parathyroidectomy: the value of the localizing scan. *J Otolaryngol*. 1993;22:307-310.
24. Vogel LM, Lucas R, Czako P. Unilateral parathyroid exploration. *Am Surg*. 1998;64:693-697.
25. Denham DW, Norman J. Cost-effectiveness of preoperative sestamibi scan for primary hyperparathyroidism is dependent solely upon the surgeon's choice of operative procedure. *J Am Coll Surg*. 1998;186:293-305.
26. Ryan JA, Eisenberg B, Pado KM, Lee F. Efficacy of selective unilateral exploration in hyperparathyroidism based on localization tests. *Arch Surg*. 1997;132:886-890.
27. Wei JP, Burke GJ. Analysis of savings in operative time for primary hyperparathyroidism using localization with technetium 99m sestamibi scan. *Am J Surg*. 1995;170:488-491.
28. Worsley MJ, Carty SE, Watson CG. Success of unilateral neck exploration for sporadic primary hyperparathyroidism. *Surgery*. 1993;114:1024-1030.
29. Norman J, Chheda H, Farrell C. Minimally invasive parathyroidectomy for primary hyperparathyroidism: decreasing operative time and potential complications while improving cosmetic results. *Am Surg*. 1998;64:391-396.
30. van Vroonhoven TJMV, van Dalen A. Successful minimally invasive surgery in primary hyperparathyroidism after combined preoperative ultrasound and computed tomography imaging. *J Intern Med*. 1998;243:581-587.
31. *Review Manager* [computer program]. Version 3.1 for Windows. Oxford, England: Cochrane Collaboration; 1998.
32. Gottlieb A, Sprung J, Zheng XM, Gagner M. Massive subcutaneous emphysema and severe hypercarbia in a patient during endoscopic transcervical parathyroidectomy using carbon dioxide insufflation. *Anesth Analg*. 1997;84:1154-1156.
33. Naitoh T, Gagner M, Garciaruiz A, Heniford BT. Endoscopic endocrine surgery in the neck: an initial report of endoscopic subtotal parathyroidectomy. *Surg Endosc*. 1998;12:202-205.
34. Yeung GC, Ng JT. The technique of endoscopic exploration for parathyroid adenoma of the neck. *Aust N Z J Surg*. 1998;68:147-150.
35. Yeung GC, Ng WT, Kong CK. Endoscopic thyroid and parathyroid surgery. *Surg Endosc*. 1997;11:1135.
36. Brunt LM, Jones DB, Wu JS, Quasebarth MA, Meininger T, Soper NJ. Experimental development of an endoscopic approach to neck exploration and parathyroidectomy. *Surgery*. 1997;122:893-901.
37. Norman J, Albrink MH. Minimally invasive videoscopic parathyroidectomy: a feasibility study in dogs and humans. *J Laparoendosc Adv Surg Tech A*. 1997;7:301-306.
38. Miccoli P, Pinchera A, Cecchini G, et al. Minimally invasive, video-assisted parathyroid surgery for primary hyperparathyroidism. *J Endocrinol Invest*. 1997;20:429-430.
39. Gauger PG, Reeve TS, Delbridge LW. Endoscopically-assisted minimally-invasive parathyroidectomy. *Br J Surg*. 1999;86:1563-1566.
40. Malmæus J, Granberg J, Halvorsen G, Johansson H. Parathyroid surgery in Scandinavia. *Acta Chir Scand*. 1988;154:409-413.
41. Vanheerden JA. Presidential address: lessons learned: American Association of Endocrine Surgeons. *Surgery*. 1997;122:979-988.
42. Brunt LM. Endoscopic versus radioguided parathyroidectomy [letter; reply]. *Surgery*. 1998;124:119.
43. Duh QY, Uden P, Clark OH. Unilateral neck exploration for primary hyperparathyroidism: analysis of a controversy using a mathematical model. *World J Surg*. 1992;16:654-662.

IN OTHER AMA JOURNALS

ARCHIVES OF INTERNAL MEDICINE

A New Pharmacological Treatment for Intermittent Claudication: Results of a Randomized, Multicenter Trial

Hugh G. Beebe, MD; David L. Dawson, MD; Bruce S. Cutler, MD; J. Alan Herd, MD; D. Eugene Strandness, Jr, MD; Enoch B. Bortey, PhD; William P. Forbes, PharmD

Background: Effective medication is limited for the relief of intermittent claudication, a common manifestation of arterial occlusive disease. Cilostazol is a potent inhibitor of platelet aggregation with vasodilation effects.

Objective: To evaluate the safety and efficacy of cilostazol for the treatment of intermittent claudication.

Methods: Thirty-seven outpatient vascular medicine clinics at regional tertiary and university hospitals in the United States participated in this multicenter, randomized, double-blind, placebo-controlled, parallel trial. Of the 663 screened volunteer patients with leg discomfort, a total of 516 men and women 40 years or older with a diagnosis of moderately severe chronic, stable, symptomatic intermittent claudication were randomized to receive cilostazol, 100 mg, cilostazol, 50 mg, or placebo twice a day orally for 24 weeks. Outcome measures included pain-free and maximal walking distances via treadmill testing, patient-based quality-of-life measures, global assessments by patient and physician, and cardiovascular morbidity and all-cause mortality survival analysis.

Results: The clinical and statistical superiority of active treatment over placebo was evident as early as week 4, with continued improvement at all subsequent time points. After 24 weeks, patients who received cilostazol, 100 mg, twice a day had a 51% geometric mean improvement in maximal walking distance ($P < .001$ vs placebo); those who received cilostazol, 50 mg, twice a day had a 38% geometric mean improvement in maximal walking distance ($P < .001$ vs placebo). These percentages translate into an arithmetic mean increase in distance walked, from 129.7 m at baseline to 258.8 m at week 24 for the cilostazol, 100 mg, group, and from 131.5 to 198.8 m for the cilostazol, 50 mg, group. Geometric mean change for pain-free walking distance increased by 59% ($P < .001$) and 48% ($P < .001$), respectively, in the cilostazol, 100 mg, and cilostazol, 50 mg, groups. These results were corroborated by the results of subjective quality-of-life assessments, functional status, and global evaluations. Headache, abnormal stool samples or diarrhea, dizziness, and palpitations were the most commonly reported potentially drug-related adverse events and were self-limited. A total of 75 patients (14.5%) withdrew because of any adverse event, which was equally distributed between all 3 treatment groups. Similarly, there were no differences between groups in the incidence of combined cardiovascular morbidity or all-cause mortality.

Conclusion: Compared with placebo, long-term use of cilostazol, 100 mg or 50 mg, twice a day significantly improves walking distances in patients with intermittent claudication. (1999;159:2041-2050)

Reprints: Hugh G. Beebe, MD, Jobst Vascular Center, 2109 Hughes Dr, Toledo, OH 43606 (e-mail: hbeebe@jvc.org).