

# Relative Contributions of Technetium Tc 99m Sestamibi Scintigraphy, Intraoperative Gamma Probe Detection, and the Rapid Parathyroid Hormone Assay to the Surgical Management of Hyperparathyroidism

Alan P. B. Dackiw, MD, PhD; Jeffrey J. Sussman, MD; Herbert A. Fritsche, Jr, PhD; Ebrahim S. Delpassand, MD; Pam Stanford, RN; Ana Hoff, MD; Robert F. Gagel, MD; Douglas B. Evans, MD; Jeffrey E. Lee, MD

**Hypothesis:** Technetium Tc 99m sestamibi scintigraphy, intraoperative gamma probe detection, and the rapid parathyroid hormone assay have been used to permit a directed operation in patients with hyperparathyroidism. We hypothesized that the coordinated use of these techniques might be particularly useful in patients who require a second operation for hyperparathyroidism.

**Design:** Retrospective analysis was performed to determine the specific contribution of these technologies to the surgical management of patients with hyperparathyroidism who underwent evaluation by at least 2 of these techniques between April 1996 and October 1999.

**Setting:** Patients were evaluated and treated by an endocrine tumor surgery group within a tertiary care referral center.

**Patients:** Coordinated application of <sup>99m</sup>Tc-sestamibi scintigraphy, intraoperative gamma probe detection, and/or the rapid parathyroid hormone assay was performed in 32 patients.

**Results:** Twenty-eight of 32 patients had primary hyperparathyroidism, 3 had multiple endocrine neoplasia type 1, and 1 had secondary hyperparathyroidism. The surgical procedure was an initial cervical exploration in 19 and a second operative procedure in 13. Parathyroidectomy was successful in all patients. A directed anatomic operation was performed in 24 patients, including 11 patients who underwent second operative procedures and 9 patients who underwent minimally invasive procedures under local anesthesia. A directed operation was facilitated by sestamibi scan in 22 of 24 patients, intraoperative gamma probe detection in 5 of 23 patients, and the rapid parathyroid hormone assay in 15 of 15 patients.

**Conclusions:** Coordinated application of <sup>99m</sup>Tc-sestamibi scintigraphy, intraoperative gamma probe detection, and the rapid parathyroid hormone assay allows for successful directed reoperative parathyroidectomy; a minimally invasive procedure may be performed in selected patients.

*Arch Surg.* 2000;135:550-557

From the Departments of Surgical Oncology (Section of Endocrine Tumor Surgery), Research Laboratory Medicine, Nuclear Medicine, and Medical Specialties (Section of Endocrine Neoplasia and Hormonal Disorders), The University of Texas M. D. Anderson Cancer Center, Houston; and the Division of Surgical Oncology, University of Cincinnati Medical Center, Cincinnati, Ohio.

**R**ECENT REPORTS have documented that most patients with primary hyperparathyroidism can undergo a directed, anatomic, unilateral operation with a high degree of success and low morbidity using the combination of a preoperative sestamibi scan and either an intraoperative rapid parathyroid hormone (rPTH) assay<sup>1-5</sup> or intraoperative localization of sestamibi-labeled parathyroid tissue by the use of a hand-held gamma detector.<sup>6-8</sup> The latter technique, in particular, has been advocated by some authors as an important component of minimally invasive outpatient parathyroidectomy using very small incisions and local anesthesia.<sup>7,8</sup> Both of these techniques individually have been applied to the treatment of patients undergoing an initial parathyroid exploration and those undergoing a second parathyroid sur-

gery. We report our initial experience comparing our results with these 2 techniques in a series of patients with hyperparathyroidism. This series is unique in that most of these patients were treated using both the intraoperative rPTH assay and intraoperative parathyroid gamma probe localization.

## RESULTS

### PATIENTS AND SURGICAL PROCEDURES

The study group consisted of 32 patients (**Figure 1**). Twenty-eight of these patients had sporadic primary hyperparathyroidism, 3 patients had multiple endocrine neoplasia type 1 (MEN 1), and 1 patient had secondary hyperparathyroidism.

Among the entire group of 32 patients, the surgical procedure performed

## PATIENTS AND METHODS

### PATIENTS

For this retrospective analysis, the study population consisted of 32 patients with biochemically confirmed hyperparathyroidism who underwent evaluation and treatment by the Surgical Endocrinology Section of The University of Texas M. D. Anderson Cancer Center, Houston, between April 1996 and October 1999. All patients underwent a preoperative scan with technetium Tc 99m sestamibi, followed by one or both of 2 intraoperative techniques: preoperative sestamibi injection followed by intraoperative parathyroid localization using a handheld gamma detector and/or intraoperative rPTH assay. A database was created, and assessment of the relative contributions of sestamibi scanning, intraoperative gamma probe detection, and the rPTH assay to the surgical management of these patients was performed.

### <sup>99m</sup>Tc-SESTAMIBI IMAGING

Planar images of the neck and chest in the anterior and posterior projections were obtained approximately 10 to 20 minutes and 2 to 3 hours following intravenous injection of 740 to 1110 MBq of <sup>99m</sup>Tc-sestamibi using a dual-detector gamma camera (Siemens e-cam; Siemens, Hoffman Estates, Ill) with a low-energy, ultra-high-resolution collimator. In some cases, additional delayed images were obtained. In 10 patients, single photon emission computed tomography (SPECT) images were also obtained. The SPECT images were obtained using a dual- or triple-detector gamma camera with a low-energy, ultra-high-resolution parallel-hole collimator at a magnification factor of 1.25 in a 128 × 128 matrix with 45 stops per detector at 40 seconds per stop. Images were processed using a Butterworth filter with Nyquist 9.0 cycles/cm and a cutoff frequency of 0.55 cycles/cm. The SPECT images were presented in coronal, transaxial, and sagittal planes.

### INTRAOPERATIVE GAMMA PROBE DETECTION

Patients underwent intravenous injection of 370 MBq of <sup>99m</sup>Tc-sestamibi 2 to 3 hours before their planned surgical procedures. An 11-mm, handheld gamma counter (Neoprobe Corp,

Dublin, Ohio) was used to measure gamma activity in the neck and upper mediastinum. Intraoperative gamma probe localization was considered to have been successful if abnormal parathyroid tissue that was associated with focal gamma activity was identified (>20% above background).<sup>7</sup>

Intraoperative gamma probe localization was considered to have facilitated a directed anatomic operation when identification of focal gamma activity was used to direct intraoperative dissection or when identification of focal gamma activity *ex vivo* resulted in confirmation of the presence of abnormal parathyroid tissue within a surgical specimen, assisting in a decision to terminate the procedure. Intraoperative gamma probe localization was not considered to have facilitated an operation (despite successful intraoperative gamma probe localization) when localization and identification of abnormal parathyroid tissue was apparent without the use of the gamma probe (ie, there was correct preoperative localization of the abnormal parathyroid tissue by sestamibi scan and identification of the abnormal parathyroid tissue intraoperatively was easily performed following a limited anatomic dissection).

### INTRAOPERATIVE rPTH ASSAY

The intraoperative rPTH assay system (QuiCk IntraOperative Intact PTH; Nichols Institute Diagnostics, San Juan Capistrano, Calif) was used. Venous or arterial blood samples were drawn into EDTA acid and analyzed using a luminometer and washer (Nichols CLS System 400) according to the manufacturer's instructions. The lower limit of detection for the assay was 15.0 pg/mL (1.6 pmol/L). The assay precision ranged from 5.0% to 11.0% (coefficient of variation) for mean values in the range of 29 to 220 pg/mL (3.0-23.2 pmol/L). Determination of rPTH levels was performed on site in the operating room, with a total turnaround time of less than 15 minutes. In most cases, 4 separate samples were drawn: preincision baseline, postincision baseline, 5 minutes after excision, and 10 minutes after excision. A 50% decrease in the rPTH value from baseline was taken as indicative of clinical cure in patients with primary, nonfamilial hyperparathyroidism.<sup>5</sup> Patients undergoing directed, unilateral operations who experienced lesser decreases in rPTH levels following removal of a suspected single adenoma underwent bilateral neck exploration to evaluate for the presence of multigland disease.

represented an initial cervical exploration in 19 and a second surgical procedure in 13. Twelve of these 13 patients had undergone prior cervical explorations for hyperparathyroidism; the remaining patient had undergone a remote prior total thyroidectomy for papillary thyroid cancer. Twenty-four patients had a single adenoma, 3 patients had double adenomas, and 5 patients had multigland hyperplasia (MEN 1, 3 patients; secondary hyperparathyroidism, 1 patient; sporadic hyperplasia, 1 patient). Serum calcium levels normalized postoperatively in all patients. No patient experienced a postoperative recurrent laryngeal nerve injury, and no patient developed postoperative permanent hypoparathyroidism.

A directed anatomic operation was attempted in 26 of the 32 patients and was successfully performed in 24 patients. A patient was considered to have undergone a

directed anatomic operation if either unilateral neck exploration (22 patients) or sternotomy (2 patients) was performed based on preoperative localization studies. The directed surgical procedure performed represented an initial cervical exploration in 13 of 24 patients and a second surgical procedure in 11 of 24 patients. In 9 patients, the directed anatomic operation was performed as a minimally invasive procedure under local anesthesia, with intravenous sedation and monitoring provided by the anesthesia service.

A bilateral neck exploration was performed in 8 (25%) of the 32 patients. Reasons for performing a bilateral exploration rather than a directed operation in these patients were as follows: the need for concurrent thyroidectomy (1 patient), nonlocalization of sestamibi uptake on preoperative sestamibi scan (3 patients), bilat-

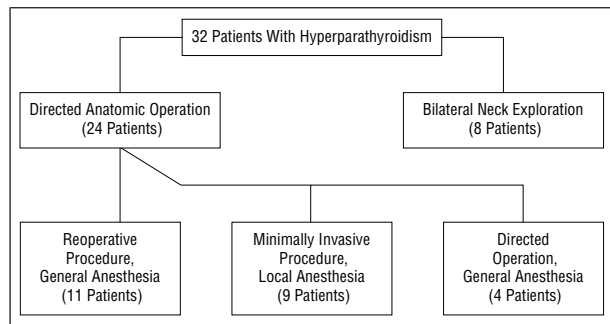


Figure 1. Surgical treatment of 32 patients with hyperparathyroidism.

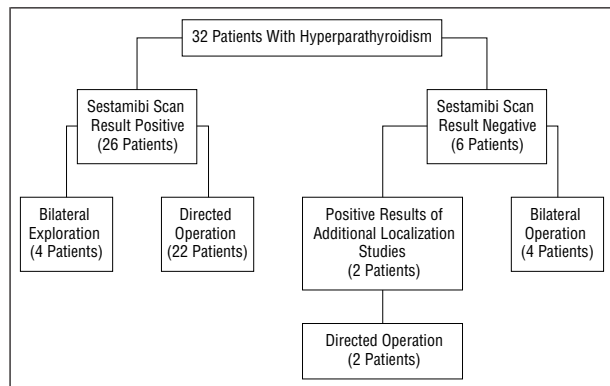


Figure 2. Results of technetium Tc 99m sestamibi scan and surgical procedure performed in 32 patients with hyperparathyroidism.

eral sestamibi uptake on preoperative scan (1 patient), failure of the intraoperative rPTH to decrease by at least 50% after a unilateral (directed) neck exploration (2 patients), and performance of the procedure before availability of the rPTH assay (1 patient).

#### <sup>99m</sup>Tc-SESTAMIBI SCINTIGRAPHY

Preoperative sestamibi imaging was performed in all patients (Figure 2). Directed anatomic operations were successfully performed based on the results of preoperative sestamibi scan localization in 22 of 24 patients: 13 of 13 patients who underwent primary cervical explorations and 9 of 11 patients who underwent reoperative cervical explorations. Parathyroid adenomas in the remaining 2 patients were successfully localized preoperatively despite negative sestamibi scan results. These included one patient in whom a cervical adenoma was identified on magnetic resonance imaging and ultrasonography and a second patient in whom selective venous sampling for intact parathyroid hormone levels successfully localized an intrathymic parathyroid adenoma following nondiagnostic cervical ultrasonography and cervical and thoracic magnetic resonance imaging. Four patients with positive sestamibi scan results underwent bilateral cervical exploration because of bilateral localization of sestamibi on the preoperative scan (1 patient), failure of the intraoperative rPTH to decrease by at least 50% after a unilateral neck exploration (2 patients), or performance of the procedure before the availability of the rPTH assay (1 patient).

Sestamibi imaging correctly identified the location of hyperfunctioning parathyroid tissue in 26 (81%) of 32

patients. Single adenomas were correctly localized in 19 of 26 patients, and multigland disease was successfully identified in the remaining 7 patients. There were no false-positive sestamibi scan results. Six patients had nonlocalizing sestamibi scans. These 6 patients included 2 patients with single adenomas in ectopic locations, 3 patients with single adenomas in normal anatomic locations, and 1 patient with multigland disease.

#### INTRAOPERATIVE GAMMA PROBE LOCALIZATION

Preoperative sestamibi injection followed by intraoperative gamma probe localization was performed in 27 of 32 patients. Intraoperative gamma probe localization was performed in 23 of 24 patients who underwent a successful directed anatomic operation. Intraoperative gamma probe localization of abnormal parathyroid tissue was successful overall in 21 (78%) of 27 patients and in 17 (74%) of 23 patients who underwent a successful directed anatomic operation. Seventeen of the patients who underwent intraoperative gamma probe localization also underwent intraoperative determination of rPTH levels.

Intraoperative gamma probe localization was considered to have facilitated a directed anatomic operation in 5 (22%) of 23 patients. These included 2 patients in whom intraoperative gamma probe localization (directed by the results of the preoperative sestamibi scan) assisted in limiting dissection at the time of reoperative neck exploration. In an additional patient, intraoperative gamma probe localization assisted in limiting dissection during a minimally invasive parathyroidectomy performed as an outpatient procedure under local anesthesia. Finally, intraoperative gamma probe localization was considered to have facilitated parathyroidectomy in 2 patients in whom localization of abnormal parathyroid tissue was only successful ex vivo. One of these patients had a small thymic parathyroid adenoma poorly visualized on the preoperative sestamibi scan. The other patient had MEN 1 and had undergone a prior total cervical parathyroidectomy with parathyroid autografts placed into the left forearm and the right pectoralis major muscle. Ex vivo examination of excised scar and muscle from the site of prior pectoralis autotransplant resulted in the identification of a 3-mm nodule containing focal gamma activity, which was histologically confirmed as hypercellular parathyroid. This information, along with low normal results from an intraoperative rPTH assay, influenced the decision to terminate the procedure.

Of the 6 patients (19%) who had sestamibi scans considered preoperatively to be nonlocalizing, 3 patients nonetheless underwent attempts at intraoperative gamma probe localization. The gamma probe was successful at identifying abnormal parathyroid tissue in all 3 patients. In 2 of 3 patients, a very faint uptake in the location of the intraoperatively identified adenoma could be identified retrospectively on the preoperative sestamibi scan. Two of the 3 patients had undergone SPECT and planar imaging as part of their preoperative sestamibi scintigraphy; SPECT imaging was not helpful in these patients in identifying the parathyroid adenoma. In the first of these 3 patients, despite a nonlocalizing preoperative

sestamibi scan, the intraoperative gamma probe successfully directed dissection toward sestamibi-labeled parathyroid tissue and enabled identification of a left superior parathyroid adenoma. In the second patient, sternotomy followed by *ex vivo* gamma probe examination of the resected thymus resulted in identification of a 7-mm parathyroid that contained focal gamma activity; hypercalcemia was corrected. A third patient had successful intraoperative gamma probe localization of a parathyroid adenoma. However, because of excellent preoperative imaging by magnetic resonance imaging and ultrasound, as well as relatively low-intensity labeling with sestamibi, gamma probe localization did not contribute significantly to the management of this patient.

### rPTH ASSAY

The rPTH assay was performed in 22 of 32 patients, including 15 of 24 patients who underwent a successful directed anatomic operation. In all 15 patients who underwent directed anatomic operations, the decision to terminate the procedure was based on an appropriate decrease in the rPTH level. In 4 of 22 patients, the initial (5- and 10-minute) postexcision rPTH levels decreased by less than 50% of the baseline value, indicating the probable presence of additional abnormal parathyroid tissue. In 3 of these patients, additional exploration resulted in the identification of a second adenoma (2 patients) or multigland hyperplasia (1 patient). Excision of the additionally identified abnormal parathyroid tissue resulted in a further decline in rPTH levels in these patients and postoperative resolution of hypercalcemia. In the fourth patient, partial intraoperative rupture of a parathyroid cyst associated with an adenoma resulted in a persistently high postexcision rPTH level. Cyst fluid analysis documented very high PTH levels within the cyst fluid. Following 4-gland exploration and cervical thymectomy, the operation was terminated. Subsequent evaluation revealed resolution of hypercalcemia, and there has been no evidence for recurrence of hyperparathyroidism in this patient after 12 months of follow-up. The mean decrease in rPTH at 10 minutes following parathyroidectomy in the 21 cases in which rPTH testing was successfully performed was 78% (median, 80%; range, 56.1%-89.8%).

In 4 of 21 patients, results of rPTH altered intraoperative management significantly, emphasizing the value of this technology in complicated patients. One patient with MEN 1 had undergone 2 prior cervical parathyroidectomies and a left forearm parathyroid autograft; preoperative sestamibi scan indicated intense uptake in the neck and lesser uptake at the forearm autograft site. Following removal of a hyperplastic parathyroid gland from the left side of the neck, the rPTH level decreased from 114 to 26 pg/mL (77% decrease). Based on these values, a decision was made not to perform debulking of the forearm parathyroid autograft. This patient has normal intact PTH, serum calcium, and phosphorus levels after tapering off all supplementation 3 months following surgery.

A second patient with MEN 1 had undergone a prior 4-gland cervical parathyroidectomy with parathyroid autografts placed into the left forearm and the right pectoralis major muscle. In this patient, rPTH levels were used

as a guide for debulking of her parathyroid autografts. The pectoralis major autograft was excised, and the left forearm autograft was then debulked twice until the rPTH level decreased from 163 to 26 pg/mL (84% decrease). This patient is asymptomatic while taking low doses of oral calcium and vitamin D supplementation postoperatively; she has normal intact PTH, low normal serum calcium, and normal serum phosphorus levels 1 month following her parathyroid surgery.

A third patient had undergone a 3.5-gland resection for presumed parathyroid hyperplasia before referral and had biochemical evidence for persistent hyperparathyroidism. Preoperative localizing studies suggested the presence of abnormal parathyroid tissue in the mediastinum. A sternal split and thymectomy resulted in the identification of a parathyroid adenoma. The rPTH level decreased intraoperatively from 125 to less than 15 pg/mL (>88% decrease), suggesting that the parathyroid tissue remaining in the neck may have been devascularized at the initial operation. Because of concern that the patient might be hypoparathyroid, a left forearm parathyroid autograft was performed using a small piece of the mediastinal adenoma; the remainder was submitted for cryopreservation. A brief period of asymptomatic postoperative hypoparathyroidism, manifested by low serum calcium and high serum phosphorus levels, responded to calcium and vitamin D supplementation. After tapering off all supplements, this patient had normal intact PTH, serum calcium, and phosphorus levels 6 months postoperatively.

Finally, a 59-year-old woman was transferred to our institution with profound hypercalcemia and an intact PTH level of more than 900 pg/mL (94.8 pmol/L). Sestamibi localized to the left inferior aspect of the central part of the neck. Because of the clinical concern of parathyroid carcinoma, she underwent *en bloc* resection of the left central neck contents. The rPTH level did not normalize at 10 minutes after resection, prompting *ex vivo* examination of the surgical specimen. In addition to a huge left inferior parathyroid neoplasm, the left superior gland was clearly enlarged (approximately 12 × 5 mm). Therefore, the contralateral aspect of the neck was examined, confirming multigland hyperplasia. Subtotal parathyroidectomy was performed, leaving a 4 × 3-mm portion of the right inferior gland *in situ*. Following a period of profound hungry-bone syndrome, the patient is eucalcemic, with an intact PTH level of 44 pg/mL (4.6 pmol/L).

### COMMENT

This series represents the first report, to our knowledge, to directly compare the use of the intraoperative rPTH assay with intraoperative gamma probe localization for treatment of patients with hyperparathyroidism (**Table**). The results of this study confirm the high success rate and low morbidity of parathyroidectomy for patients with primary, secondary, and MEN 1-associated hyperparathyroidism undergoing initial and reoperative procedures when performed by an experienced endocrine surgical group.

Approximately 80% of patients with hyperparathyroidism in this series had accurate localization of abnormal parathyroid tissue preoperatively by sestamibi scan.

**Reports of Technetium Tc 99m Sestamibi Scanning, Intraoperative Gamma Probe Detection, and the Rapid Parathyroid Hormone (rPTH) Assay in Patients With Hyperparathyroidism**

Source, y	Location	No. of Patients Undergoing Initial Operation	No. of Patients Undergoing Second Operation	Technetium Tc 99m Sestamibi Scintigraphy Performed	Intraoperative Gamma Probe Localization Performed	rPTH Assay Performed
Present study	Houston, Tex	19	13	Yes	Yes	Yes
Thompson et al, <sup>4</sup> 1999	Rochester, Minn	0	124	Yes	No	Yes
Irvin et al, <sup>5</sup> 1999	Miami, Fla	0	33	Yes	No	Yes
Moore et al, <sup>9</sup> 1999	Boston, Mass	48	0	Yes	No	Yes
Norman and Denham, <sup>8</sup> 1998	Tampa, Fla	0	24	Yes	Yes	No
Norman and Chheda, <sup>7</sup> 1997	Tampa, Fla	15	0	Yes	Yes	No
Bonjer et al, <sup>6</sup> 1997	Rotterdam, the Netherlands	20	15	Yes	Yes	No
Carty et al, <sup>3</sup> 1997	Pittsburgh, Pa	128	0	Yes	No	Yes
Boggs et al, <sup>1</sup> 1996	Miami, Fla	80	9	Yes	No	Yes
Chapuis et al, <sup>2</sup> 1996	Paris, France	447	24	Yes	No	Yes

A preoperative sestamibi scan, when clearly localizing, was consistently helpful in directing minimally invasive parathyroid surgery and in directing exploration for patients undergoing reoperative surgical procedures. When available, we would always combine preoperative sestamibi imaging with the rPTH assay when performing anatomically directed operations, including minimally invasive operations, to help ensure postoperative resolution of hypercalcemia.

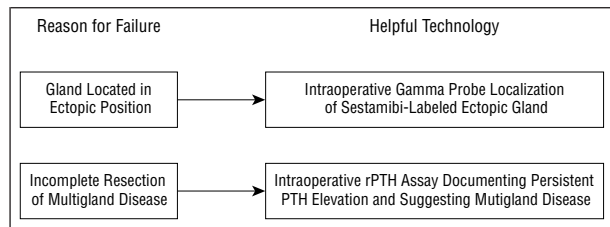
The occasional success in our series with intraoperative gamma probe localization following a nonlocalizing sestamibi scan suggests that selected patients with nonlocalizing sestamibi scans may still be candidates for successful intraoperative gamma probe localization of sestamibi-labeled parathyroid tissue. Although we cannot exclude the possibility that alterations in sestamibi scan technique (eg, inclusion of oblique views<sup>8</sup>) might have resulted in more sensitive and accurate preoperative sestamibi scan identification of the abnormal parathyroid tissue subsequently identified by intraoperative gamma probe localization in the 3 patients in this series, it appears more likely that a combination of factors was responsible: relatively weak labeling of the parathyroid tissue with sestamibi (3 patients), relatively small parathyroid adenomas (2 patients), and background interference (mediastinal structures, 2 patients; multinodular thyroid gland, 1 patient). In these patients, the advantages of the intraoperative gamma probe over the preoperative sestamibi scan included the ability to move interfering structures (thyroid) out of the way of the probe and the ability to perform ex vivo scans.

We do not advocate the use of the intraoperative gamma probe in the absence of good-quality preoperative sestamibi imaging. Furthermore, it is unlikely that routine application of the intraoperative gamma probe to patients with nonlocalizing preoperative sestamibi scans will be helpful. However, an attempt at intraoperative gamma probe localization is reasonable in highly selected patients who have nonlocalizing or equivocal sestamibi scans and are undergoing reoperative procedures. In such patients, it would also be reasonable to suppress thyroid function (if thyroid tissue is present) preoperatively with thyroxine, as advocated by Norman and Denham.<sup>8</sup>

The successful identification of ex vivo parathyroid tissue in 2 patients in this series in the absence of successful preoperative sestamibi localization suggests that the intraoperative gamma probe may be sensitive enough to assist in maximizing the preservation of normal parathyroid tissue in patients undergoing total thyroidectomies and major ablative procedures for selected malignant neoplasms (eg, differentiated thyroid cancer, squamous cell carcinoma of the upper aerodigestive tract). Ex vivo identification of sestamibi-labeled parathyroid tissue in the excision specimen could be accomplished rapidly on the back table and any identified parathyroid glands autografted (following histologic confirmation), thereby potentially preventing postoperative hypoparathyroidism.

We confirm the feasibility of intraoperative gamma probe localization in the majority of patients who have successful preoperative localization with sestamibi. In a few cases in this series, the gamma probe was helpful in directing an operation and limiting the extent of dissection. However, our experience with the application of all 3 technologies (preoperative sestamibi scintigraphy, rPTH assay, and intraoperative gamma probe localization) suggests that the gamma probe was the least essential component for successful operative management of hyperparathyroidism. In the majority of cases, the preoperative sestamibi scan was used to identify the site of exploration, a limited incision was performed, a directed, anatomic operation was carried out, and the parathyroid adenoma was identified and excised. The rPTH assay was then used to confirm biochemical cure, thereby allowing the operation to be terminated. Intraoperative gamma probe localization was neither necessary nor particularly helpful under these circumstances. The gamma probe may still be useful in assisting in the localization of abnormal parathyroid tissue in selected patients, particularly in patients undergoing reoperative surgical procedures.

We confirm that a decrease of the intraoperative rPTH level by at least 50% from baseline values is associated with postoperative resolution of hypercalcemia and clinical cure in patients with primary hyperparathyroidism. Some authors<sup>4</sup> have suggested that a more stringent cutoff of 70% would result in the identification of a higher proportion of patients with multigland disease. The mean and median decreases in rPTH levels in this



**Figure 3.** Potential contributions of intraoperative gamma probe localization and the rapid parathyroid hormone (rPTH) assay to a reduction in the rate of failed parathyroid explorations.

series were both greater than 70%. Only a single patient had a final intraoperative rPTH level that decreased by less than 70%; this patient had a final rPTH level that decreased 56.1% from baseline after identification of a single parathyroid adenoma during a minimally invasive parathyroidectomy; she remains eucalcemic 6 months postoperatively. No patient in this series had evidence of persistent hypercalcemia postoperatively.

The 2 patients with MEN 1 in this series who had intraoperative determination of rPTH had final rPTH values that decreased by 77% and 84%. When using the rPTH assay in patients with MEN 1, we think it is reasonable to apply the target developed by Clary et al<sup>10</sup> of an approximately 80% decrease in rPTH level for patients with secondary hyperparathyroidism and parathyroid hyperplasia; additionally, it is probably desirable to have the final rPTH value in these patients decrease to within the normal range.

The 2 most common causes of failed parathyroid exploration requiring a second surgical procedure are (1) a missed parathyroid adenoma in an ectopic location and (2) incomplete resection of multigland disease.<sup>11</sup> Our results demonstrate that intraoperative gamma probe localization and the rPTH assay provide complementary information that may improve the chances for clinical and biochemical cure. Intraoperative gamma probe localization is particularly helpful in assisting in the identification of ectopic parathyroid adenomas, whereas the rPTH assay assists in the identification and management of patients with multigland disease (**Figure 3**).

In summary, the rPTH assay was consistently helpful in documenting a decrease in intact PTH levels sufficient to predict resolution of hypercalcemia, and the assay was particularly helpful in several clinical situations: (1) predicting clinical cure in patients undergoing a unilateral, minimally invasive parathyroidectomy; (2) indicating the need for bilateral exploration and the likelihood of multigland disease in patients undergoing a unilateral, minimally invasive parathyroidectomy; (3) predicting clinical cure in patients undergoing an anatomically directed reoperative parathyroidectomy; (4) indicating the need for additional resection of hyperplastic parathyroid tissue in patients with secondary hyperparathyroidism and MEN 1; and (5) suggesting the potential need for autografting and cryopreservation in patients with final rPTH values below the lower limit of detection, particularly in patients undergoing a reoperative parathyroidectomy and in patients undergoing near-total parathyroid excisions.

In conclusion, we found that the application of a preoperative parathyroid localization using <sup>99m</sup>Tc-sestamibi

scintigraphy combined with the intraoperative rPTH assay allowed for a successful directed parathyroidectomy in patients undergoing primary and reoperative parathyroidectomy; a minimally invasive approach was often both feasible and well tolerated. Although not routinely essential, in selected patients the addition of intraoperative gamma probe localization was helpful, particularly in the reoperative setting.

Presented at the 107th Scientific Session of the Western Surgical Association, Santa Fe, New Mexico, November 17, 1999.

Reprints: Jeffrey E. Lee, MD, Department of Surgical Oncology, Box 106, The University of Texas M. D. Anderson Cancer Center, 1515 Holcombe Blvd, Houston, TX 77030.

## REFERENCES

1. Boggs JE, Irvin GL III, Molinari AS, Deriso GT. Intraoperative parathyroid hormone monitoring as an adjunct to parathyroidectomy. *Surgery*. 1996;120:954-958.
2. Chapuis Y, Fulla Y, Bonnichon P, et al. Values of ultrasonography, sestamibi scintigraphy, and intraoperative measurement of 1-84 PTH for unilateral neck exploration of primary hyperparathyroidism. *World J Surg*. 1996;20:835-839.
3. Carty SE, Worsley J, Virji MA, Brown ML, Watson CG. Concise parathyroidectomy: the impact of preoperative SPECT 99mTc sestamibi scanning and intraoperative quick parathormone assay. *Surgery*. 1997;122:1107-1114.
4. Thompson GB, Grant CS, Perrier ND, et al. Reoperative parathyroid surgery in the era of sestamibi scanning and intraoperative parathyroid hormone monitoring. *Arch Surg*. 1999;134:699-705.
5. Irvin GL, Molinari AS, Figueroa C, Carneiro DM. Improved success rate in reoperative parathyroidectomy with intraoperative PTH assay. *Ann Surg*. 1999;229:874-879.
6. Bonjer HJ, Bruining HA, Pols HAP, et al. Intraoperative nuclear guidance in benign hyperparathyroidism and parathyroid cancer. *Eur J Nucl Med*. 1997;24:246-251.
7. Norman J, Chheda H. Minimally invasive parathyroidectomy facilitated by intraoperative nuclear mapping. *Surgery*. 1997;122:998-1004.
8. Norman J, Denham D. Minimally invasive radioguided parathyroidectomy in the reoperative neck. *Surgery*. 1998;124:1088-1092.
9. Moore FD Jr, Mannting F, Tanasijevic M. Intrinsic limitations to unilateral parathyroid exploration. *Ann Surg*. 1999;230:382-388.
10. Clary BM, Garner SC, Leight GS Jr. Intraoperative parathyroid hormone monitoring during parathyroidectomy for secondary hyperparathyroidism. *Surgery*. 1997;122:1034-1038.
11. Shen W, Duren M, Morita E, et al. Reoperation for persistent or recurrent hyperparathyroidism. *Arch Surg*. 1996;131:861-869.

## DISCUSSION

Steven A. DeJong, MD, Maywood, Ill: The technology described here allows a directed or minimally invasive approach to treat primary hyperparathyroidism and is currently challenging the traditional approach of bilateral cervical exploration and no preoperative localization. The authors report that preoperative sestamibi scanning and rapid intraoperative PTH determinations are a useful combination to facilitate a directed unilateral and often minimally invasive parathyroidectomy. Intraoperative gamma scintigraphy was not as useful in their patient population. Sestamibi scanning thought to be one of the best preoperative localizing tools for parathyroid disease was still negative in roughly 20% of their patients, and 25% of their patients still underwent bilateral cervical exploration despite the routine use of preoperative sestamibi scanning. This pinpoints some of the limitations of these studies and emphasizes now more than ever the need for experienced parathyroid surgeons.

As reported, these modalities predicted operative cure, limited cervical dissection, and identified patients who needed bilateral cervical exploration in primary and reoperative para-

thyroid surgery. Another interesting use for this technology mentioned in the manuscript is the intraoperative titration of PTH and identification of patients needing parathyroid autografting and/or cryopreservation to prevent or combat the serious problems of postoperative and permanent hypoparathyroidism. This is an important potential application of this technology that should not be overlooked. The usefulness of preoperative localization studies and intraoperative PTH determinations in gamma scintigraphy for persistent or recurrent parathyroid disease to cure parathyroid disease and limit hypoparathyroidism in this study and in general is well documented. The conduct of reoperative parathyroid surgery is by design minimally invasive in that it is a focused attack directed at removing only the localized hyperfunctioning parathyroid gland or glands and limiting the cervical dissection to preserve normal functioning parathyroid tissue. I think the authors showed us many examples of that quite well.

The case made for routine localizing studies before the first cervical exploration is performed for primary hyperparathyroidism, 19 patients in this study, is less clear. The extensive use of preoperative and intraoperative testing in this setting may be seen as the proverbial long run for the short slide unless clear advantages using this technology can be demonstrated regarding total cost, operative time, anesthetic morbidity, recovery time, and cosmetic results.

My own bias is that this will be difficult to do unless the procedure is performed under local anesthesia, patients are discharged on the same day of the procedure, and the cure rates for unilateral and bilateral exploration are equal.

First, would you have cured all of your previously unoperated patients with primary hyperparathyroidism if you had simply used only preoperative sestamibi scanning and intraoperative PTH determination? What would have been the outcome for these patients if no preoperative or intraoperative tools were used?

Second, what were your operative times to address the issue of cost and how do they compare to your bilateral exploration patients? Parathyroidectomy was successful in all your patients, despite a 20% incidence of negative preoperative sestamibi imaging. How persistent would you be in a patient who is having negative studies to get a positive localizing study before you would recommend operation? Generally speaking, these patients usually receive a very costly preoperative workup followed by a traditional bilateral exploration. This has a negative impact on some of the cost issues involved in the minimally invasive approach to parathyroid disease.

Why was the intraoperative gamma technology not as useful in your patients? Can you tell us a little bit about the length of follow-up, especially considering that 3 patients in your study had double adenomas. Do you think that this raises some cause for concern in using unilateral approaches given this data?

Finally, can you tell us how you selected your 9 patients for local anesthesia and maybe some of the problems that you encountered with this technique?

**Philip D. Schneider, MD, Sacramento, Calif:** A paper from a prestigious society such as this should not go out of here without the strongest possible caveat. The potential exists for creating a procedure that is not only more expensive but also carries higher risk. Although these are important techniques, there are some things that need to be addressed.

As an academic for all of my career, I have a personal mission to keep general surgeons involved in doing this kind of surgery and, particularly, the primary operations—safety is paramount. But I think that this technique has some potential for misinterpretation by unskilled general surgeons. Particularly, I would like to caution them about the data from Kenneth Kern, who, as you know, is a surgeon and a lawyer who has looked at 20 years of malpractice litigation in the United States and

has particularly looked at technical reasons why general surgeons are sued. The most common technical misadventures leading to malpractice suits are cranial nerve injuries during head and neck surgery. Some of these are hypoglossal nerve injuries with carotid surgery; some of these are spinal accessory nerve injuries with posterior triangle node biopsies; but the vast majority are recurrent nerve injuries during thyroid/parathyroid surgery. Limited surgery in the neck is a prescription for disaster. Exposure is very critical in parathyroid surgery, and anatomic approaches must be employed.

The potential exists for unsophisticated application of these techniques and creation of more cranial nerve injuries, particularly recurrent nerve injury.

My question for the authors is how much morbidity do you really save with a limited operation and is that cost justified by what may be higher risk if this approach is disseminated widely and uncritically?

**Norman W. Thompson, MD, Ann Arbor, Mich:** I would point out that this group is a sophisticated group. They are all very experienced. In fact, one of the authors trained at the University of Michigan before he went to the M. D. Anderson Hospital. And this represents a first paper that really compares and analyzes all 3 of the newer techniques that have evolved in the last decade as applied to parathyroid reoperation and initial exploration.

If one recalls, historically in 1991 the NIH [National Institutes of Health] Consensus said that localization procedures were not recommended because they were not cost-effective. Sestamibi evolved in 1992 and quickly became the nonlocalization procedure of choice. Some have claimed that 90% of parathyroid single gland disease would be detected by its use. We know that the figure of 80% given here is a much more common figure in most institutions. It may be lower than that in some. In reoperative cases it's considerably lower than that. In our own experience, it is only about 50%. That's true in a number of centers where patients are referred after a sestamibi scan is negative. So it is a very select group, particularly with the reoperative cases.

So in the M. D. Anderson experience with these 32 cases, 80% were then subject to a localized directed procedure, and I would point out that only if you have a positive scan or localization can you then apply the gamma probe, the magic wand, as some have claimed, to a directed procedure. The same with the utilization of the rapid assay, both techniques that have been developed only in the last few years.

The authors have addressed all of these issues and have found that the rapid assay was particularly valuable. I would like to ask them whether they feel that any localization directed operation is justified without the availability of the PTH assay, because there is no way of proving whether you have double adenomas or multiple gland disease.

A point they make in their paper that is very important for everybody to recognize is that no localization study rules out multiple gland disease when it is positive for what appears to be a single gland.

Finally, the *radioguided procedure* is a misnomer; it's a sestamibi-guided procedure. The radioguided procedure they said was useful in only 5 of 23 cases. They were generous in saying that it helped them. They had 2 *ex vivo* cases where if they had sectioned their specimens very carefully they would have found the parathyroid disease that they detected with a probe. For the other 3 cases, I would ask whether they would have found those adenomas with or without the probe.

This is a paper that everyone should read for the details because an awful lot of information is being given out.

**Don Melvin Morris, MD, Albuquerque, NM:** When do you do your scanning prior to the operation? Is it done the day before or just before surgery, and if you have done it at differ-

ent times, did that affect your results? Was the test more or less useful in patients with prior neck operations, especially on the thyroid?

**Dr Lee:** I will start by reinforcing some of the statements made by Drs DeJong and Schneider: the most important localization procedure for patients undergoing surgery for hyperparathyroidism remains to “localize” an experienced parathyroid surgeon. We do not advocate widespread, unconsidered application of these technologies to patients with hyperparathyroidism.

Drs DeJong and Thompson both asked, in effect, whether we would have achieved equivalent results without the use of intraoperative gamma probe localization. I believe we most likely would have achieved equivalent results in all these patients without the use of the gamma probe. There were 5 patients in whom use of the gamma probe was somewhat helpful; in these 5 patients, the gamma probe facilitated their operation. However, in none of these 5 patients was the gamma probe essential to achieving a successful result.

Dr DeJong also asked whether we would have achieved equivalent results if we had not used any of these preoperative or intraoperative tools. Without preoperative sestamibi localization and the intraoperative rapid parathyroid hormone assay, all the patients who presented with primary hyperparathyroidism who had not undergone prior neck surgery would have undergone a standard 4-gland bilateral cervical exploration under general anesthesia; I expect that we would have achieved equivalent and successful results in that patient population without the use of these technologies. On the other hand, we are particularly interested in the subgroup of patients whose hyperparathyroidism is the most difficult to control, including patients with MEN who have had several prior cervical operations. In this patient population, the rapid parathyroid hormone assay can be particularly helpful in achieving an optimum result. For these patients, optimum results are most likely achieved when the final intraoperative rapid parathyroid hormone level is in the low normal range.

Drs DeJong and Schneider addressed the issue of the costs associated with these technologies. With regard to the group of patients with recurrent, persistent, or MEN-associated hyperparathyroidism, the issue of costs is a clearer one. Currently, even without the addition of the cost of the rapid intraoperative hormone assay, we spend a great deal of money on this group of patients, including the routine performance of multiple preoperative localization studies. In this group of complex patients, the rapid parathyroid hormone assay adds to our armamentarium of helpful tests, adds marginally to the cost of taking care of these patients, assists in ensuring a satisfactory result, and may reduce the need for reoperations. Considering particularly the group of patients with MEN-associated hyperparathyroidism, in the long term for these patients there could in fact be cost re-

ductions. The issue of costs with regard to patients with primary hyperparathyroidism is a more difficult one; I am not necessarily an advocate or proponent of using these technologies as a uniform approach at this time for treatment of patients with primary hyperparathyroidism who have not had prior neck surgery. Bilateral neck exploration remains a gold standard that we have to live up to. Nonetheless, it is clear from several reports of large series of patients with primary hyperparathyroidism who have undergone preoperative localization followed by selected, directed operations using either the rapid intraoperative parathyroid hormone assay or intraoperative gamma probe localization that at least equivalent results in terms of short-term outcome can be achieved with a localized procedure in selected patients. This approach can be expensive, however. The increased costs associated with the additional testing involved must be balanced against tangible and intangible cost savings. I agree with Dr DeJong that to realize a cost saving in the group of patients with primary previously unoperated hyperparathyroidism one should do most of these procedures as an anatomically limited, outpatient operation under local anesthesia. The cost issue for this group of patients remains an open one; ultimately, our future practices for these patients will probably be driven in part by what our patients prefer, in much the same way that the demand for many laparoscopic procedures has been driven in part by patient preference.

Intraoperative gamma probe localization was not as helpful in our patient population compared with the published experiences of some other authors for at least 2 reasons. First, our series included a relatively large proportion of patients with multigland disease; in patients with multigland disease, intraoperative localization with the gamma probe was less helpful. Second, in our comparison of intraoperative gamma probe localization to the rapid parathyroid hormone assay, intraoperative gamma probe localization was overall a less helpful technology. Approximately 80% of the information that one obtains from using the gamma probe is already available from the preoperative sestamibi scan. Therefore, in most cases, and especially in straightforward cases, an experienced parathyroid surgeon can review the sestamibi scan and make a regionally appropriate incision based on the sestamibi image; one's knowledge of the local anatomy, and to a lesser extent the details of the sestamibi image, then directs one where to look for the abnormal parathyroid gland.

Finally, in response specifically to Dr Schneider, we had no recurrent laryngeal nerve injuries in this series. I hope and expect that experienced parathyroid surgeons, despite the fact that they are doing a limited operation, will continue to do an anatomically directed operation. Our experience and the published experiences of others performing these directed operations support that assertion.

## IN OTHER AMA JOURNALS

### ARCHIVES OF INTERNAL MEDICINE

#### Antipyretic Therapy: Physiologic Rationale, Diagnostic Implications, and Clinical Consequences

Karen I. Plaisance, MD; Philip A. Mackowiak, MD

**V**arious treatments have been used to suppress fever since antiquity. Surprisingly, few studies have been performed to ascertain the physiologic consequences of antipyresis and validate the rationale behind such therapy. More importantly, it has not been established conclusively that the benefits of antipyretic therapy outweigh its risks. The present review considers these issues in light of currently available data and formulates guidelines for antipyretic therapy based on these data. (2000;160:449-456)

Reprints: Philip A. Mackowiak, MD, the Medical Care Clinical Center, Veterans Affairs Maryland Health Care System, 10 N Greene St, Baltimore, MD 21201.