

# Resectional Treatment for Thyroid Cancer With Tracheal Invasion

## A Long-term Follow-up Study

Chih-Chieh Yang, MD; Chen-Hsen Lee, MD; Liang-Shun Wang, MD; Biing-Shin Huang, MD; Wen-Hu Hsu, MD; Ming-Hsiung Huang, MD

**Hypothesis:** Transmural invasion of the trachea by well-differentiated thyroid carcinomas is a locally advanced disease condition. It frequently causes deaths owing to airway obstruction. We hypothesized that resection of the invaded trachea followed by primary anastomosis provides the opportunity for cure.

**Design:** A retrospective review study of medical records.

**Setting:** The surgical department of a tertiary referral center.

**Patients:** Eight patients with well-differentiated thyroid carcinomas, complicated with tracheal invasion resulting in bleeding and airway obstruction, operated on by tracheal resection and immediate anastomosis, were included.

**Interventions:** All patients received total thyroidectomy and neck lymph node dissection as well as segmental tracheal resection followed by primary reconstruction. Postoperative radioactive sodium iodine I 131

treatment and suppression therapy with thyroxine were applied to all of them.

**Main Outcome Measure:** Postoperative follow-up of serum levels of human thyroglobulin and abnormal radioactive iodine <sup>131</sup>I from whole body scan.

**Results:** Seven patients are alive. Of these patients, 5 had no evidence of disease; (3 had no evidence of cancer for more than 10 years' follow-up), 2 had regional lymph node metastasis, and 1 had lung metastases. The remaining patient had anastomotic site recurrence with airway obstruction and needed tracheostomy to relieve stridor. She was lost to follow-up 39 months after undergoing the initial operation.

**Conclusions:** Patients with mucosal invasion of the trachea by well-differentiated thyroid carcinomas should be treated by surgical resection followed by primary reconstruction when technically feasible. This facilitates postoperative care, and it is possible to achieve long-term survival with improvement of the quality of life and possible cures.

*Arch Surg.* 2000;135:704-707

From the Departments of Emergency Medicine (Drs Yang and Lee) and Surgery (Drs Lee, Wang, B.-S. Huang, Hsu, and M.-H. Huang), Veterans General Hospital-Taipei, and National Yang-Ming University, Taipei, Taiwan.

**P**ATIENTS WITH well-differentiated thyroid carcinomas (WDTCs) may, on occasion, be initially seen with hemoptysis or dyspnea caused by airway obstruction. More commonly, tracheal invasion is identified by bronchoscopy or by the surgeon at the time of thyroidectomy. Fifty-eight percent or more of the deaths in the late stages of thyroid cancers are caused by asphyxia or lung metastases with secondary infection.<sup>1,2</sup> The usual treatment of carcinoma invading the trachea is by "shaving" the tumor off the trachea. The postoperative administration of radioactive iodine or external irradiations is expected to control residual neoplasm.<sup>3</sup> Although this may be initially effective, the neoplasm often recurs. With the improvement of tracheal surgical techniques, invasive carcinoma

can be resected followed by immediate reconstruction of the trachea.<sup>4</sup> This is a retrospective study of 8 patients with WDTCs invading the trachea whose primary treatment was surgical resection and primary anastomosis.

## RESULTS

No major postoperative complications occurred in the 8 patients except for 1 case of a leak at the anastomotic site that was treated conservatively. Five patients are without evidence of disease after follow-up ranging from 14 to 183 months, with a mean of 91 months (**Table**). The serum levels of human thyroglobulin in these patients were all below 30 ng/mL and their annual follow-up <sup>131</sup>I whole body scan was free of any abnormality.

Of the 3 remaining patients, one patient (case 6) had a recurrence in a re-

## PATIENTS, MATERIALS, AND METHODS

From January 1, 1983, to December 31, 1998, 8 patients with invasion of the trachea by WDTCs were treated by resection of the trachea and immediate anastomosis at the Veterans General Hospital-Taipei, Taipei, Taiwan. The diagnosis was established by preoperative endoscopy or by the surgeon at the time of the thyroidectomy. Four patients were initially seen with life-threatening conditions, manifested by intratracheal bleeding or obstruction of the airway. Two were men and 6 were women, aged from 22 to 78 years. Six of the invasive neoplasms were papillary carcinomas, and 2 were follicular cancers. All of the patients were treated by total thyroidectomy and dissection of the neck as well as segmental resection of the trachea followed by primary reconstruction. Frozen sections were done to ensure that the surgical margins of the trachea were free of neoplasm in 5 cases.

Postoperatively, the patient's neck was kept in a flexed position for 5 to 7 postoperative days by suturing the skin of the chin to the skin of chest. The endotracheal tubes were removed on the third postoperative day. Radioactive sodium iodine I 131 was administered 6 weeks later at a dosage of 3700 MBq and the patient was given suppressive doses of thyroxine, 100 to 150 µg/d. All 8 patients were followed up in the clinics (every 3 months) by physical examination, endoscopy, serum levels of human thyroglobulin, and when indicated, by <sup>131</sup>I whole body scan.

After the thyroid gland was resected, the segment of the trachea invaded by neoplasm was mobilized circumferentially. This was done 1 cm above and below the segment to be resected by sharp dissection and as close to the

tracheal wall as possible. The recurrent laryngeal nerves were clearly defined above and below the involved area. The trachea was divided transversely through uninvolved tissue immediately above and below the segment to be resected. The distal trachea was mobilized to facilitate the approximation of the cut ends of the trachea. Stay sutures, 2-0 polyglactin (Vicryl), were placed in the midline anteriorly and also on each side at the junction of the cartilaginous and membranous portions of the trachea, approximately 1 ring away from the divided edge. Following division of the trachea, the nasal endotracheal tube was pulled back into the proximal airway. The distal trachea was intubated with a flexible, cuffed-armored endotracheal tube. The trachea was then divided above the lesion through uninvolved tissue, and stay sutures were placed to display the tracheal margin (**Figure, left**). A frozen section of the tracheal margin was done. The anastomosis was begun by placing a row of interrupted sutures (4-0 polyglactin or polypropylene [Prolene]) in the posterior portion of the membranous trachea. These sutures were placed at 2- to 3-mm intervals, taking approximately a 3-mm bite of tracheal tissue on each side of the tracheal margin. The sutures were placed by beginning posteriorly in the middle of the membranous trachea and progressing around each side to the anterior portion. The endotracheal tube was removed. The nasotracheal tube was pushed downward past the anastomotic site.

The ends of the trachea were approximated and the 2-0 polyglactin stay sutures were tied. The 4-0 sutures were tied with the knots located exteriorly, beginning in the midline anteriorly and working to the back on both sides (**Figure, right**). The wound was closed with a drain as usual. Finally, a strong suture was placed between the skin of the chin and the skin of the anterior chest to maintain flexion of the neck for 5 to 7 postoperative days.

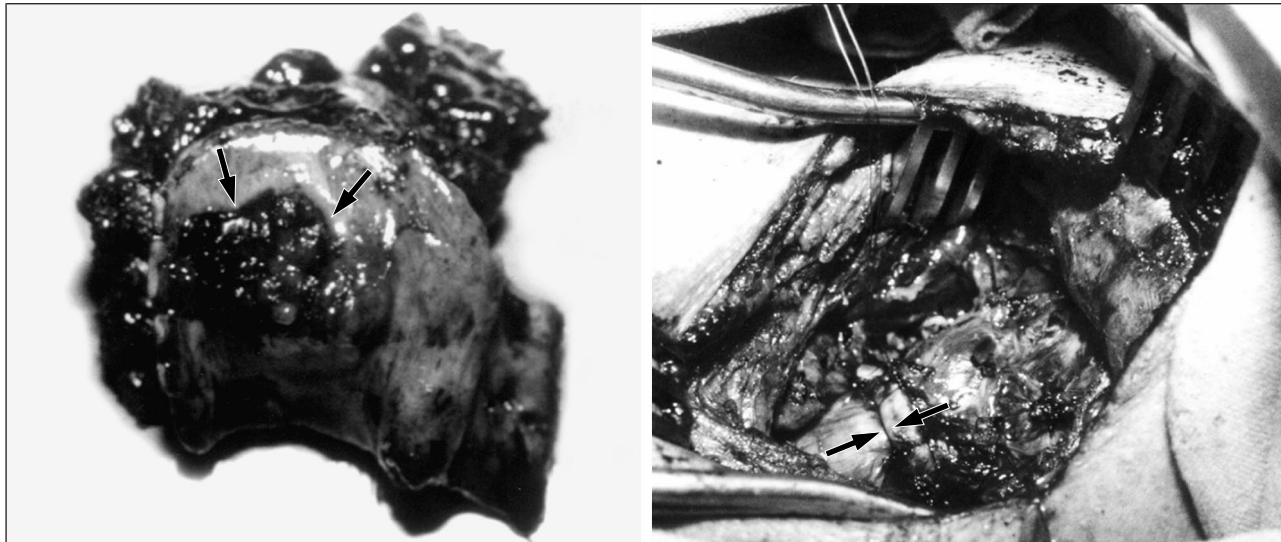
gional lymph node in the neck 56 months later. The lymph node was removed and 3700 MBq of <sup>131</sup>I treatment was given. She was still alive at the time of her last follow-up visit 71 months after anastomosis. A second patient (case 7) developed pulmonary metastases 3 months later and was given 4810 MBq of <sup>131</sup>I. Thirty-five months later a metastasis in a regional lymph node was found and an additional dose of 4810 MBq <sup>131</sup>I treatment was administered. She was alive 48 months later. A third patient (case 8) developed a recurrence at the anastomotic site with obstruction of the airway 17 months later. She required a tracheostomy. She was lost to follow-up after 39 months.

### COMMENT

The prognosis for well-differentiated carcinomas worsens when neoplasm invades the trachea. The cause of death in nearly half of the fatal cases of papillary carcinomas is caused by obstruction of the trachea.<sup>2,5</sup> In addition, the rate of survival for patients treated by incomplete resection of the involved trachea is much worse than those patients treated by complete resection.<sup>6-8</sup> For many years only palliative surgery was employed in the treat-

ment of patients with tracheal invasion by thyroid carcinomas.<sup>9,10</sup> However, with progress in tracheal surgical techniques, resection of portions of the trachea with primary anastomosis is feasible. This is becoming the treatment of choice at our and other institutions.<sup>5,6,11-14</sup> One of the difficulties associated with this procedure is to accurately assess preoperatively the extent of neoplasm within the trachea. Ishihara et al<sup>13</sup> recommend endoscopic examination of the trachea, but also stress the difficulty of accurately assessing the extent of invasion by this technique. Nakao et al<sup>11</sup> recommend endoscopy and computed tomography as part of the preoperative evaluation of a patient. They also stress the need to examine the margins of the resected trachea with frozen sections, as proposed by Mathey et al,<sup>4</sup> to lessen the incidence of recurrences at the anastomotic site. In this study, there were no anastomotic recurrences in the 5 patients in whom the tracheal margins were evaluated by frozen sections. In contrast, there was 1 recurrence in 3 patients in whom no frozen section evaluations were done.

The complete resection of the trachea to remove neoplasm that does not invade the mucosa is controversial.<sup>15,16</sup> Neoplastic involvement of the trachea without mucosal involvement usually has a favorable outcome.



Left, The resected segment of trachea invaded by a papillary carcinoma of the thyroid. The arrows indicate the transmural invasion of cancer. Right, The trachea shows postprimary reconstruction after segmental resection. The arrows indicate the anastomosis.

#### Clinical Data of Patients Who Underwent Tracheal Resection

Patient No./ Sex/Age, y	Symptoms	Duration of Symptoms, mo	Tumor Size in Diameter, cm	Pathologic Type	Transmural Invasion	Lymph Node Metastasis	Cut End Frozen Section	No. of Resected Rings	Outcome*	Follow-up, mo
1/M/54	Hoarseness	1	3.5	Follicular	Yes	No	No	2	NED	183
2/M/58	Hemoptysis	12	3	Papillary	Yes	No	Yes	4	NED	179
3/F/35	Neck pain	2	1.5	Papillary	No	No	Yes	2	NED	155
4/F/50	Neck mass	24	6	Papillary	Yes	Yes	Yes	6	NED	41
5/F/22	Neck mass	24	3	Papillary	No	Yes	Yes	2	NED	14
6/F/68	Stridor and hemoptysis	5	5	Papillary	Yes	Yes	Yes	2	LR	71
7/F/50	Stridor	2	5	Papillary	Yes	Yes	No	4	DM + LR	48†
8/F/78	Hemoptysis	1	7	Follicular	Yes	No	No	7	AR	39‡

\*NED indicates no evidence of disease; LR, local recurrence; DM, distal metastases; and AR, anastomotic site recurrence.

†Patient experienced leakage at the anastomotic site.

‡Patient lost to follow-up.

However, a larger area of mucosal invasion may limit the feasibility of partial tracheal resection because it may lead to kinking or stenosis of the trachea after repair. In our experience, resection of the trachea followed by end-to-end anastomosis is safe and effective and is the preferred method of treatment. The unpredictable results associated with “shaving” followed by treatment with radioactive iodine lead us to favor resection and primary anastomosis. The contraindications include extensive involvement of the trachea, such that 6 or more tracheal rings need to be resected, or simultaneous invasion of the esophagus. One of the major advantages of tracheal resection is the immediate and effective relief of intratracheal bleeding and the symptoms of obstruction. The subsequent care of the patients is also significantly facilitated. In addition, 3 of 7 patients have survived for more than 10 years without evidence of recurrent disease.

Therefore, it is our opinion that the possibility of resection of the trachea with primary anastomosis should be considered when there are signs and symptoms that suggest the presence of tracheal mucosal invasion in patients with WDTCs. Bronchoscopy and computed tomography

should be done preoperatively in such patients. If unexpected invasion of the trachea is found at the time of thyroidectomy for treatment of a WDTC, intraoperative bronchoscopy through the endotracheal tube is helpful. If technically feasible, resection of the trachea with end-to-end anastomosis should be done. This procedure may result in long-term survival and possible cures.

Reprints: Chen-Hsen Lee, MD, Department of Emergency Medicine, Veterans General Hospital, 201, Section 2, Shih-Pai Road, Taipei, Taiwan, Republic of China (e-mail: chlee@vghtpe.gov.tw).

#### REFERENCES

- Silliphant WM, Klinck GH, Levitin MS. Thyroid carcinoma and death: a clinicopathological study of 193 autopsies. *Cancer*. 1964;17:513-525.
- Lin CK, Lee CH, Lui WY, et al. The result of the treatment of thyroid cancer: a retrospective study. *J Formos Med Assoc*. 1985;84:482-493.
- Grillo HC, Zannini P. Resectional management of airway invasion by thyroid carcinoma. *Ann Thorac Surg*. 1986;42:287-298.
- Mathey J, Binet JP, Galey JJ, Evrard C, Lemoine G, Denis S. Tracheal and tracheobronchial resections: technique and results in 20 cases. *J Thorac Cardiovasc Surg*. 1966;51:1-13.

5. Ishihara T, Yamazaki S, Kobayashi K, et al. Resection of the trachea infiltrated by thyroid carcinoma. *Ann Surg.* 1982;195:496-500.
6. Tsumori T, Nakao K, Miyata M, et al. Clinicopathologic study of thyroid carcinoma infiltrating the trachea. *Cancer.* 1985;56:2843-2848.
7. Ishihara T, Kobayashi K, Kikuchi K, Kato R, Kawamura M, Ito K. Surgical treatment of advanced thyroid carcinoma invading the trachea. *J Thorac Cardiovasc Surg.* 1991;102: 717-720.
8. Melliere DJM, Ben Yahia NE, Bec quemin JP, et al. Thyroid carcinoma with tracheal or esophageal involvement: limited or maximal surgery? *Surgery.* 1993; 113: 166-172.
9. Breaux EP Jr, Guillamondegui OM. Treatment of locally invasive carcinoma of the thyroid: how radical? *Am J Surg.* 1980;140:514-517.
10. Cody HS III, Shah JP. Locally invasive, well-differentiated thyroid cancer: 22 years' experience at Memorial Sloan-Kettering Cancer Center. *Am J Surg.* 1981;142: 480-483.
11. Nakao K, Miyata M, Izukura M, Monden Y, Maoda M, Kanashima Y. Radical operation for thyroid carcinoma invading the trachea. *Arch Surg.* 1984;119:1046-1049.
12. Pearson FG, Cooper JD, Nelems JM, Van Nostrand AW. Primary tracheal anastomosis after resection of the cricoid cartilage with preservation of recurrent laryngeal nerves. *J Thorac Cardiovasc Surg.* 1975;70:806-816.
13. Ishihara T, Kikuchi K, Ikeda T, et al. Resection of thyroid carcinoma infiltrating the trachea. *Thorax.* 1978;33:378-386.
14. Nomori H, Kobayashi K, Ishihara T, et al. Thyroid carcinoma infiltrating the trachea: clinical, histologic, and morphometric analysis. *J Surg Oncol.* 1990;44: 78-83.
15. Lipton RJ, McCaffery TV, Van Heerden JA. Surgical treatment of invasion of the upper aerodigestive tract by well-differentiated thyroid carcinoma. *Am J Surg.* 1987;154:363-367.
16. Ozaki O, Sugino K, Mimura T, Ito K. Surgery for patients with thyroid carcinoma invading the trachea: circumferential sleeve resection followed by end-to-end anastomosis. *Surgery.* 1995;117:268-271.

#### IN OTHER AMA JOURNALS

##### ARCHIVES OF INTERNAL MEDICINE

##### Low-Molecular-Weight Heparin vs Heparin in the Treatment of Patients With Pulmonary Embolism

Russell D. Hull, MBBS, MSc; Gary E. Raskob, PhD; Rollin F. Brant, PhD; Graham F. Pineo, MD; Gregory Elliott, MD; Paul D. Stein, MD; Alexander Gottschalk, MD; Karen A. Valentine, MD, PhD; Andrew F. Mah; for the American-Canadian Thrombosis Study Group

**Background:** Pulmonary embolism (PE) occurs in 50% or more of patients with proximal deep-vein thrombosis. Low-molecular-weight heparin treatment is effective and safe in patients with deep vein thrombosis and may also be so in patients with PE. Recent rigorous clinical trials have established objective criteria for determining a high probability of PE by perfusion lung scanning.

**Objective:** To compare low-molecular-weight heparin with intravenous heparin for the treatment of patients with objectively documented PE and underlying proximal deep vein thrombosis.

**Methods:** In a multicenter, double-blind, randomized trial, we compared fixed-dose subcutaneous low-molecular-weight heparin (tinzaparin sodium) given once daily with dose-adjusted intravenous heparin given by continuous infusion using objective documentation of clinical outcomes. Pulmonary embolism at study entry was documented by the presence of high-probability lung scan findings.

**Results:** Of 200 patients with high-probability lung scan findings at study entry, none of the 97 who received low-molecular-weight heparin had new episodes of venous thromboembolism compared with 7 (6.8%) of 103 patients who received intravenous heparin (95% confidence interval for the difference, 1.9%-11.7%;  $P = .01$ ). Major bleeding associated with initial therapy occurred in 1 patient (1.0%) who was given low-molecular-weight heparin and in 2 patients (1.9%) given intravenous heparin (95% confidence interval for the difference, -2.4% to 4.3%).

**Conclusions:** Low-molecular-weight heparin administered once daily subcutaneously was no less effective and probably more effective than use of dose-adjusted intravenous unfractionated heparin for preventing recurrent venous thromboembolism in patients with PE and associated proximal deep vein thrombosis. Our findings extend the use of low-molecular-weight heparin without anticoagulant monitoring to patients with submassive PE. (2000;160:229-236)

Reprints: Russell D. Hull, MBBS, MSc, Thrombosis Research Unit, 601 S Tower, Foothills Hospital, 1403-29 St NW, Calgary, AB Canada T2N 2T9 (e-mail: [jeanne.sheldon@CRHA-Health.ab.ca](mailto:jeanne.sheldon@CRHA-Health.ab.ca)).