

# Ultrasonographic Characteristics of Thyroid Nodules

## Prediction of Malignancy

Eisuke Koike, MD; Shiro Noguchi, MD, PhD; Hiroyuki Yamashita, MD, PhD; Tsukasa Murakami, MD, PhD; Akira Ohshima, MD, PhD; Hitoshi Kawamoto, PhD; Hiroto Yamashita, MD, PhD

**Background:** High-resolution real-time ultrasonography (US) can detect characteristics of thyroid nodules, but the US differentiation between malignant nodules and benign nodules is not well described.

**Hypothesis:** Ultrasonography is useful for predicting malignancy of thyroid nodules.

**Design:** A retrospective study of 329 thyroid nodules ( $\geq 5$  mm) in 309 patients comparing US characteristics and pathological results.

**Setting:** A center for the treatment of thyroid diseases where about 1400 thyroid operations are performed per year.

**Patients:** Between January 1 and June 30, 1999, 309 patients were examined by US before thyroidectomy.

**Main Outcome Measure:** The US characteristics to predict malignancy for both follicular and nonfollicular neoplasms by means of multiple logistic regression analysis.

**Results:** The sensitivity of preoperative US diagnosis was 86.5% for nonfollicular neoplasms and 18.2% for follicular neoplasms. The specificity was 92.3% and 88.7%, respectively. According to multiple logistic regression analysis, margin, shape, echo structure, echogenicity, and calcification were reliable indication of malignancy in nonfollicular neoplasms. According to a receiver operating characteristic curve constructed from this multiple logistic regression analysis, the best point not to overlook malignancy is the point at which sensitivity is 94% and specificity is 87%. The probability of malignancy at this point is greater than 0.2. For follicular neoplasms, ultrasonographic diagnosis was unreliable, even when multiple logistic regression analysis was applied.

**Conclusion:** We can predict malignancy of nonfollicular neoplasms of the thyroid by using multiple logistic regression analysis based on only 5 features: margin, shape, echo structure, echogenicity, and calcification.

*Arch Surg.* 2001;136:334-337

ULTRASONOGRAPHY (US) is useful for evaluation of thyroid nodules because of its safety, noninvasiveness, nonradioactivity, and effectiveness. Presently, high-resolution real-time US not only detects the presence, site, number, and size of thyroid nodules but also clearly shows the characteristics of thyroid nodules. However, the US differentiation between malignant nodules and benign nodules is not well described.<sup>1-12</sup> Some authors have reported US diagnosis of thyroid nodules of all types with relatively high sensitivity ranging from 74% to 81%,<sup>3,6,7,9</sup> but no formulas based on analysis of US characteristics are available to predict malignancy. Any useful formula should be simple and accurate for clinical use. We therefore evaluated US characteristics of thyroid

nodules prospectively and analyzed the probability of malignancy on the basis of multiple logistic regression analysis.

## RESULTS

For preoperative US diagnosis, the overall sensitivity was 81.8% and the overall specificity was 90.6%. For the 265 nonfollicular neoplasms, sensitivity and specificity were 86.5% and 92.3%, respectively. For the 64 follicular neoplasms, sensitivity and specificity were 18.2% and 88.7%, respectively.

For nonfollicular malignant neoplasms, the positivity and the sensitivity of each US characteristic are shown in **Table 1**. According to Fisher exact 2-tailed test, all characteristics assumed to determine malignancy were statistically significant.

From the Noguchi Thyroid Clinic and Hospital Foundation, Oita, Japan.

## PATIENTS AND METHODS

### PATIENTS

This study included 309 consecutive patients with 329 thyroid nodules larger than 5 mm in diameter. All patients underwent US examination before thyroidectomy between January 1 and June 30, 1999, at Noguchi Thyroid Clinic and Hospital Foundation, Oita, Japan. The patients comprised 279 females and 30 males with a mean age ( $\pm$ SD) of  $52.8 \pm 13.8$  years (range, 15-82 years). Solitary nodules were found in 254 patients (82.2%), and multiple nodules were found in 55 (17.8%). For multiple nodular goiters, US characteristics were evaluated on the dominant nodule and/or suspected malignant nodule. Surgery was performed for a preoperative diagnosis of malignant nodule in 152 patients (49.2%), for follicular neoplasms in 52 (16.8%), and for cosmetic reasons and/or tracheal compression by nodular goiter in 77 (24.9%).

### ULTRASONOGRAPHY

The US examination was performed with a US scanner (Logiq TM500MD; GE Yokogawa Medical Systems, Tokyo, Japan) equipped with a 6- to 13-MHz linear probe (LA 39; GE Yokogawa Medical Systems). The spatial resolution for this system is about 2 mm. Margin (well defined or ill defined), shape (regular or irregular), halo sign (present or absent), echo structure (solid, mixed, or cystic), internal echo (homogeneous or heterogeneous), echogenicity (hyperechoic or isoechoic, hypoechoic, or hypoisoechoic), calcification (fine, other, or absent), and invasion to adjacent organs (present or absent) were assessed to make a US diagnosis of either malignant or benign disease. Preoperatively, we considered ill-defined or irregular nodules with heterogeneous internal echo or hypoechogenicity to be malignant. With signs

of invasion to adjacent organs, nodules were malignant regardless of the other characteristics. We also considered solitary and solid nodules with homogeneous internal echo to be follicular neoplasms.

### PATHOLOGICAL DIAGNOSIS

The final pathological diagnosis was determined by a single pathologist (Hiroto Yamashita). Pathologically, we found 145 papillary carcinomas, 11 follicular carcinomas, 2 medullary carcinomas, 1 mucoepidermoid carcinoma, 101 adenomatous goiters, 54 follicular adenomas, 14 cysts, and 1 calcified nodule. Nodules were divided into 2 groups on the basis of pathological diagnosis: follicular neoplasms (follicular adenoma and carcinoma) and nonfollicular neoplasms (papillary carcinoma, medullary carcinoma, mucoepidermoid carcinoma, adenomatous goiter, cyst, and calcified nodule).

### STATISTICAL ANALYSIS

The numbers of true-positive (TP), true-negative (TN), false-positive (FP), and false-negative (FN) US diagnoses were determined. Sensitivity was calculated as  $TP/(TP+FN)$ , and specificity was calculated as  $TN/(TN+FP)$ . Fisher exact 2-tailed test and multiple logistic regression analysis with a JMP program for Macintosh (SAS Institute Inc, Cary, NC) were used for statistical analyses.  $P < .05$  was considered statistically significant. The probability of malignancy was calculated by the following formula:

$$\text{Probability (Malignancy)} = \frac{1}{1 + \text{Exp}[-(a_0 + a_1X_1 + a_2X_2 + a_3X_3 + a_4X_4 + a_5X_5)]}$$

where exp represents exponent,  $a_0$  is the intercept estimate,  $a_{1-5}$  is the estimate of US characteristics, and  $X$  is the point of US characteristics.

**Table 1. Ultrasonographic Characteristics of Nonfollicular Malignant Nodules**

Feature	Characteristics	No./Total No. (%)	
		Positivity in Malignant Nodules	Sensitivity
Margin	Ill defined	83/148 (56.1)	83/93 (89.2)
Shape	Irregular	87/148 (58.8)	87/90 (96.7)
Echo structure	Solid	121/148 (81.8)	121/145 (83.4)
Internal echo	Heterogeneous	43/148 (29.1)	43/63 (68.3)
Echogenicity	Hypoechoic	76/148 (51.4)	76/80 (95.0)
Halo sign	Absent	119/148 (80.4)	119/177 (67.2)
Calcification	Fine	47/148 (31.8)	47/53 (88.7)
	Other	42/148 (28.4)	42/53 (79.2)
Invasion	Present	18/148 (12.2)	18/18 (100)

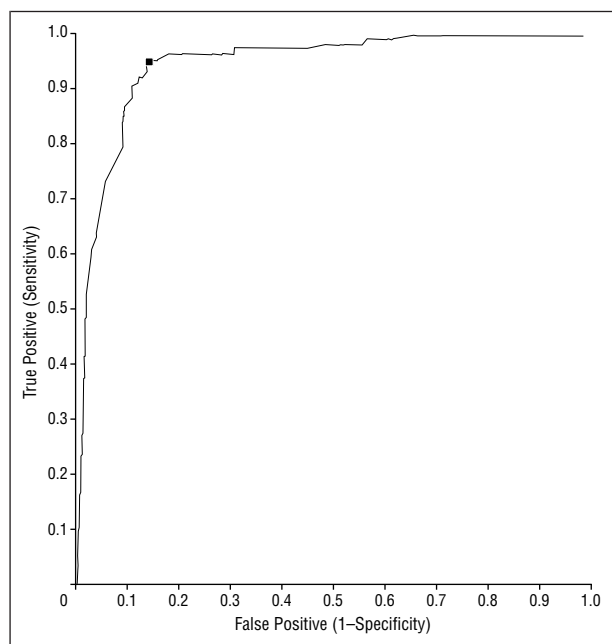
Considerations of internal echo, invasion, and halo sign were excluded from multiple logistic regression analysis for the following reasons. When nodules were studied for echogenicity, nodules showing a heterogeneous internal echo appeared hypoisoechoic; thus, a bias existed. Invasion showed a low positivity (18/148) with 100% sensitivity, and the  $P$  value for the halo sign was not significant ( $P = .60$ ). The remaining 5 characteristics were reanalyzed. The remaining characteristics as-

sumed to determine malignancy were statistically significant ( $P < .05$ ) and the estimate and point of each characteristic are shown in **Table 2**. We constructed receiver operating characteristic curves with the use of these data (**Figure 1**). According to the receiver operating characteristic curve, the best point at which to predict malignancy was when sensitivity was 94% and specificity was 87%. The probability of malignancy at this point was greater than 0.2. **Figure 2** shows the receiver operating

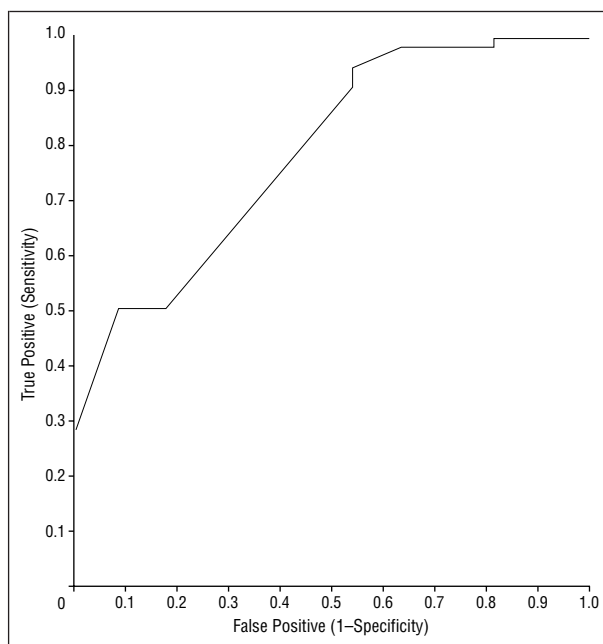
**Table 2. Estimate and Point Ultrasonographic Characteristics\***

Feature	Characteristics	Point	Estimate	P Value
Intercept	...	...	0.355	...
Margin	Well-defined	0	...	.049
	Ill-defined	1	1.034	
Shape	Regular	0	...	<.001
	Irregular	1	3.079	
Echo structure	Cystic	0	...	.01
	Solid	1	0.457	
	Mixed	2	-0.871	
Echogenicity	Isoechoic or hyperechoic	0	...	<.001
	Hypoechoic	1	1.717	
	Hypoisoechoic	2	0.491	
Calcification	Absent	0	...	<.001
	Fine	1	1.382	
	Other	2	0.452	

\*Ellipses indicate not applicable.



**Figure 1.** Receiver operating characteristic curve for nonfollicular neoplasms.



**Figure 2.** Receiver operating characteristic curve for follicular neoplasms.

characteristic curve for follicular neoplasms, which was created in the same manner.

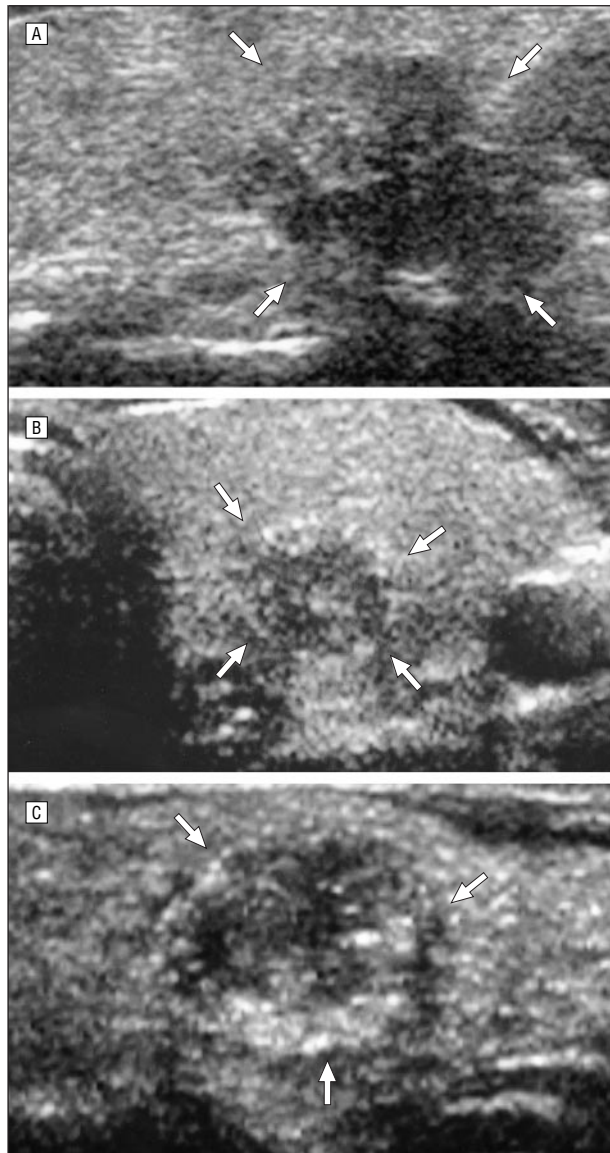
**COMMENT**

Thyroid nodules are very common, detected on palpation in 2.1% to 4.2% of the population in the United States,<sup>13,14</sup> in 5.1% to 6.5% in Europe,<sup>15,16</sup> and in 1.3% to 3.9% in Japan.<sup>17,18</sup> Thus, it is important to differentiate malignant nodules from benign nodules to avoid unnecessary thyroidectomy. Ultrasonography is the first choice for detecting thyroid abnormalities because of its safety, noninvasiveness, nonradioactivity, and effectiveness. Ultrasound can detect the presence, site, size, and number of thyroid nodules, and there have been reports of US characteristics of malignancy, such as ill-defined margin, irregular shape, hypoechogenicity, heterogeneity, absence of cystic lesion and/or the halo sign, the presence

of calcification, and invasion to adjacent organs.<sup>1-4,6-8,10</sup> However, the characteristics of thyroid nodules on US can vary widely by observer,<sup>19</sup> and a formula for predicting malignancy has not yet been reported. The US diagnosis of thyroid nodules is still controversial for these 2 reasons.

For this study, we chose nodules with a diameter greater than 5 mm, because high-resolution real-time US can detect characteristics of even small thyroid nodules in detail, and sometimes patients with minute cancers die of local and/or distant metastasis.<sup>20,21</sup> It is important not to overlook malignancy. We also separated thyroid nodules into 2 groups on the basis of pathological diagnosis. Because follicular neoplasms are difficult to diagnose as malignant or benign, they should be considered separately.

As far as we know, this is the first study to formulate statistical prediction of malignancy based on US char-



**Figure 3.** A, Irregular and ill-defined solid nodule with hypoechoogenicity (arrows). The probability ratio is 0.97. B, Regular and well-defined solid nodule with hypoechoogenicity (arrows). The probability ratio is 0.83. C, Regular and well-defined solid nodule with hypoechoogenicity and fine calcification (arrows). The probability ratio is 0.85.

acteristics of thyroid nodules in a large number of patients in a short time. The US features reported previously to predict malignancy (Table 1) were statistically significant on the basis of univariate analysis. According to multiple logistic regression analysis, 5 features (margin, shape, echo structure, echogenicity, and calcification) were statistically significant for predicting malignancy in non-follicular neoplasms. Using receiver operating characteristic curves based on the multiple logistic regression analysis, we identified the best point with high true-positive and low false-negative rate. The probability at this point was greater than 0.2. Some typical US characteristics are shown in **Figure 3**. For follicular neoplasms,

we could not differentiate carcinoma from adenoma by the same procedure.

In conclusion, we created a formula for predicting malignancy of thyroid nodules on the basis of multiple logistic regression analysis with the use of only 5 US features. It can be applied to nonfollicular thyroid neoplasms with high accuracy but not to follicular thyroid neoplasms.

*Corresponding author and reprints: Shiro Noguchi, MD, PhD, Noguchi Thyroid Clinic and Hospital Foundation, 6-33 Noguchi Naka-machi, Beppu, Oita, 874-0932, Japan.*

## REFERENCES

- Solbiati L, Volterrani L, Rizzato G, et al. The thyroid gland with low uptake lesions: evaluation by ultrasound. *Radiology*. 1985;155:187-191.
- Rojeski MT, Gharib H. Nodular thyroid disease: evaluation and management. *N Engl J Med*. 1985;313:428-436.
- Murakami T, Murakami N, Noguchi S, Noguchi A, Ohta N. Ultrasonographic diagnosis of solitary thyroid nodule. *Jpn J Med Ultrasonics*. 1987;14:126-133.
- Murakami T, Murakami N, Noguchi S, Noguchi A, Ohta N. Ultrasonographic diagnosis of nodular goiter. *Jpn J Med Ultrasonics*. 1988;15:264-272.
- Cox MR, Marshall SG, Spence RAJ. Solitary thyroid nodule: a prospective evaluation of nuclear scanning and ultrasonography. *Br J Surg*. 1991;78:90-93.
- Watters DA, Ahuja AT, Evans RM, et al. Role of ultrasound in the management of thyroid nodules. *Am J Surg*. 1992;164:654-657.
- Okamoto T, Yamashita T, Harasawa A, et al. Test performances of three diagnostic procedures in evaluating thyroid nodules: physical examination, ultrasonography and fine needle aspiration cytology. *Endocr J*. 1994;41:243-247.
- Brkijacic B, Cuk V, Tomic-Brzac H, Bence-Zigman Z, Delic-Brkijacic D, Drinkovic I. Ultrasonic evaluation of benign and malignant nodules in echographically multinodular thyroids. *J Clin Ultrasound*. 1994;22:71-76.
- Leenhardt L, Tramalloni J, Aurengo H, Delbot T, Guillausseau C, Aurengo A. Echography of thyroid nodules: the echography specialist facing the clinician's requirements. *Presse Med*. 1994;23:1389-1392.
- Takashima S, Fukuda H, Nomura N, Kishimoto H, Kim T, Kobayashi T. Thyroid nodules: re-evaluation with ultrasound. *J Clin Ultrasound*. 1995;23:179-184.
- Lin J, Huang B, Weng H, Jeng L, Hsueh C. Thyroid ultrasonography with fine-needle aspiration cytology for the diagnosis of thyroid cancer. *J Clin Ultrasound*. 1997;25:111-118.
- Hatada T, Okada K, Ishii H, Ichii S, Utsunomiya J. Evaluation of ultrasound-guided fine-needle aspiration biopsy for thyroid nodules. *Am J Surg*. 1998;175:133-136.
- Vander J, Gaston E, Dawber T. The significance of nontoxic thyroid nodules: final report of a 15-year study of the incidence of thyroid malignancy. *Ann Intern Med*. 1968;69:537-540.
- Rallison ML, Dobyns BM, Meikle AW, Bishop M, Lyon JL, Stevens W. Natural history of thyroid abnormalities: prevalence, incidence, and regression of thyroid diseases in adolescents and young adults [published correction appears in *Am J Med*. 1992;92:582]. *Am J Med*. 1991;91:363-370.
- Christensen S, Ericsson U, Janzon L, Tibblin S. The prevalence of thyroid disorders in a middle-aged female population, with special reference to the solitary thyroid nodule. *Acta Chir Scand*. 1984;150:13-19.
- Brander A, Viikinkoski P, Nickels J, Kivisaari L. Thyroid gland: US screening in a random adult population. *Radiology*. 1991;181:683-687.
- Ishida T, Izuo M, Ogawa T, Kurebayashi J, Satoh K. Evaluation of mass screening for thyroid cancer. *Jpn J Clin Oncol*. 1988;18:289-295.
- Miki H, Oshimo K, Inoue H, et al. Incidence of ultrasonographically-detected thyroid nodules in healthy adults. *Tokushima J Exp Med*. 1993;40:43-46.
- Jarlov AE, Nygard B, Hegedus L, Karstrup S, Hansen JM. Observer variation in ultrasound assessment of the thyroid gland. *Br J Radiol*. 1993;66:625-627.
- Kasai N. New approach to diagnosis of minute and small thyroid cancer. *Gan No Rinsho*. 1983;29:488-492.
- Noguchi S, Yamashita H, Murakami N, Nakayama I, Toda M, Kawamoto H. Small carcinomas of the thyroid: a long-term follow-up of 867 patients. *Arch Surg*. 1996;131:187-191.