

# Melanoma of the Clavicular Region

## Multimodal Treatment

Linh Lam, MD; Edward Krementz, MD; Clifton McGinness, MD; Richard Godfrey, MD

**Hypothesis:** Treatment for melanoma that has metastasized to the supraclavicular nodes should be intensive and use a multimodality approach.

**Design:** Retrospective analysis of clinical records.

**Setting:** Six primary care centers, 2 of which were referral centers.

**Patients:** Eighteen patients diagnosed as having a rare pattern of advanced melanoma metastatic to the clavicular region.

**Intervention:** Combined radiotherapy, chemotherapy, and thorough surgical excision of the affected nodal basins.

**Main Outcome Measure:** Length of survival from time of diagnosis and treatment to time of follow-up.

**Results:** Median survival among the 18 patients was 28 months with a 22% survival rate at 5 years after diagnosis. Among patients who received radiotherapy to the

clavicular node basin, mean length of survival was 88.7 months with a 50% 5-year survival rate compared with a mean length of survival of 33.8 months and an 8.3% 5-year survival rate in patients who did not receive radiotherapy ( $P < .001$ ). Mean survival among patients who had supraclavicular node dissection was 45.8 months with a 23.1% survival rate at 5 years after diagnosis, compared with a mean survival of 52 months and a 20% 5-year survival rate among patients who did not receive therapeutic lymphadenectomy. Of the 11 patients who had therapeutic lymphadenectomy, 2 also received radiotherapy to the supraclavicular nodal basin and continued to be disease-free at 82 and 130 months. All long-term survivors had been treated with intra-arterial chemotherapy.

**Conclusion:** In a series of patients with malignant melanoma metastatic to the clavicular lymph nodes, multimodality treatment using radiotherapy, chemotherapy, and thorough surgical excision of affected nodal basins provided an appreciable 5-year survival rate.

*Arch Surg.* 2001;136:1054-1058

**M**ALIGNANT melanoma represents 3% of all malignant neoplasms and 5% of all skin cancers. It accounts for nearly 75% of all deaths of skin cancer and is the second leading cause of death of cancer in US men aged 15 to 34 years. Moreover, its incidence is increasing at a rate of 3% to 5% annually, and an estimated 47 700 new cases were expected to be diagnosed in the year 2000.<sup>1-3</sup>

Malignant melanoma grows locally and metastasizes by lymphatic and hematogenous routes. Regional lymph node metastasis is the most common manifestation of recurrent melanoma.<sup>4,5</sup> When nodal involvement has occurred, prognosis is affected primarily by the number of positive lymph nodes involved, extent of lymph node involvement, recurrence in other re-

gional lymph nodes, and presence of extranodal disease.<sup>4,5</sup>

The medical literature contains extensive information and discussion of the clinical management of melanoma metastatic to cervical, axillary, and inguinal nodes.<sup>4,6,7</sup> Very little, however, has been written about the clinical course of the disease or about therapy in patients who are initially seen with metastases to the clavicular nodes. A search of the medical literature in English identified no articles describing this disease entity specifically.

We describe clinical treatment and treatment outcome in a series of patients with clavicular lymph node metastases, and review management of regionally advanced disease. We hypothesize that multimodal therapy can improve survival for some patients.

From the Departments of Surgery, Tulane University Medical Center (Dr Krementz) and Memorial Medical Center (Dr McGinness), New Orleans, La; and Kaiser Permanente Medical Center, Oakland, Calif (Drs Lam and Godfrey).

## METHODS

A retrospective analysis of clinical records was conducted for 325 patients diagnosed as having malignant melanoma treated at 6 medical centers (Tulane University Medical Center, New Orleans, La; Southern Baptist Hospital, New Orleans; Hotel Dieu, New Orleans; Touro Infirmary, New Orleans; Veterans Administration Hospital, New Orleans; and Kaiser Permanente Medical Center, Oakland, Calif) between 1959 and 1998. Of the 325 patients, 18 (5.5%), including 11 patients seen in New Orleans and 7 patients seen in Oakland, had melanoma that had metastasized to the clavicular region; of these 18 patients, 17 had metastases to the axillary nodes and subsequently received axillary lymphadenectomy before affected nodes that were clinically palpable developed in the clavicular region. Only 1 patient was noted to have affected nodes at initial axillary node dissection. Clavicular node dissection was done in 13 patients, 6 patients received radiation therapy, and 18 patients received chemotherapy. The mean follow-up interval was 28 months (range, 3-118 months) from the date clavicular node metastasis was diagnosed to the date of last follow-up or death. Cumulative survival rates were calculated from this interval.

## RESULTS

Of the 18 patients with clavicular node metastases, 6 (33%) were women and 12 (67%) were men. Ages ranged from 27 to 69 years (median, 43.5 years) (**Table**). Three patients (17%) survived after clavicular node metastases, 1 (5%) was unavailable at follow-up, and 14 (78%) died of cancer. Median length of survival for the entire 18 patients was 28 months with a 22% 5-year survival rate calculated from the date clavicular node metastases was diagnosed (**Figure 1**).

## CLINICAL MANAGEMENT

Radiotherapy to the clavicular node basin was administered to 6 patients, 3 of whom were still alive at the time of analysis, 1 of whom survived for 9 years and 10 months, and another who was alive at the 11-year follow-up despite being seen initially with stage IV disease (classification according to the American Joint Committee on Cancer manual). Median length of survival in this subset of patients was 88.7 months with a 50% 5-year survival rate, whereas patients without radiation treatment survived for a median of 33.8 months and had an 8.3% 5-year survival rate ( $P=.009$ ).

Thirteen of the 18 patients had supraclavicular node dissection. Their mean length of survival was 45.8 months with a 23.1% 5-year survival rate, whereas patients who did not receive therapeutic lymphadenectomy survived for a mean of 52 months and had a 20% 5-year survival rate. Two of the 11 patients with supraclavicular node dissection also received radiotherapy to

**Age and Disease Stage at Diagnosis for 12 Male and 6 Female Adult Patients With Supraclavicular Malignant Melanoma\***

Patient	Age at Diagnosis, y	Sex	Disease Stage at Diagnosis†
1	44	M	III
2	45	F	I
3	54	M	II
4	43	F	I
5	28	M	IV
6	41	M	I
7	53	M	III
8	55	M	I
9	35	F	IV
10	35	M	I
11	27	M	II
12	46	F	I
13	52	F	III
14	39	M	I
15	35	M	III
16	28	M	II
17	37	F	...
18	33	M	IV

\*M indicates male; F, female; and ellipses, unknown.

†Classification according to the American Joint Committee on Cancer manual.

the supraclavicular nodal basin, and both were disease-free at follow-up.

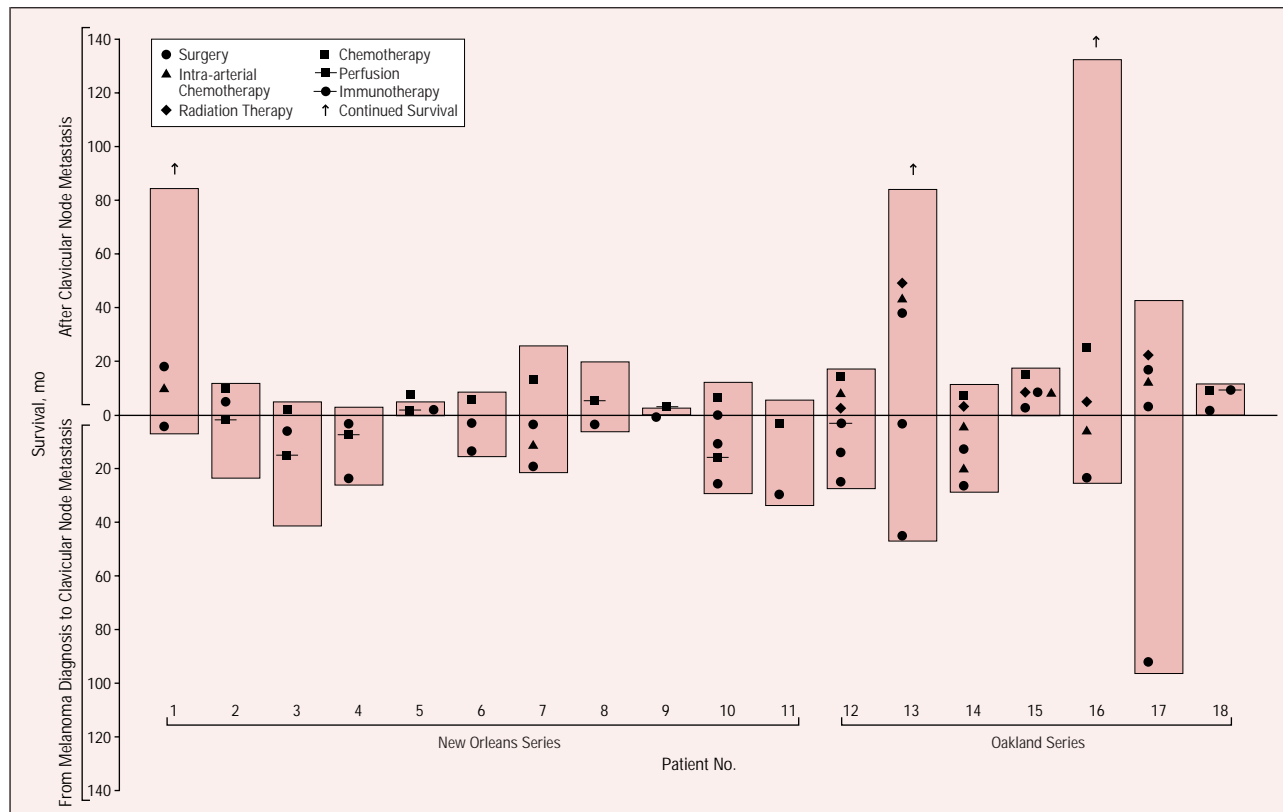
All 18 patients were treated with chemotherapy: 12 patients were treated with systemic chemotherapy, 7 patients received perfusion chemotherapy, and 8 patients received intra-arterial chemotherapy. Combinations of chemotherapy were administered at different times in most patients' courses of treatment. All long-term survivors had been treated with intra-arterial chemotherapy.

## SITE OF PRIMARY LESION

Eleven patients (61%) were seen initially with clinical stage I disease. Of these patients, 4 (36%) had a primary lesion in an extremity and 7 had a primary lesion in the head, neck, or trunk (Figures 2 and 3). Median length of survival for patients with melanoma of the head, neck, or trunk was 58.7 months with a 0% 5-year survival rate. Median length of survival for patients with a primary lesion in an extremity was 10.5 months with a 25% 5-year survival rate.

## COMMENT

Adverse clinical outcomes among patients with stage III disease can differ markedly: 5-year survival rates range from 10% for patients with more than 4 positive nodes to 58% for patients with a single positive node.<sup>6</sup> Patients with clinically negative but histologically positive nodes have better prognoses, while risk of mortality is greater in patients with a greater number of positive nodes, a higher percentage of positive lymph nodes, greater extent of lymph node replacement, extranodal extension into soft tissue, presence of disease in the highest node of a lymphatic chain, and increasing number of lymph



**Figure 1.** Length of survival among 11 patients at Tulane University Medical Center and Charity Hospital (New Orleans, La) and among 7 patients at Kaiser Permanente Medical Center (Oakland, Calif) diagnosed as having metastatic supraclavicular melanoma.

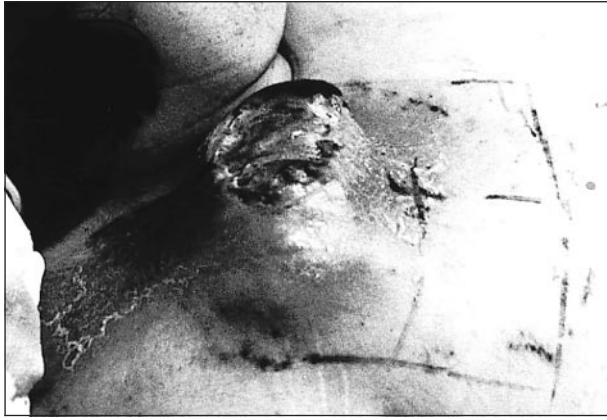phatic basins affected.<sup>4</sup> Nodal involvement is often more extensive in patients with melanoma of the head, neck, and trunk than in patients with melanoma of the extremities, although one study of a series of patients at the M. D. Anderson Cancer Center of the University of Texas<sup>7</sup> showed no statistically significant difference in survival rates for patients with cervical nodal metastases compared with patients who had inguinal or axillary lymph node metastases.

In 1983, the American Joint Committee on Cancer placed patients with more than 1 affected regional lymph node basin into the stage IV category.<sup>8</sup> This classification remains unchanged in the currently proposed classification revisions.<sup>9</sup> Stage IV disease has a poor prognosis: 5-year survival rates range from 6% to 10% in undifferentiated patient groups<sup>10</sup> to 26% in patients who received metastatectomy and vaccine treatment.<sup>11</sup> Coit<sup>4</sup> reported only a 9% 5-year survival rate for patients with 2 nodal basins affected with melanoma, whereas Barth and associates<sup>12</sup> noted a 27% 5-year survival rate in a series of 21 patients. The 22% 5-year survival rate noted in our group is favorable, but the groups may not be comparable. Some of our patients were initially seen with metachronous disease, and the 5-year survival rate in our study was calculated from time of onset of supraclavicular disease.

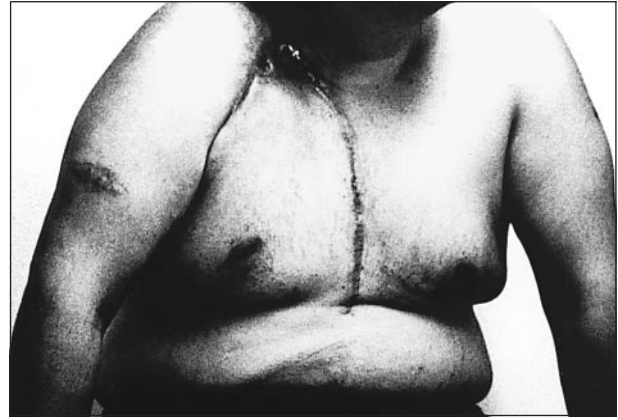Most patients with locoregional metastases of melanoma have been treated with surgery, chemotherapy, radiation, or immunotherapy, and determining the statistically most effective of these methods is beyond the scope of this retrospective review. However, our study shows some important trends that are in accord with the estab-

lished medical literature. In particular, all 18 patients were treated with some form of chemotherapy: 12 patients were treated with systemic chemotherapy, 7 patients received perfusion, and 8 patients received intra-arterial chemotherapy. Nine perfusions and 1 intra-arterial infusion were done at Tulane University Medical Center and Memorial Medical Center using techniques described by Kremenz et al during the period of 1959 to 1998.<sup>13</sup> Six arterial infusions were administered at Kaiser Permanente Medical Center infusing carboplatin and actinomycin D through catheters placed by interventional radiology.<sup>14,15</sup> The technique included the use of a balloon catheter to interrupt arterial flow for 5 minutes so that regional drug concentration could be increased. This technique, different from the tourniquet method described by other institutions,<sup>16,17</sup> resulted in no complications. Intra-arterial treatment was given on an outpatient basis in 5 patients and on an inpatient basis in 1 patient. Combinations of chemotherapy were administered at different times during the treatment phase: 4 patients had intra-arterial and systemic chemotherapy and 5 patients had perfusion and systemic chemotherapy. Each of the long-term survivors was treated with intra-arterial chemotherapy. One of the 3 long-term survivors later required systemic chemotherapy for pulmonary metastases. He did not have recurrence when seen at 11-year follow-up. Two patients underwent biochemotherapy, receiving a combination of interleukin, interferon, and chemotherapy. Both patients had a minimal response.

The role of radiotherapy in treating melanoma has been disputed. Some authors have advocated its use in



**Figure 2.** Preoperative photograph shows a patient with periclavicular metastasis.



**Figure 3.** Postoperative photograph of same patient shows myocutaneous flap created after radiation necrosis was seen in clavicular region.

the treatment of primary disease such as lentigo maligna melanoma<sup>18</sup> and for adjuvant control after lymphadenectomy,<sup>19</sup> when the tumor is no longer considered “radio-resistant.” Prospective randomized protocols have confirmed the usefulness of radiation therapy for improving the rates of disease-free survival in patients with melanoma of the head or neck as well as in patients with upper-extremity melanoma.<sup>19-21</sup> The positive effect of radiation therapy has been shown in the palliative management of inoperable and bulky metastatic melanoma.<sup>1,22</sup> Our data support the positive role of radiation therapy when used after surgical excision of involved supraclavicular nodes. Adverse effects of radiation, however, can also be significant. One patient who received 6000 rads to the clavicular region (**Figure 2**) had paresis of the right arm and radiation necrosis, which required a myocutaneous flap to cover the damaged area (**Figure 3**).

The importance of therapeutic lymph node dissection in local or regional control of metastatic melanoma has been clearly established. Warso et al<sup>23</sup> reported a recurrence rate as low as 0.8% in patients with previously dissected nodal basins and also stated that long-term survival is seen in about 15% of patients with such local relapses. In another series, mean 5-year survival dropped to 12%<sup>6</sup> from a rate of 26% in patients who had recurrent nodal metastases after initial regional lymphadenectomy.<sup>5</sup> Our 18.7% mean 5-year survival rate in the patients undergoing surgery is similar to these other studies.<sup>5,7,23</sup> Two of our patients who had early mortality had synchronous distal metastases at the onset of clavicular nodal recurrences. With the advent of positron emission tomography scan for identifying stage IV disease, selection of surgical candidates should become more accurate.<sup>24,25</sup>

Nodal basin melanoma deeper than 1 mm is initially assessed by sentinel lymph node biopsy.<sup>26-28</sup> Currently, complete node dissection is recommended for almost all patients with immunohistochemically positive sentinel nodes. Until researchers in the Sunbelt Melanoma Trial complete their investigation of clinical outcomes in patients with only immunohistochemically positive nodes, the essential role of surgery for stage III disease is unlikely to change. Given the likelihood of earlier diagnosis by sentinel lymph node biopsy and given the improved management of intermediate- and deep-level melanoma affecting the lymph node

basin, fewer patients will have metastases to the clavicular region. Since 1994, when sentinel lymph node biopsy was introduced at Kaiser Permanente Medical Center, no patients who underwent the sentinel node procedure at that facility have had clavicular metastases. Patients at risk are those who have undergone wide excision only, who have had recurrences after inaccurate lymph node dissection, or who are initially seen with unidentified primary lesions. Melanoma centers to which such patients are referred for consultation may continue to be challenged by the problem of clavicular disease.

Lymph node metastasis is the most common manifestation of recurrent melanoma. Although management of melanoma affecting the cervical, axillary, and inguinal nodal regions has been widely documented, no published reports have described the clinical course and management of metastases to the supraclavicular nodes. This pattern of metastasis represents a more advanced stage of melanoma, and given its poor prognosis, we advocate an intensive, multimodal approach for treating metastases to the clavicular area. Our retrospective analysis showed that combined use of radiotherapy, chemotherapy, and thorough surgical excision of affected nodal basins can provide an appreciable 5-year survival rate. Additional reports of this rare pattern of metastatic melanoma may provide a better understanding of the clinical entity.

*The Medical Editing Department at the Kaiser Foundation Research Institute provided editorial assistance.*

*Corresponding author and reprints: Richard Godfrey, MD, Department of Surgery, Kaiser Permanente Medical Center, 280 W MacArthur Blvd, Oakland, CA 94611-5693.*

## REFERENCES

1. Greenlee RT, Murray T, Bolden S, Wingo PA. Cancer statistics, 2000. *CA Cancer J Clin.* 2000;50:7-33.
2. Parker SL, Tong T, Bolden S, Wingo PA. Cancer statistics, 1996. *CA Cancer J Clin.* 1996;46:5-27.
3. Lenhard RE Jr. Cancer statistics: a measure of progress. *CA Cancer J Clin* 1996; 46:3-4.
4. Coit DG. Prognostic factors in patients with melanoma metastatic to regional nodes. *Surg Oncol Clin N Am.* 1992;1:281-295.
5. Karakousis CP. Therapeutic node dissections in malignant melanoma. *Ann Surg Oncol.* 1998;5:473-482.
6. Balch CM, Soong SJ, Murad TM, Ingalls AL, Maddox WA. A multifactorial analy-

- sis of melanoma, III: prognostic factors in melanoma patients with lymph node metastases (stage II). *Ann Surg.* 1981;193:377-388.
7. Singletary SE, Shallenberger R, Guinee VF, McBride CM. Melanoma with metastasis to regional axillary or inguinal lymph nodes: prognostic factors and results of surgical treatment in 714 patients. *South Med J.* 1998;81:5-9.
  8. Beahrs OH, Myers MH, eds. *Manual for Staging of Cancer.* 2nd ed. Philadelphia, Pa: Lippincott; 1983:117.
  9. Balch CM, Buzaid AC, Atkins MB, et al. A new American Joint Committee on Cancer staging system for cutaneous melanoma. *Cancer.* 2000;88:1484-1491.
  10. Meyers ML, Balch CM. Diagnosis and treatment of metastatic melanoma. In: Balch CM, Houghton AN, Sober AJ, Soong S-J, eds. *Cutaneous Melanoma.* 3rd ed. St Louis, Mo: Quality Medical Publishing; 1998:325-372.
  11. Morton DL, Foshag LJ, Hoon DS, et al. Prolongation of survival in metastatic melanoma after active specific immunotherapy with a new polyvalent melanoma vaccine [published erratum appears in *Ann Surg.* 1993;217:309]. *Ann Surg.* 1992;216:463-482.
  12. Barth RJ Jr, Venzon DJ, Baker AR. The prognosis of melanoma patients with metastases to two or more lymph node areas. *Ann Surg.* 1991;214:125-130.
  13. Kremenz ET, Ryan RF, Muchmore JH, Carter RD, Sutherland CM, Reed RJ. Hyperthermic regional perfusion for melanoma of the limbs. In: Balch CM, Houghton AN, Milton GW, Soong S-J, Sober AJ, eds. *Cutaneous Melanoma.* 2nd ed. Philadelphia, Pa: Lippincott; 1992:403-426.
  14. Godfrey R, Saha S, Kremenz E. Chemotherapy by tourniquet infusion and with water bath hyperthermia for treatment of limb melanomas. In: American Society of Clinical Oncology. *Twenty-fourth Annual Meeting of the American Society of Clinical Oncology, May 22-24, 1988, New Orleans, Louisiana, Proceedings.* Vol. 7. Alexandria, Va: ASCO; 1988:253.
  15. Godfrey RS, Saha S, Kremenz ET. Clinical experience with intra-arterial chemotherapy and hyperthermia [abstract]. In: *Proceedings of the 37th Annual Meeting of the Radiation Research Society and the 9th Annual Meeting of the North American Hyperthermia Group; March 18-23, 1989; Seattle, Wash.* Oakbrook, Ill: Radiation Research Society; 1989.
  16. Thompson JF, Kam PC, Waugh RC, Harmon CR. Isolated limb perfusion with cytotoxic agents: a simple alternative to isolated limb perfusion. *Semin Surg Oncol.* 1998;14:238-247.
  17. Karakousis CP, Kanter PM, Park HC, Sharma SD, Moore R, Ewing JH. Tourniquet infusion versus hyperthermic perfusion. *Cancer.* 1982;49:850-858.
  18. Geara FB, Ang KK. Radiation therapy for malignant melanoma. *Surg Clin N Am.* 1996;76:1383-1398.
  19. Strom EA, Ross MI. Adjuvant radiation therapy after axillary lymphadenectomy for metastatic melanoma: toxicity and local control. *Ann Surg Oncol.* 1995;2:445-449.
  20. Ang KK, Byers RM, Peters LJ, et al. Regional radiotherapy as adjuvant treatment for head and neck malignant melanoma: preliminary results. *Arch Otolaryngol Head Neck Surg.* 1990;116:169-172.
  21. Creagan ET, Cupps RE, Ivins JC, et al. Adjuvant radiation therapy for regional nodal metastases from malignant melanoma: a randomized, prospective study. *Cancer.* 1978;42:2206-2210.
  22. Burmeister BH, Smithers BM, Poulsen M, et al. Radiation therapy for nodal disease in malignant melanoma. *World J Surg.* 1995;19:369-371.
  23. Warso MA, Das Gupta TK. Melanoma recurrence in a previously dissected lymph node basin. *Arch Surg.* 1994;129:252-255.
  24. Holder WD Jr, White RL Jr, Zuger JH, Easton EJ Jr, Greene FL. Effectiveness of positron emission tomography for the detection of melanoma metastases. *Ann Surg.* 1998;227:764-769. Discussion pp 769-771.
  25. Rinne D, Baum RP, Hor G, Kaufmann R. Primary staging and follow-up of high risk melanoma patients with whole-body 18F-fluorodeoxyglucose positron emission tomography: results of a prospective study of 100 patients. *Cancer.* 1998; 82:1664-1671.
  26. Morton DL, Wen DR, Wong JH, et al. Technical details of intraoperative lymphatic mapping for early stage melanoma. *Arch Surg.* 1992;127:392-399.
  27. Reintgen D, Balch CM, Kirkwood J, Ross M. Recent advances in the care of the patient with malignant melanoma. *Ann Surg.* 1997;225:1-14.
  28. Ross MI, Gershenwald JE. Melanoma lymphatic mapping: scientific support for the sentinel lymph node concept and biological significance of the sentinel node. In: Whitman ED, Reintgen D, eds. *Radioguided Surgery.* Austin, Tex: Landes Bioscience; 1999:47-62.

## IN OTHER AMA JOURNALS

### JAMA

#### Cost-effectiveness of Screening for Colorectal Cancer in the General Population

A. Lindsay Frazier, MD, MSc; Graham A. Colditz, MD, DrPH; Charles S. Fuchs, MD, MPH; Karen M. Kuntz, ScD

**Context:** A recent expert panel recommended that persons at average risk of colorectal cancer (CRC) begin screening for CRC at age 50 years using 1 of several strategies. However, many aspects of different CRC screening strategies remain uncertain.

**Objective:** To assess the consequences, costs, and cost-effectiveness of CRC screening in average-risk individuals.

**Design:** Cost-effectiveness analysis from a societal perspective using a Markov model.

**Subjects:** Hypothetical subjects representative of the 50-year-old US population at average risk for CRC.

**Setting:** Simulated clinical practice in the United States.

**Main Outcome Measures:** Discounted lifetime costs, life expectancy, and incremental cost-effectiveness (CE) ratio, compared used 22 different CRC screening strategies, including those recommended by the expert panel.

**Results:** In 1 base-case analysis, compliance was assumed to be 60% with the initial screen and 80% with follow-up or surveillance colonoscopy. The most effective strategy for white men was annual rehydrated fecal occult blood testing (FOBT) plus sigmoidoscopy (followed by colonoscopy if either a low- or high-risk polyp was found) every 5 years from age 50 to 85 years, which resulted in a 60% reduction in cancer incidence and an 80% reduction in CRC mortality compared with no screening, and an incremental CE ratio of \$92900 per year of life gained compared with annual unrehydrated FOBT plus sigmoidoscopy every 5 years. In a base-case analysis in which compliance with screening and follow-up is assumed to be 100%, screening more often than every 10 years was prohibitively expensive; annual rehydrated FOBT plus sigmoidoscopy every 5 years had an incremental CE ratio of \$489900 per life-year gained compared with the same strategy every 10 years. Other strategies recommended by the expert panel were either less effective or cost more per year of life gained than the alternatives. Colonoscopy every 10 years was less effective than the combination of annual FOBT plus sigmoidoscopy every 5 years. However, a single colonoscopy at age 55 years achieves nearly half of the reduction in CRC mortality obtainable with colonoscopy every 10 years. Because of increased life expectancy among white women and increased cancer mortality among blacks, CRC screening was even more cost-effective in these groups than in white men.

**Conclusions:** Screening for CRC, even in the setting of imperfect compliance, significantly reduces CRC mortality at costs comparable to other cancer screening procedures. However, compliance rates significantly affect the incremental CE ratios. In this model of CRC, 60% compliance with an every 5-year schedule of screening was roughly equivalent to 100% compliance with an every 10-year schedule. Mathematical modeling used to inform clinical guidelines needs to take into account expected compliance rates. (2000;284:1954-1961) www.jama.com

*Corresponding author and reprints:* A. Lindsay Frazier, MD, MSc, Channing Laboratory, 181 Longwood Ave, Boston, MA 02115 (e-mail: lindsay.frazier@channing.harvard.edu).