

# Experiences in Thoracoscopic Sympathectomy for Axillary Hyperhidrosis and Osmidrosis

## Focusing on the Extent of Sympathectomy

Chung-Ping Hsu, MD; Sen-Ei Shia, MD; Jiun-Yi Hsia, MD; Cheng-Yen Chuang, MD; Chih-Yi Chen, MD

**Hypothesis:** A more selective sympathectomy can improve the outcome of axillary hyperhidrosis and osmidrosis and minimize the potential sequelae.

**Design:** Retrospective cohort.

**Setting:** Tertiary care center.

**Patients:** Between July 1, 1996, and May 30, 2000, 171 patients with axillary hyperhidrosis and osmidrosis were studied.

**Interventions:** T3-4 sympathectomies were performed in 40 patients (group 1), T4 sympathectomies were performed in 56 patients (group 2), and T4-5 sympathectomies were performed in 75 patients (group 3).

**Main Outcome Measures:** The surgical outcomes were evaluated by direct patient interview in the outpatient clinic or by telephone or mail questionnaires. The results were categorized as excellent (significant or com-

plete disappearance of symptoms), good ( $\geq 50\%$  improvement), or poor ( $< 50\%$  improvement).

**Results:** There were no surgical mortalities in this study. Twenty-eight group 1 patients (70%), 16 group 2 patients (29%), and 22 group 3 patients (29%) developed compensatory perspiration ( $P < .001$ ). Six group 1 patients (15%), 1 group 2 patient (2%), and 1 group 3 patient (1%) developed dry hands ( $P = .02$ ). In the group 1 patients, the surgical outcomes were excellent in 21 (52%), good in 6 (15%), and poor in 13 (32%). In the group 2 patients, the surgical outcomes were excellent in 29 (52%), good in 10 (18%), and poor in 17 (30%). In the group 3 patients, the surgical outcomes were excellent in 53 (71%), good in 11 (15%), and poor in 11 (15%) ( $P = .04$ ). (Percentages may not sum to 100 because of rounding.)

**Conclusion:** T4-5 sympathectomies provide higher patient satisfaction rates in treating axillary hyperhidrosis and osmidrosis, with fewer sequelae.

*Arch Surg.* 2001;136:1115-1117

From the Divisions of Surgical Emergency (Dr Hsu) and Thoracic Surgery (Drs Hsu, Shia, Hsia, Chuang, and Chen), Taichung Veterans General Hospital, Taichung, and Department of Surgery, School of Medicine, National Yang-Ming University, Taipei (Dr Hsu), Taiwan.

**T**HE ROLE OF thoracoscopic sympathectomy in treating palmar hyperhidrosis has been accepted worldwide since the introduction of video-assisted thoracic surgery in the early 1990s. More than 1400 thoracoscopic sympathectomies have been performed in our hospital since 1991. Axillary hyperhidrosis and osmidrosis cause considerable social and emotional handicaps. Since 1995, we have expanded our indications for performing thoracoscopic sympathectomy to treat this disorder. Large-scale treatment of axillary osmidrosis by sympathectomy is rare, and the proper extent of surgery is not well established. Different treatment approaches, including local application of deodorant,<sup>1</sup> excision or suction of apocrine glands,<sup>2-4</sup> and, more recently, local injection of botulinum toxin A,<sup>5-7</sup> have been

used. From our experience in performing thoracoscopic sympathectomies, we applied this technique to patients with axillary hyperhidrosis and osmidrosis and worked to establish the proper extent of sympathectomy for this disorder.

## RESULTS

There were no surgical mortalities in this series. Compensatory perspiration developed in 28 group 1 patients (70%), 16 group 2 patients (29%), and 22 group 3 patients (29%) ( $P < .001$ ). Dry hands developed in 8 patients (6 in group 1, 1 in group 2, and 1 in group 3) ( $P = .02$ ). In the group 1 patients, the surgical outcomes were excellent in 21 (52%), good in 6 (15%), and poor in 13 (32%). In the group 2 patients, the surgical outcomes were excellent in 29 (52%), good in 10 (18%), and poor in 17 (30%). In the group 3

## PATIENTS AND METHODS

### GENERAL DATA

Between July 1, 1996, and May 30, 2000, we performed sympathectomies for axillary hyperhidrosis and osmidrosis in 200 consecutive patients. Twenty-nine patients with concomitant palmar hyperhidrosis were excluded from the study. One hundred seventy-one patients who underwent bilateral thoracoscopic sympathectomies for axillary hyperhidrosis and osmidrosis were studied. T3-4 sympathectomies were performed in 40 patients (group 1), T4 sympathectomies were performed in 56 patients (group 2), and T4-5 sympathectomies were performed in 75 patients (group 3). The patient demographics are listed in the **Table**.

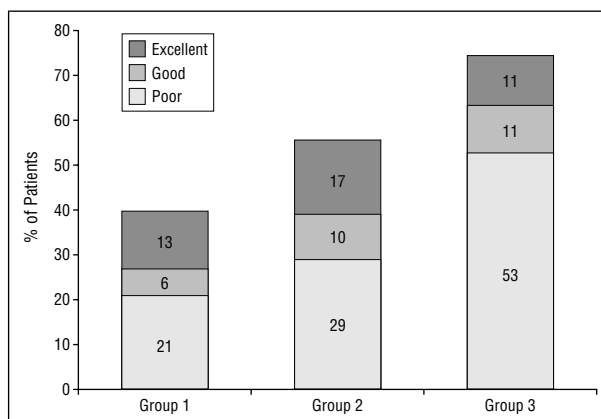
The surgical outcomes were evaluated by direct patient interview in the outpatient clinic or by questionnaires by telephone or mail. A checklist that included the degree of improvement, complications, and distribution of compensatory perspiration was used for data collection. All patients had been followed up for at least 3 months (range, 3-49 months; mean, 22.5 months). The outcomes were categorized as excellent (significant or complete disappearance of symptoms), good ( $\geq 50\%$  improvement), or poor ( $< 50\%$  improvement). Statistical analyses were performed using Pearson  $\chi^2$  test or Fisher exact test (2-tailed), and differences were considered significant at  $P < .05$ .

### SURGICAL PROCEDURES

The patient setup and surgical procedures have been previously reported.<sup>8</sup> Briefly, the patient was placed in a 45° semiseated position with 90° abduction of both upper extremities, under general anesthesia with a single-lumen endotracheal tube. An Oxypulse meter (Datex-Engstrom, Helsinki, Finland) was used in patients for monitoring oxygen saturation during the procedure. After disconnecting the endotracheal tube from the ventilation tube, suction was applied to facilitate pulmonary collapse. The pleural cavity was entered at the third intercostal space just posterior to the border of the greater pectoral muscle using a 10-mm thoracoscope (Stryker Endoscopy, Santa Clara, Calif) with a 5-mm working channel. The second rib may be localized by identifying the first internal intercostal muscle, terminating at the upper border of the second rib.<sup>9</sup> The sympathetic trunk was found, and sympathectomies were performed with endoscopic cautery. Bilateral T3-4 sympathectomies were done in 40 patients, T4 sympathectomies in 56 patients, and T4-5 sympathectomies in 75 patients. Sympathectomies on each side can usually be accomplished in 3 to 5 minutes. During the apneic period, the anesthesiologist performed pulmonary inflation once the patient's arterial oxygen saturation decreased to 90%. Intrapleural air was evacuated after completion of the bilateral procedures by pulmonary inflation, facilitated by suction applied to the pleural cavity. It is not necessary to insert a retained thoracic catheter, unless significant lung injury develops during the procedure. Patients were discharged from the recovery room after a 2-hour observation and followed up at the outpatient clinic 1 week later for a wound check and outcome evaluation.

### Demographic Data of the 171 Patients With Axillary Hyperhidrosis and Osmidrosis

Variable	Group 1 (n = 40)	Group 2 (n = 56)	Group 3 (n = 75)
Male/female, No.	12/28	13/43	12/63
Age range, (mean)	10-53 (24.5)	12-63 (25.5)	8-57 (23.2)
Sympathectomies	T3-4	T4	T4-5
Compensatory perspiration, No. (%)	28 (70.0)	16 (28.6)	22 (29.3)
Dry hands, No. (%)	6 (15.0)	1 (1.8)	1 (1.3)



Surgical results according to the extent of thoracoscopic sympathectomy. The overall good to excellent patient satisfaction rates in groups 1 through 3 were 67.5%, 69.6%, and 85.3%, respectively (overall,  $P = .04$ ; group 1 vs group 2,  $P = .83$ ; group 1 vs group 3,  $P = .03$ ; and group 2 vs group 3,  $P = .03$ ).

patients, the surgical outcomes were excellent in 53 (71%), good in 11 (15%), and poor in 11 (15%) ( $P = .04$ ). (Percentages may not sum to 100 because of rounding.) The surgical results are summarized in the **Figure**.

### COMMENT

Axillary hyperhidrosis, especially when it is associated with osmidrosis, is a disorder that significantly interferes with a person's social activities. Reports<sup>10-14</sup> describing treatment of this problem have focused on the treatment of palmar hyperhidrosis, with minimal discussion of axillary hyperhidrosis and osmidrosis. The proper extent of sympathectomy in the treatment of this condition is not yet well established.

Most previous reports<sup>10-14</sup> have recommended a T3-4 sympathectomy for this disorder, with satisfactory results in 68% to 89% of patients. The importance of T4 sympathectomy in treating axillary hyperhidrosis was emphasized by Masters and Rennie.<sup>15</sup> They obtained a 77% success rate with T2-4 sympathectomies. However, they also indicated that a T5 sympathectomy may be necessary for improved patient satisfaction.<sup>15</sup> Our data showed similar outcomes in group 1 and group 2 patients, but the proportion of good to excellent results increased to 85% when T4-5 sympathectomies were performed in our later experience. Although the results in treating axillary hyperhidrosis and osmidrosis did not reach the 97.5% satisfaction rate that was achieved in treating palmar hyperhidrosis,<sup>8</sup> our

data support incorporation of the T5 ganglion in treating axillary hyperhidrosis and osmidrosis, with preservation of the T3 ganglion. However, this was a retrospective cohort study, and comparison of the surgical outcomes of the procedures is limited by the different periods involved and by personal preference bias. A randomized study may be necessary to strengthen our recommendations.

Compensatory perspiration is a significant sequela, which developed in 95% of patients after T2 sympathectomy for palmar hyperhidrosis.<sup>8</sup> However, this condition was not as severe after sympathectomy for axillary hyperhidrosis and osmidrosis. As shown in the Table, compensatory perspiration developed in 28 (70%) patients after T3-4 sympathectomies and in 22 (29%) patients receiving T4-5 sympathectomies. This indicates that T2 and T3 ganglia affect upper limb perspiration more significantly than do T4 and T5 ganglia. Consequently, to minimize compensatory perspiration, T4-5 sympathectomy is the procedure of choice in treating axillary hyperhidrosis and osmidrosis. On rare occasions, compensatory perspiration becomes intolerable to the patient. This developed in fewer than 2% of patients receiving T2 sympathectomy for palmar hyperhidrosis<sup>8</sup> and was not observed in this study. However, patients should be warned of this possible complication before surgery because of the irreversibility of this sequela.

Dry hands among the patients who underwent T3-4 sympathectomies was another bothersome sequela in earlier experiences. However, by lessening the extent of sympathectomy by one level, the incidence of dry hands becomes negligible, without compromising the final outcome. Transient facial anhidrosis, which may be caused by upward thermal conduction during transection of the sympathetic trunk by diathermy, is another sequela; it occurred in 6.9% of the patients undergoing T2 sympathectomy for palmar hyperhidrosis.<sup>8</sup> In this study, only 2 group 1 patients and no group 2 or group 3 patients developed transient facial anhidrosis. This can be attributed to avoidance of thermal injury by a quick and sharp sympathetic transection, without further contact with the proximal cut end.

Recently, local injection of botulinum toxin A has demonstrated a promising effect in treating palmar and axillary hyperhidrosis.<sup>5-7</sup> However, the results are inconsistent, and successive local injections may be necessary to obtain a long-term effect. A total dosage of 200 U of botulinum toxin A per axilla has been recommended to avoid symptomatic relapse.<sup>16,17</sup> The definitive role of this treatment needs further investigation and may be a treatment option before sympathectomy.

Failed or recurrent cases of axillary hyperhidrosis and osmidrosis are mostly due to inadequate sympathectomy in the primary surgery, as previously reported.<sup>18</sup> Performing a second sympathectomy by extending the area of ganglion ablation achieved an 80% success rate.<sup>18</sup> The major sequela for the secondary procedure is a more significant compensatory perspiration induced by extensive sympathectomy, and patients should be informed of this before a subsequent sympathectomy.

From this study, we may conclude that T3 to T5 sympathetic ganglia all contribute to axillary perspiration. Ablation of all or part of these ganglia leads to a reduction in axillary sweating. Based on results of the extent of thoracoscopic sympathectomy in the treatment of axillary hyperhidrosis and osmidrosis, we suggest that the T3 sympathetic ganglion plays a lesser role in axillary hyperhidrosis, while the T4 sympathetic ganglion is the most important contributing factor. With a more selective sympathectomy by preservation of the T3 ganglion and ablation of the T5 ganglion, sequelae such as facial anhidrosis, dry hands, and compensatory perspiration may be decreased, contributing to overall patient satisfaction.

*Corresponding author and reprints: Chung-Ping Hsu, MD, Division of Surgical Emergency, Taichung Veterans General Hospital, Building 160, Section 3, Taichung-Kang Road, Taichung, Taiwan. (e-mail: cliff@vghc.vghc.gov.tw).*

## REFERENCES

1. Glent-Madsen L, Dahl JC. Axillary hyperhidrosis: local treatment with aluminum-chloride hexahydrate 25% in absolute ethanol with and without supplementary treatment with triethanolamine. *Acta Derm Venereol.* 1988;68:87-89.
2. Wang HJ, Cheng TY, Chen TM. Modified Skoog procedure by an axillary bi-pedicle flap approach. *Plast Reconstr Surg.* 1996;98:524-529.
3. Endo T, Nakayama Y. Surgical treatment of axillary osmidrosis. *Ann Plast Surg.* 1993;30:136-139.
4. Apesos J, Chami R. Functional applications of suction-assisted lipectomy: a new treatment for old disorders. *Aesthetic Plast Surg.* 1991;15:73-79.
5. Glogau RG. Botulinum A neurotoxin for axillary hyperhidrosis: no sweat Botox. *Dermatol Surg.* 1998;24:817-819.
6. Odderson IR. Axillary hyperhidrosis: treatment with botulinum toxin A. *Arch Phys Med Rehabil.* 1998;79:350-352.
7. Bushara KO, Park DM, Jones JC, Schutta HS. Botulinum toxin: a possible new treatment for axillary hyperhidrosis. *Clin Exp Dermatol.* 1996;21:276-278.
8. Hsu CP, Chen CY, Lin CT, Wang JH, Chen CL, Wang PY. Video-assisted thoracoscopic T2 sympathectomy for hyperhidrosis palmaris. *J Am Coll Surg.* 1994;179:59-64.
9. Hsu CP, Douglas JM Jr. Thoracoscopic sympathectomy. In: Sabiston DC Jr, ed. *Atlas of Cardiothoracic Surgery.* Philadelphia, Pa: WB Saunders Co; 1995:573-575.
10. Fox AD, Hands L, Collin J. The results of thoracoscopic sympathetic trunk transection for palmar hyperhidrosis and sympathetic ganglionectomy for axillary hyperhidrosis. *Eur J Vasc Endovasc Surg.* 1999;17:343-346.
11. Rex LO, Drott C, Claes G, Gothberg G, Dalman P. The Boras experience of endoscopic thoracic sympathectomy for palmar, axillary, facial hyperhidrosis and facial blushing. *Eur J Surg.* 1998;580(suppl):23-26.
12. Nicholson ML, Dennis MJ, Hopkinson BR. Endoscopic transthoracic sympathectomy: successful in hyperhidrosis but can the indications be extended? *Ann R Coll Surg Engl.* 1994;76:311-314.
13. Byrne J, Walsh TN, Hederman WP. Endoscopic transthoracic electrocautery of the sympathetic chain for palmar and axillary hyperhidrosis. *Br J Surg.* 1990;77:1046-1049.
14. Lee DY, Hong YJ, Shin HK. Thoracoscopic sympathetic surgery for hyperhidrosis. *Yonsei Med J.* 1999;40:589-595.
15. Masters A, Rennie JA. Endoscopic transthoracic sympathectomy for idiopathic upper limb hyperhidrosis. *Clin Auton Res.* 1992;2:349-352.
16. Karamfilov T, Konrad H, Karte K, Wollina U. Lower relapse rate of botulinum toxin A therapy for axillary hyperhidrosis by dose increase. *Arch Dermatol.* 2000;136:487-490.
17. Naver H, Swartling C, Aquilonius SM. Palmar and axillary hyperhidrosis treated with botulinum toxin: one-year clinical follow-up. *Eur J Neurol.* 2000;7:55-62.
18. Hsu CP, Chen CY, Hsia JY, Shai SE. Resympathectomy for palmar and axillary hyperhidrosis. *Br J Surg.* 1998;85:1504-1505.