

Parathyroid Autotransplantation During Thyroidectomy

Documentation of Graft Function

Chung Yau Lo, MBBS(HK), MS(HK), FRCS(Edin); Sidney C. Tam, MBBS(HK), FRCP, FRCPA

Hypothesis: Biochemical function of normal parathyroid tissue grafted during thyroidectomy can be documented.

Design: An intervention study in which devascularized or inadvertently removed parathyroid glands are reimplanted in forearm muscle pockets during thyroidectomy. Postoperative serum parathyroid hormone levels were evaluated by venous sampling from both forearms on postoperative days 1, 3, 14, 28, 56, and 84.

Setting: Tertiary care teaching hospital.

Patients: Seven patients undergoing thyroidectomy at risk for postoperative hypocalcemia.

Results: A 1.5-fold gradient of parathyroid hormone measurements between grafted and nongrafted arms was demonstrated in all patients on postoperative day 28. A maximal parathyroid hormone gradient was reached on day 56, and biochemical function persisted in 6 patients on day 84.

Conclusions: Biochemical function of parathyroid glands reimplanted during thyroidectomy can be demonstrated objectively. The application of parathyroid autotransplantation may preserve parathyroid function for inadvertently removed or devascularized parathyroid glands during thyroid surgery.

Arch Surg. 2001;136:1381-1385

ALTHOUGH the practice of implanting parathyroid tissue has a long surgical tradition, the clinical utility of parathyroid transplantation (PTX) has not been explored until the past 20 years.¹ In general, indications for PTX include secondary hyperparathyroidism, primary parathyroid hyperplasia, recurrent or persistent hyperparathyroidism, and radical head and neck operations that include total thyroidectomy.¹⁻³ The functioning of parathyroid autografts has been widely documented in animal studies⁴⁻⁶ and clinically and biochemically for patients who undergo surgery for abnormal parathyroid diseases.⁷⁻⁹ The high success of PTX is attributed to the ability of parathyroid tissue to induce angiogenesis, as seen in the laboratory model.¹⁰

In contrast to PTX for parathyroid diseases, the functional evaluation of parathyroid autograft from normal parathyroid tissue during thyroid surgery has not been possible often because the most common place for autografting has been the sternocleidomastoid muscle. Unless routine removal of all parathyroid glands is

performed during thyroidectomy, functioning parathyroid tissue is left in the neck. As a result, objective determination of graft function has been almost impossible. Instead, this determination has been based on the resolution of clinically significant hypocalcemia or the recovery pattern of parathyroid hormone (PTH) level. The present study aims to document the biochemical function, if any, of the normal parathyroid gland grafted in the forearm during thyroidectomy.

RESULTS

The 7 patients are described in **Table 1**. They had a median age of 48 years (range, 30-77 years). The right and left forearms were used for PTX in 1 and 6 patients, respectively. The number of parathyroid glands seen during surgery ranged from 2 to 4. Three patients developed symptomatic hypocalcemia requiring replacement therapy to maintain normocalcemia before hospital discharge. Their PTH levels at postoperative day 1 were all below reference values (median, <1.4 pg/mL [<0.1 ng/L]; range, <1.4-4.9 pg/mL [$<0.1-0.5$ ng/L]) (reference range, 11-54

From the Departments of Surgery (Dr Lo) and Medicine (Dr Tam), University of Hong Kong Medical Center, Queen Mary Hospital.

PATIENTS AND METHODS

Seven patients were recruited to undergo PTX to their non-dominant forearm during thyroidectomy. Biochemical graft function was determined by measuring any differential difference or gradient in the PTH level of forearm venous samples between grafted and nongrafted arms during follow-up. Informed consent was obtained from all 7 patients. Inadvertently removed or devascularized parathyroid glands were removed and placed in ice-cold isotonic sodium chloride solution in preparation for autotransplantation. The nondominant forearm was chosen for PTX, which was performed as previously described.¹¹ A sliver of tissue was obtained from the reimplanted parathyroid tissue, with subsequent histologic confirmation in all patients. The parathyroid gland was minced into 0.5-mm fragments that were inserted into multiple muscle pockets in the brachioradialis muscle at the end of surgery. The muscle pockets were closed using small metallic clips or silk sutures.

Blood samples were drawn from both forearms at the antecubital fossae within 24 hours of surgery (day 1) and again at 3, 14 (2 weeks), 28 (1 month), 56 (2 months), and 84 (3 months) days after surgery. Prolonged use of a tourniquet was avoided before blood sampling. Three milliliters of venous blood were collected in plain bottles, which were immediately spun in a refrigerated centrifuge to separate serum from cells. Serum samples were stored at -80°C for 24 hours. Serum PTH concentrations were measured using a 2-site immunochemiluminometric assay (Magic-Lite System; Bayer Diagnostics, Leverkusen, Germany). In addition, serum calcium levels were measured every 12 to 24 hours. Replacement therapy with oral calcium supplements (calcium carbonate, 2-3 g daily) or vitamin D analog (calcitriol, 0.25-0.50 μg daily) (Roche Laboratories, Nutley, NJ) was begun when patients had symptomatic hypocalcemia or the serum calcium level was less than 6.8 mg/dL (<1.70 mmol/L) (reference range, 8.4-10.2 mg/dL [2.10 - 2.55 mmol/L]).

Table 1. Demographics, Indications for Surgery, Types of Operative Procedures Performed, and Number of Parathyroid Glands Autotransplanted and Detected in Resected Specimens in 7 Patients*

Age, y/Sex	Indication	Surgery	Autotransplanted, No.	Parathyroid Glands in Resected Specimens, No.	Calcium Supplement
30/F	Graves disease†	BST	1	0	No
48/F	Multinodular goiter	TT	1	0	No
76/M	Papillary carcinoma	TT+TL+SND	2	1	Yes
77/F	Toxic nodular goiter	TT	1	0	No
70/F	Papillary carcinoma	TT	2	0	No
32/F	Medullary carcinoma	TT	1	0	Yes
40/F	Papillary carcinoma	TT+SND	2	2	Yes

*BST indicates bilateral subtotal thyroidectomy; TT, total thyroidectomy; TL, total laryngectomy; and SND, selective neck dissection.

†Papillary microcarcinoma in specimen.

Table 2. Summary of Parathyroid Hormone (PTH) Measurements and Gradients Between Grafted and Nongrafted Arm Venous Samples*

Days, No.	PTH, pg/mL		Gradient (Grafted/Nongrafted)
	Grafted Arm	Nongrafted Arm	
0	12.7 \pm 5.1 (1.4-37.0)	9.2 \pm 3.6 (1.4-23.0)	1.4 \pm 0.3 (1.0-2.9)
3	12.8 \pm 5.3 (1.4-37.0)	9.6 \pm 4.2 (1.4-32.0)	1.3 \pm 0.1 (1.0-1.9)
14	41.0 \pm 13.3 (5.0-106.0)	13.5 \pm 4.2 (1.4-30.0)	5.6 \pm 2.7 (1.0-21.4)
28	71.7 \pm 27.0 (13.0-223.0)	17.2 \pm 4.6 (1.4-31.0)	5.2 \pm 1.1 (1.7-9.3)
56	93.4 \pm 35.5 (19.0-238.0)	16.8 \pm 5.3 (1.4-38.0)	15.1 \pm 6.8 (1.1-42.1)
84	140.1 \pm 49.8 (27.0-368.0)	21.1 \pm 2.1 (14.0-29.0)	7.6 \pm 3.4 (1.1-26.3)

*Data are given as mean \pm SE (range). To convert PTH from picograms per milliliter to nanograms per liter, multiply by 0.1053.

pg/mL [1.2 - 5.7 ng/L]). Use of the supplements was gradually discontinued 2 to 4 months after surgery, accompanied by normalization of PTH levels. The serum calcium level remained normal 2 weeks after discontinuation of calcium supplementation.

The PTH measurements and gradients between the grafted and nongrafted arm venous samples for all patients are summarized in **Table 2**. Three months after surgery, biochemical graft function persisted in 6 patients (86%), as seen by a greater than 1.5-fold serum PTH

gradient in the grafted vs nongrafted arm venous samples. **Figure 1** shows the PTH values of grafted and nongrafted forearm samples in individual patients with documented grafted function at 3 months. Biochemical graft function, as seen by a 1.5-fold gradient of PTH measurements between grafted and nongrafted arms, was demonstrated in all except 2 patients at 2 weeks and in all patients 1 month after autotransplantation. However, 1 patient had evidence of graft failure 2 months after PTX, with the abolishment of the PTH gradient, although the

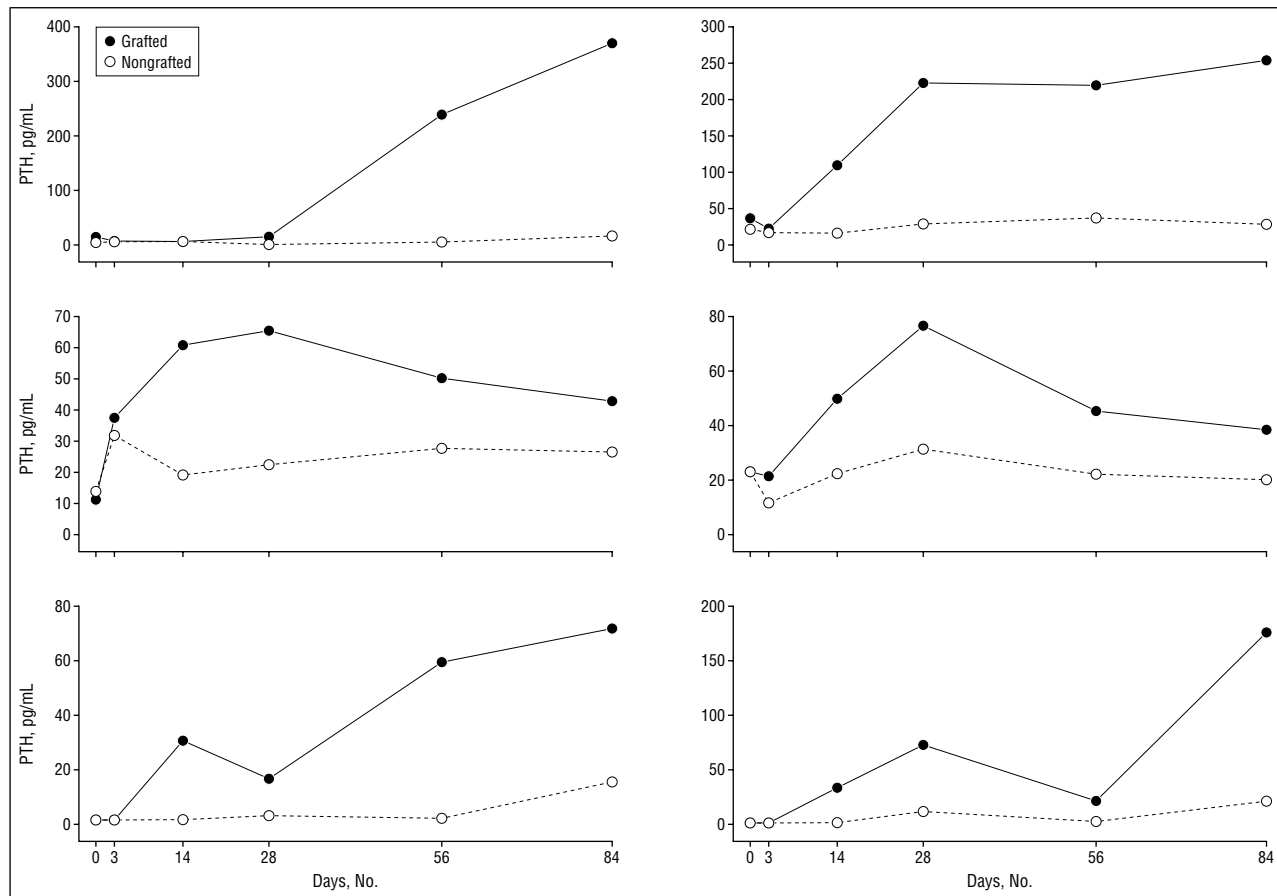


Figure 1. Parathyroid hormone (PTH) measurements from venous samples from grafted and nongrafted arms plotted against time for patients with functioning grafts. To convert PTH from picograms per milliliter to nanograms per liter, multiply by 0.1053.

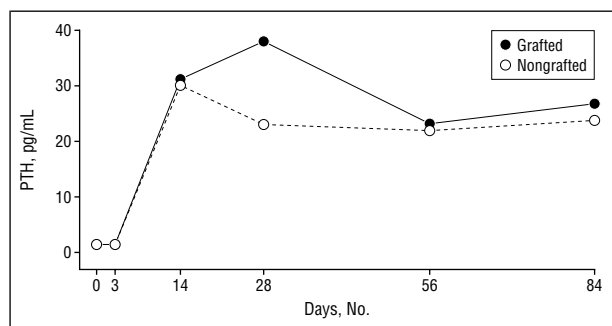


Figure 2. Parathyroid hormone (PTH) measurements in the patient with graft failure 3 months after surgery. To convert PTH from picograms per milliliter to nanograms per liter, multiply by 0.1053.

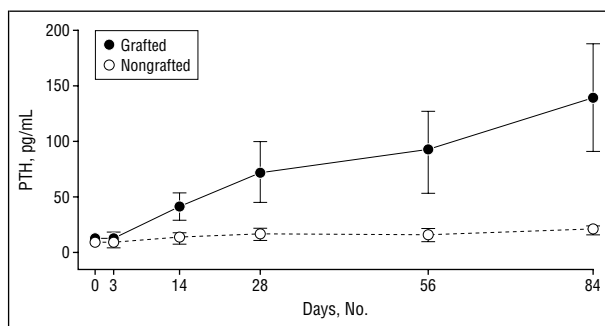


Figure 3. Parathyroid hormone (PTH) values from grafted and nongrafted arms measured during follow-up. All values are given as mean \pm SE.

serum PTH level remained within reference limits (**Figure 2**).

All patients had normal PTH levels in venous samples obtained from nongrafted forearms 3 months after surgery. The PTH measurements sampled from nongrafted arms were within the reference range in all patients during follow-up. Within the time scheduled for venous sampling during follow-up, PTH progressively recovered in venous samples from grafted and nongrafted forearms (**Figure 3**), and the overall maximal PTH hormone gradient was reached 2 months after surgery (**Figure 4**).

When the PTH measurement was compared between grafted and nongrafted arms, the difference was

statistically significant from postoperative day 14 onward ($P = .02$ by Wilcoxon signed rank test) but was not significantly different at days 1 and 3 ($P = .1$ and $.08$, respectively).

COMMENT

In 1958, Murray¹² proposed several criteria to evaluate successful endocrine transplantations, including (1) documented hormone deficiency before transplantation, (2) evidence of correction of hormonal deficiency after grafting, (3) microscopic evidence of graft survival, (4) return of hormonal deficiency after removal of the graft, and (5) postmortem evaluation of ectopic

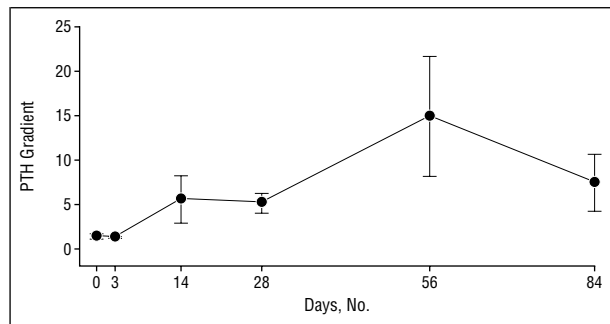


Figure 4. Parathyroid hormone (PTH) gradients between grafted and nongrafted arms during follow-up. All values are given as mean ± SE.

endocrine tissue. With reference to PTX, it is difficult to apply these unequivocal morphological and functional criteria to human studies. However, functional assessment of parathyroid autografts has included maintenance of normocalcemia without calcium supplementation, elevated PTH concentration in blood draining from the grafted site compared with systemic blood, increase in PTH level after transplantation, and graft uptake of radioisotopes.¹²

Wells et al¹ demonstrated successful PTX clinically and biochemically in a large series of patients who underwent surgery for hyperparathyroidism. In autotransplantation of parathyroid tissue during persistent primary, secondary, or tertiary hyperparathyroidism, forearm autotransplantation is usually performed to avoid reoperation on the neck and for easy monitoring of abnormal graft function.⁸ Direct evidence of graft function can be obtained by comparing PTH levels in grafted and nongrafted arms.^{7,8} In humans, a gradient of 1.5 or greater in PTH measurement between grafted and nongrafted arms has been generally accepted as proof of graft function.³ Success rates range from 55% to 100% after immediate autotransplantation of abnormal fresh parathyroid tissue.^{8,9,13}

Parathyroid autotransplantation has been performed in humans during partial thyroidectomy in an attempt to preserve parathyroid function.¹⁴ Lahey¹⁴ urged that any thyroid tissue surgically removed be carefully examined and that any parathyroid glands so extirpated be reimplanted. Despite being a procedure with a long tradition, biochemical graft function and the success of PTX during thyroid surgery cannot be easily documented. In fact, primary hyperparathyroidism may develop, albeit rarely, after autotransplantation of histologically normal parathyroid tissue during thyroid surgery.¹⁵ In contrast to autotransplantation of abnormal glands, successful PTX during thyroidectomy has been determined through the maintenance of normocalcemia without calcium supplementation after a period of postoperative hypocalcemia. Several studies on PTX during thyroidectomy determined graft function mainly based on biochemical analysis of the serum calcium concentration^{11,16,17} or infrequently on PTH measurement in peripheral circulation.^{18,19} Functional assessment of grafted function in humans based on the criteria of Murray¹² is impractical for PTX during thyroid surgery because functioning parathyroid tissue is left in the neck, and the parathyroid gland is usually transplanted in the neck muscle

for convenience without the need for an additional incision in the forearm. Funahashi et al¹⁸ documented the recovery patterns of the PTH level from undetectable to the preoperative level 2 weeks after autotransplantation of 2 to 4 parathyroid glands in 17 patients. They demonstrated that the graft functioned for a long time based on the intact PTH concentration in the peripheral circulation.¹⁹ However, measurement of hormone levels in the systemic circulation can be affected by the functional recovery of residual parathyroid tissue in the neck during the initial surgery. Direct assessment of graft function by demonstrating a PTH gradient between grafted and nongrafted arms should be more sensitive in documenting graft function.

The time necessary to develop function in transplanted tissue is of interest but difficult to ascertain. In the present study, we did not attempt to evaluate graft function during the immediate postoperative period. When intact PTH levels were used as the index of functional recovery of the transplanted gland, the PTH level returned to the preoperative level approximately 2 weeks after surgery.¹⁸ A study²⁰ of PTX of hyperplastic parathyroid glands showed that a small PTH gradient was apparent at 3 weeks but that 12 to 18 weeks were required to reach normal peripheral levels. In our study, it seemed that normal parathyroid tissue resumed function 2 to 4 weeks after reimplantation and became fully functional at 8 weeks.

A study²¹ of 32 children who underwent total thyroidectomy with PTX described using the forearm as the site for reimplantation in 26 patients. Serum PTH levels in 22 patients who had placement of parathyroid tissue into their forearms were measured, and in each there were increased PTH levels in the grafted arm compared with the nongrafted arm. The gradient was more than 1.5-fold in 20 (91%) of 22 patients.²¹ Another study²² of 12 patients with forearm PTX during thyroidectomy revealed biochemical graft function in 10 (83%) of 12 based on PTH measurements. Isotope uptake at the site of parathyroid autotransplant was demonstrated in all 7 patients evaluated in a study by Sierra et al.²²

Our study confirmed evidence of biochemical function from grafted normal parathyroid tissue as reflected by the PTH gradient between grafted and nongrafted arms, and our graft success rate compares favorably with others.^{21,22} One of our patients had 2 parathyroid glands autotransplanted, and 2 were discovered in the resected specimen. Graft function was indicated by an undetectable PTH level with development of hypocalcemia after surgery, the patient's gradual recovery, and an elevated PTH level in the venous sample of the grafted arm during follow-up. Without PTX, permanent hypoparathyroidism would have occurred.

The need for PTX in patients who do not develop postoperative hypocalcemia is controversial because the difference in PTH concentration between grafted and nongrafted forearms seems impractical in the presence of normal-functioning parathyroid tissue remaining in the neck. However, a high PTH level in the direct sampling of blood from venous effluent in close proximity to the site of PTH release²² provides indirect evidence of graft function. In our study, the reason for the presence of graft function

1 month after surgery followed by delayed graft failure in 1 patient is not fully understood.

In conclusion, biochemical function of parathyroid autografts during thyroid surgery can be documented objectively, and the value of PTX can be confirmed. Based on the results of the present study, we cannot recommend routine PTX during all thyroidectomies; however, inadvertently removed or devascularized parathyroid glands identified should be routinely autotransplanted to preserve parathyroid function and prevent permanent hypoparathyroidism.

Corresponding author and reprints: Chung Yau Lo, MBBS(HK), Division of Endocrine Surgery, Department of Surgery, University of Hong Kong Medical Center, Queen Mary Hospital, 102 Pokfulam Rd, Hong Kong (e-mail: cylo@hkucc.hku.hk).

REFERENCES

1. Wells SA Jr, Ross AJ, Dale JK, Gray RS. Transplantation of the parathyroid glands: current status. *Surg Clin North Am*. 1979;59:167-177.
2. Baumann DS, Wells SA Jr. Parathyroid autotransplantation. *Surgery*. 1993;113:130-133.
3. Saxe A. Parathyroid transplantation: a review. *Surgery*. 1984;95:507-526.
4. Halsted WFP. Auto and iso-transplantation in dogs of the parathyroid granules. *J Exp Med*. 1908;11:175-198.
5. Leight GS, Parker GA, Sears HF, Marx SJ, Terrill RE. Experimental cryopreservation and autotransplantation of parathyroid glands: technique and demonstration of function. *Ann Surg*. 1978;188:16-21.
6. Prigouris S, Lorentziadis M, Stylogiannis S, Nafas R, Masouras A, Poulantzas I. Experimental autotransplantation of the parathyroid gland. *Br J Surg*. 1996;83:410-412.
7. Hickey RC, Samaan NA. Human parathyroid autotransplantation: proved function by radioimmunoassay of plasma parathyroid hormone. *Arch Surg*. 1975;110:892-895.
8. Walgenbach S, Hommel G, Junginger T. Prospective evaluation of parathyroid graft function after total parathyroidectomy and heterotopic autotransplantation in renal hyperparathyroidism by bilateral determination of intact parathormone in cubital venous blood. *World J Surg*. 1998;22:93-98.
9. Feldman AL, Sharaf RN, Skarulis MC, et al. Results of heterotopic parathyroid autotransplantation: a 13-year experience. *Surgery*. 1999;126:1042-1048.
10. Carter WB, Uy K, Ward MD, Hoying JB. Parathyroid-induced angiogenesis is VEGF dependent. *Surgery*. 2000;128:458-464.
11. Lo CY, Lam KY. Postoperative hypocalcemia in patients who did or did not undergo parathyroid autotransplantation during thyroidectomy: a comparative study. *Surgery*. 1998;124:1081-1087.
12. Murray JE. Evaluation of endocrine transplants. *Transplant Bull*. 1958;5:369-370.
13. Herrera M, Grant C, van Heerden JA, Fitzpatrick LA. Parathyroid autotransplantation. *Arch Surg*. 1992;127:825-830.
14. Lahey FH. The transplantation of parathyroids in partial thyroidectomy. *Surg Gynecol Obstet*. 1922;62:508-509.
15. D'Avanzo A, Parangi S, Mortia E, Duh QY, Siperstein AE, Clark OH. Hyperparathyroidism after thyroid surgery and autotransplantation of histologically normal parathyroid glands. *J Am Coll Surg*. 2000;190:546-552.
16. Walker RP, Paloyan E, Keley TF, Gopalsami C, Jarosz H. Parathyroid autotransplantation in patients undergoing a total thyroidectomy: a review of 261 patients. *Otolaryngol Head Neck Surg*. 1994;111:258-264.
17. Olson JA Jr, DeBenedetti MK, Baumann DS, Wells SA Jr. Parathyroid autotransplantation during thyroidectomy: results of long-term follow-up. *Ann Surg*. 1996;223:472-480.
18. Funahashi H, Satoh Y, Imai T, et al. Our technique of parathyroid autotransplantation in operation for papillary thyroid carcinoma. *Surgery*. 1992;114:92-96.
19. Kikumori T, Imai T, Tanaka Y, Oiwa M, Mase T, Funahashi H. Parathyroid autotransplantation with total thyroidectomy for thyroid carcinoma: long-term follow-up of grafted parathyroid function. *Surgery*. 1999;125:504-508.
20. Mallette LE, Eisenberg K, Wilson H, Noon GP. Generalized primary parathyroid hyperplasia: studies of the evolution of autogenous parathyroid graft function. *Surgery*. 1983;93:254-259.
21. Skinner MA, Norton JA, Moley JF, DeBenedetti MK, Wells SA Jr. Heterotopic autotransplantation of parathyroid tissue in children undergoing total thyroidectomy. *J Pediatr Surg*. 1997;15:688-692.
22. Sierra M, Herrera MF, Herrero B, et al. Prospective biochemical and scintigraphic evaluation of autografted normal parathyroid glands in patients undergoing thyroid operations. *Surgery*. 1998;124:1005-1010.