

Answer

Gastropericardial Fistula

The patient's history and physical examination, as well as the results of the chest radiography, led us to suspect a gastropericardial fistula. A subsequent computed tomographic scan of the chest and abdomen revealed a recurrent tumor of the colon invading the fundus and body of the stomach, with an extensive presence in the spleen, diaphragm, pericardium, and left hepatic lobe. Orally administered contrast material filled the colon, the lumen of the fistula, and the pericardial cavity, which confirmed the diagnosis (**Figure 2**). Subsequently, esophagogastroduodenoscopy was performed to assess the exact location of the fistula and the possible modes of treatment. The fistula in the fundus of the stomach was visualized as being surrounded by neoplasms. The fistula was approximately 5 mm in diameter and was not wide enough to pass the gastroscope. The esophagogastroduodenoscopy did not alter the treatment plan.

Unfortunately, a radical resection was not feasible owing to an extensive local invasion into the adjacent organs. Because the patient demonstrated signs and symptoms of pericardial tamponade on admission, an emergency pericardiocentesis was performed, and a percutaneous pericardial tube was subsequently inserted for drainage. Antibiotics and opioids were also administered. The pericardial tube was removed after a week of treatment, and tamponade did not recur. The patient was subsequently transferred to a palliative care unit. No recurrence of tamponade was observed, but the patient died 4 weeks later of complications due to the progression of the disease.

The signs and symptoms that are present in patients with a gastropericardial fistula may result from 3 underlying causes: the presence of air in the pericardial cavity, pericarditis, and cardiac tamponade. Retrosternal or substernal pain radiating to the left shoulder (a sign of diaphragmatic irritation), tympanitic percussion, and metallic splashing sounds synchronous with the heart sounds during auscultation are typical for pneumopericardium. The presence of high-grade fever, chills, an elevated white blood cells count, and elevated C-reactive protein levels indicate

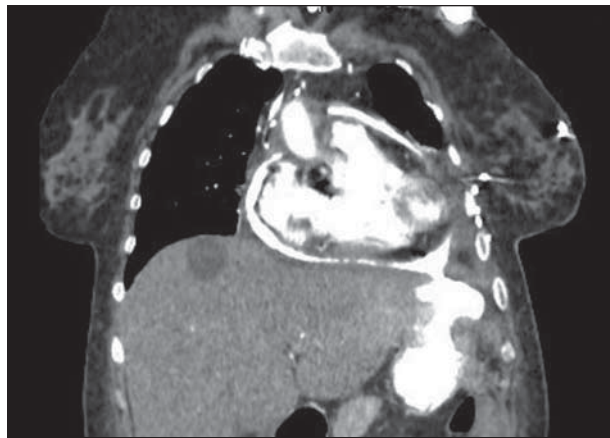


Figure 2. Computed tomographic scan of the chest and abdomen of a 63-year-old woman after contrast material was orally administered.

imminent purulent pericarditis. Tachycardia, hypotension, dyspnea, and distended neck veins are signs of pericardial tamponade and require emergency intervention.¹

The presence of air in the pericardial sac may be visualized on a chest radiograph. A computed tomographic scan of the chest and abdomen is helpful for confirming the diagnosis and for planning treatment.² Esophagogastroduodenoscopy may provide additional information but should be used with caution. It is hypothesized that the insufflation of air may cause pericardial tamponade.³ Although no such cases have been described to date, esophagogastroduodenoscopy should be considered a high-risk procedure for this type of patient, and additional safety measures (ie, the potential need for emergency pericardiocentesis) should be implemented.

Gastropericardial fistula is an extremely rare clinical entity. It can be a complication of various nonmalignant (peptic ulcer perforation or hiatal hernia) and malignant diseases (esophageal, gastric, or colon cancer), as well as a complication due to previous surgical procedures (Nissen fundoplication or esophagectomy).⁴

A gastropericardial fistula that complicates locally advanced colon cancer is particularly difficult to treat and can be considered a preterminal event. Although an attempt to resect a fistula of nonmalignant etiology with the interposition of a pedicled muscle flap and with lavage and drainage of the pericardial cavity is usually successful, we were not able to find any reports of malignant fistulas that were treated with radical surgery. In refractory cases, the pericardial window may be necessary for palliation.

Accepted for Publication: January 11, 2012.

Correspondence: Piotr Gabryel, MD, Department of Thoracic Surgery, Poznań University of Medical Sciences, ul Szamarzewskiego 62, Poznań 60-569, Poland (piotrgabryel@gmail.com).

Author Contributions: *Study concept and design:* Gabryel, Gąsiorowski, and Dyszkiewicz. *Acquisition of data:* Gabryel and Gałęcki. *Analysis and interpretation of data:* Gabryel and Dyszkiewicz. *Drafting of the manuscript:* Gabryel and Gałęcki. *Critical revision of the manuscript for important intellectual content:* Gąsiorowski and Dyszkiewicz. *Study supervision:* Dyszkiewicz.

Conflict of Interest Disclosures: None reported.

REFERENCES

1. Luthi F, Groebli Y, Newton A, Kaeser P. Cardiac and pericardial fistulae associated with esophageal or gastric neoplasms. *Int Surg.* 2003;88(4):188-193.
2. Kaur H, Singh D, Kirschner ES, Maxwell JS. True heartburn. *J Clin Gastroenterol.* 2001;32(5):458.
3. Wegryn RL, Zaroff LI, Weiner RS. Spontaneous tension pneumopericardium. *N Engl J Med.* 1968;279(26):1440-1441.
4. Chinnaiyan KM, Ali MI, Gunaratnam NT. Gastric cancer presenting as gastropericardial fistula in a patient with familial adenomatous polyposis syndrome. *J Clin Gastroenterol.* 2004;38(3):298.