

# A Simple Method for Safe Identification of the Facial Nerve Using Palpable Landmarks

José A. Pereira, MD; Alex Merí, PhD; José María Potau, MD; Alberto Prats-Galino, MD; Joan José Sancho, MD; Antonio Sitges-Serra, MD

**Hypothesis:** External palpable landmarks can be used to identify the facial nerve trunk quickly and safely.

**Design:** Prospective anatomical dissection study.

**Setting:** University department of human anatomy and university hospital.

**Methods:** A total of 40 human cadaver heads (79 facial nerves) were dissected by 2 prosectors, a surgeon with experience in the anatomy of the parotid region (J.A.P.; n=39) and a medical student with experience in anatomical dissection and basic knowledge of the facial nerve disposition (A.M.; n=40). A 3-cm skin incision was made in the center of the triangle formed by the temporomandibular joint, the mastoid process, and the angle of the mandible, and dissection was continued deep until the main facial nerve trunk was identified.

**Main Outcome Measures:** The time taken from the skin incision to the identification of the nerve was monitored with a chronometer by an independent observer. The distance between the predicted and actual position of the facial nerve was measured.

**Results:** In all cases, the facial nerve was identified and there were no significant differences in the dissection time between the 2 prosectors (144 vs 148 seconds). The mean distance between the predicted and the actual position of the nerve was 1.42 mm.

**Conclusion:** The proposed localization landmarks allowed a fast and safe identification of the facial nerve and may be of significant help during surgery around the parotid region.

*Arch Surg.* 2004;139:745-747

**R**EASONABLE SPEED AND safety in identifying and preserving important anatomical structures are of vital importance for successful surgery in all specialties. In some circumstances, such as thyroidectomy or parotidectomy, the final success of the operation depends to a vast extent on the safe handling of the recurrent laryngeal or facial nerves.

## See Invited Critique at end of article

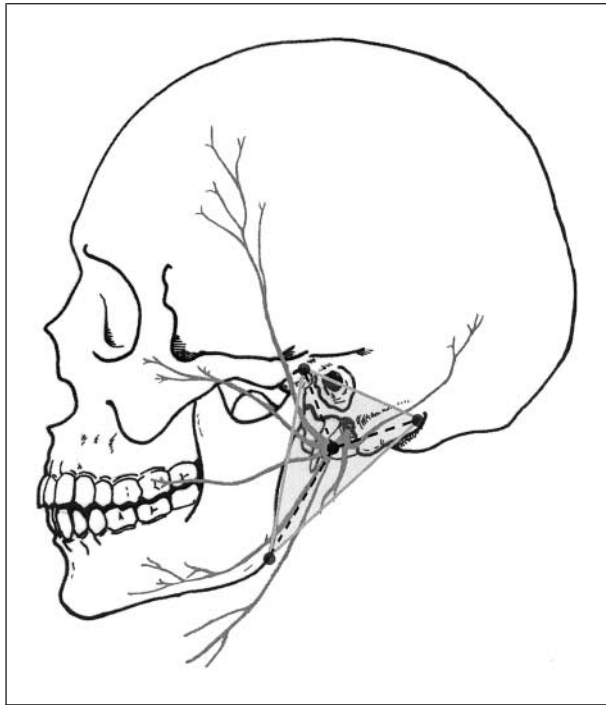
In the absence of preoperative methods allowing the precise location of relevant anatomical structures, surgeons require a system of references that enable them to predict with safe margins the location of the anatomical structure to be preserved. This system of references can only be based on anatomical landmarks.<sup>1</sup> Topographical alterations caused by the underlying surgical disease or related to the normal variations among individuals

may result in major changes of the normal anatomy of the key structures to be dissected. For this reason, the anatomical landmarks guiding the surgeon throughout any intervention must meet the following characteristics: (1) easy to identify, (2) keep their position throughout the whole procedure, (3) be easily palpable independent of the position of the patient, and (4) allow the speedy and safe identification of the anatomical structure to be preserved.

The identification of the facial nerve in the parotid region—be it during parotidectomy or for repair of facial trauma—is a paradigmatic procedure. Both the main trunk and peripheral branches must be identified and preserved to prevent permanent aesthetic sequelae and medico-legal actions related to facial paralysis.

Several methods have been devised for the identification of the facial nerve trunk during parotidectomy,<sup>2-4</sup> even to predict the disposition of its branches preoperatively.<sup>5-7</sup> The most frequently used references for its intraoperative localization

From the Departament de Ciències Experimentals i de la Salut, Universitat Pompeu Fabra (Drs Pereira and Merí), the Departament d'Anatomia i Embriologia Humana, Facultat de Medicina, Universitat de Barcelona (Drs Potau and Prats-Galino), and the Departament de Cirurgia, Hospital del Mar (Drs Sancho and Sitges-Serra); Barcelona, Spain.



Drawing showing the anatomical landmarks, the reference triangle, and the location of the facial nerve.

are the retromandibular vein,<sup>8</sup> the tympanomastoid fissure,<sup>9-11</sup> the tragal pointer,<sup>9</sup> and the styloid process of the temporal bone.<sup>12</sup> The most used anatomical landmark is the tympanomastoid fissure since it has shown its efficacy as a reference in comparison with other techniques allowing the identification of the facial nerve with a precision within the 3-mm range.<sup>11</sup>

The present study set out to investigate the ease and accuracy of facial nerve identification using the center of the triangle formed by the temporomandibular joint, the mastoid process, and the angle of the mandible as the anatomical landmark (**Figure**). These reference points were chosen because they meet the 3 aforementioned requisites.

## METHODS

A total of 40 human cadaver heads either fresh (n=15) or preserved in formaldehyde (n=25) were dissected (17 male and 23 female with a mean age of 80 years). Heads were sectioned sagittally and dissected by 2 investigators, a surgeon with experience in the parotid region (J.A.P.; n=39) and a medical student with experience in anatomical dissection and basic anatomical knowledge of the facial nerve anatomy (A.M.; n=40). A total of 79 dissections were performed. One specimen could not be used because of previous mandibular resection and radiotherapy because of an oral cancer.

The approach to the trunk of the facial nerve involves 3 steps. First, the 3 anatomical landmarks were identified by palpation and marked with color needles. The first point was at the center of the temporomandibular joint. From that point, a line was traced crossing the center of the external acoustic meatus until it reached the posterior border of the mastoid process where the second point was marked. The third landmark was placed at the vertex of the mandible angle (Figure) and the reference triangle was delineated.

The second step involved marking the predicted position of the facial nerve at the center of the reference triangle with a

perpendicularly inserted hypodermic needle (0.8 × 40 mm; Micro-lance 3; Becton Dickinson, Madrid, Spain). All references were chosen by means of palpation and not by objective measurements. Finally, the third step was to make a longitudinal incision of 3 cm at the guiding needle position without removing it. The dorsal border of the parotid gland was retracted anteriorly or the dissection progressed across the gland whenever necessary, with blunt dissection using a Reynolds-type scissors (model 08.325.15; Dimeda, Rhineland, Germany) following the needle until the trunk of the facial nerve was located. Once identified, the facial nerve was dissected until its trunk and its major 2 branches were individualized. At this point, the distance between the theoretical and the actual position of the facial nerve trunk was registered.

Measurements were made at the end of the procedure by each prosector using a caliper. Calculation of the reference triangle area was done on a computer using the Heron formula, which uses the length of each side of the triangle.

The whole dissection process, from the skin incision until the identification of the trunk and the 2 divisions of the facial nerve, was monitored with a chronometer by an independent observer.

At the end of the procedure, the correct location of the nerve was double-checked by enlarging the incision to confirm the position of the nerve and the integrity of its branches.

Results were statistically analyzed with the Statview 4 package (SAS Institute Inc, Cary, NC). The unpaired, 2-tailed *t* test was used to compare quantitative variables with normal distribution between the 2 prosectors. Statistical significance was established at  $P < .05$ .

## RESULTS

The 79 facial nerves were uneventfully dissected and preserved. Neither the major trunk nor its division were damaged during the procedure. The results of the measurements are presented in **Table 1**. Both prosectors safely identified the facial nerve in fewer than 3 minutes with no significant differences in the duration of the procedure between the 2. Neither were there major differences in the distance between the predicted and the actual localization site. The dimensions (side length and area) of the reference triangle drawn by the 2 prosectors were similar with only the anterior side showing some (4 mm) difference.

There were no significant differences in the time to identify the nerve nor in the distance between the theoretical and actual nerve localization between male and female specimens. As expected, the dimensions (sides and area) of the reference triangle were higher in male specimens (**Table 2**).

## COMMENT

The anatomical triangle proposed in this study is a modification of that described in textbooks of surgical anatomy.<sup>1,13,14</sup> There are no references, however, about the usefulness and effect of the use of these landmarks in current surgical practice. In our opinion, the adoption of this type of anatomical orientation could make surgery around the parotid region safer and quicker.

Our approach offers substantial advantages when compared with other methods. It predicts nerve position accurately; the 3 anatomical landmarks are easy to

**Table 1. Results of Dissections Performed by Each Prosector\***

Prosector	Time, s	Distance, mm	Area, cm <sup>2</sup>	Height, cm	Triangle Mean Dimensions, cm		
					Superior Side	Posterior Side	Anterior Side
1	144 (67)	1.62 (1.10)	12.20 (2.07)	4.43 (0.37)	5.10 (0.46)	5.50 (0.64)	5.40 (0.48)
2	148 (74)	1.21 (0.89)	11.60 (2.40)	4.36 (0.62)	5.20 (0.50)	5.30 (0.64)	5.00 (0.80)†
Average	146 (71)	1.42 (1.04)	11.90 (2.20)	4.40 (0.51)	5.10 (0.48)	5.40 (0.64)	5.20 (0.68)

\*Values are expressed as mean (SD). Prosector 1 (author José Antonio Pereira, MD) is a surgeon with experience in the anatomy of the parotid region. Prosector 2 (author Alex Meri, PhD) is a medical student with experience in anatomical dissection and basic knowledge of the facial nerve disposition. †P = .03.

**Table 2. Comparison of Measurements Made in Both Sexes of Cadaver Heads\***

Sex	Time, s	Distance, mm	Area, cm <sup>2</sup>	Height, cm	Triangle Mean Dimensions, cm		
					Superior Side	Posterior Side	Anterior Side
Male (n = 33)	152 (9)	1.59 (1.11)	13.10 (2.17)	4.54 (0.50)	5.40 (0.44)	5.70 (0.59)	5.40 (0.62)
Female (n = 46)	142 (52)	1.30 (0.98)	11.10 (1.92)	4.29 (0.50)†	5.00 (0.45)†	5.20 (0.58)†	5.00 (0.68)†

\*Values are expressed as mean (SD). †P < .03.

identify by palpation at all times during surgery and are not distorted by the underlying pathologic features. Surgeons with different skill levels, as shown by our data, can reproduce the technique easily, and the final result seems not to be influenced by the expected normal anatomical variations.

There are few studies demonstrating the efficacy of specific dissecting techniques to locate the facial nerve. The most complete study, by de Ru et al,<sup>11</sup> investigated the distance of 30 facial nerve trunks to single anatomical landmarks. The anatomical reference with the best yield (range, 3 mm) was the tympanomastoid fissure. This study, however, did not report the dissection time, and the best anatomical reference was determined on the basis of measurements made at the end of the dissection and a subjective assessment score based on the opinion of 2 experienced surgeons. The present study improves the accuracy reported by de Ru et al<sup>11</sup> and permits the identification of the facial nerve in fewer than 3 minutes. So far, none of the studies has reported time to nerve identification as a parameter to determine the adequacy of the dissection technique. The tragal pointer is often used as a reference, although there is no empirical evidence to suggest that it is better than other approaches.<sup>11</sup> Learning to use this landmark requires more surgical expertise and does not predict more accurately the position of the facial nerve trunk than other methods reported.

The main innovation of our approach lies in the ease with which the anatomical landmarks are located. This allows even a nonexperienced prosector to locate the facial trunk with relative ease. This is important in circumstances in which facial nerve identification becomes difficult because of bleeding.

In conclusion, the anatomical landmarks put forward in our study make facial dissection safe and speedy mostly because they can be palpated at all times during

the procedure. This technique can be easily applied to all surgical procedures in or around the parotid region.

Accepted for publication November 18, 2003.

Correspondence: Antonio Sitges-Serra, MD, Department of Surgery, Hospital del Mar, Passeig Marítim, 25-29, 08003 Barcelona, Spain (asitges@imas.imim.es).

## REFERENCES

1. Behrns OH. The surgical anatomy and technique of parotidectomy. *Surg Clin North Am.* 1977;57:477-493.
2. Wong DS. Surface landmarks of the facial nerve trunk: a prospective measurement study. *Anz J Surg.* 2001;71:753-756.
3. Nahlieli O, Levy Y. Intraoperative staining with methylene blue as an aid to facial nerve identification in parotid gland surgery. *J Oral Maxillofac Surg.* 2001;59:355-356.
4. Lin SD, Tsai CC, Lai CS, Lee SS, Chang KP. Endoscope-assisted parotidectomy for benign parotid tumors. *Ann Plast Surg.* 2000;45:269-273.
5. de Ru JA, Bleyers RL, van Benthem PP, Hordijk GJ. Preoperative determination of the location of parotid gland tumors by analysis of the position of the facial nerve. *J Oral Maxillofac Surg.* 2001;59:525-528.
6. de Ru JA, van Benthem PP, Hordijk GJ. The location of parotid gland tumors in relation to the facial nerve on magnetic resonance images and computed tomography scans. *J Oral Maxillofac Surg.* 2002;60:992-994.
7. Tada Y, Inamura H, Takahashi N, Sugai Y, Aoyagi M. Identification of the intraparotid facial nerve on magnetic resonance imaging. *Acta Otolaryngol Suppl.* 2000;542:49-53.
8. Kopuz C, Ilgi S, Yavuz S, Onderoglu S. Morphology of the retromandibular vein in relation to the facial nerve in the parotid gland. *Acta Anat (Basel).* 1995;152:66-68.
9. Hogg SP, Katz RC. Surgical exposure of the facial nerve. *Arch Otolaryngol.* 1958;67:560-561.
10. Robertson MS, Blake P. A method of using the tympanomastoid fissure to find the facial nerve at parotidectomy. *Aust N Z J Surg.* 1984;54:369-373.
11. de Ru JA, van Benthem PP, Bleyers RL, Lubsen H, Hordijk GJ. Landmarks for parotid gland surgery. *J Laryngol Otol.* 2001;115:122-125.
12. Lathrop FD. Technique of exposing the facial nerve as an aid to surgery of the parotid gland. *Surg Clin North Am.* 1949;29:673-677.
13. Carlson G. The salivary glands: embryology, anatomy and surgical applications. *Surg Clin North Am.* 2000;80:261-273.
14. Skandalakis JE, Skandalakis PN, Skandalakis LJ, Skandalakis J. *Surgical Anatomy and Technique.* New York: Springer-Verlag New York; 1999.