

## Image of the Month

Stacey D. Moore-Olufemi, MD; Angela Cheng, MD; Gary A. Vercruyse, MD

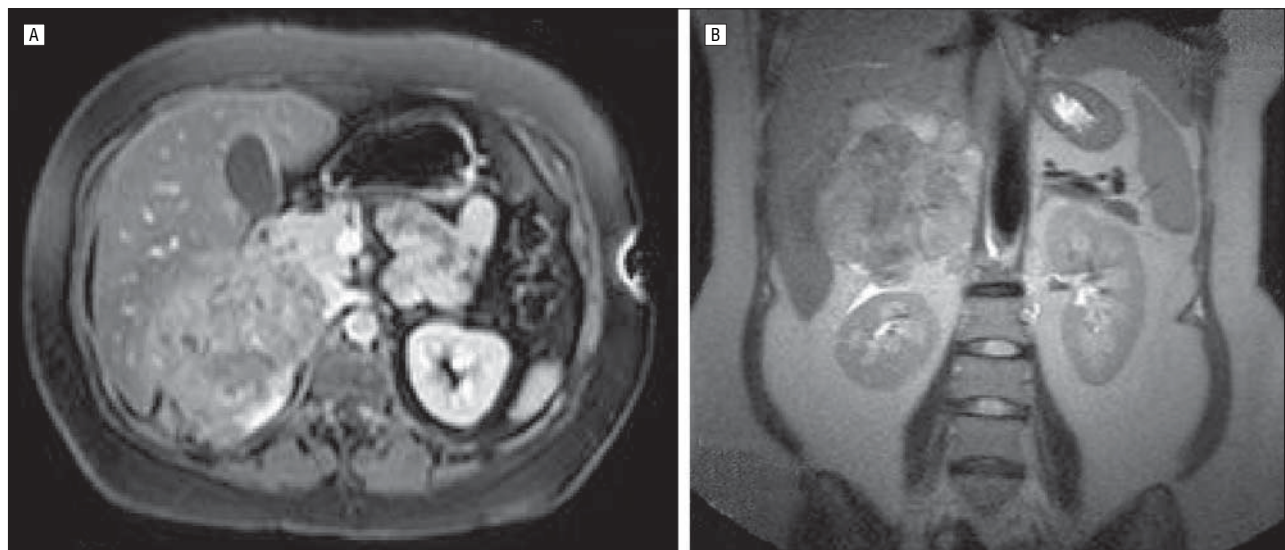
**A** 26-YEAR-OLD WOMAN WAS ADMITTED TO our hospital, a few months after giving birth to her second child, with a history of new-onset uncontrolled hypertension and diabetes diagnosed during her second pregnancy. The patient underwent early induction of her labor because her symptoms were thought to be secondary to preeclampsia. After delivery, the patient

continued to have severe hypertension and hyperglycemia not controlled by maximum antihypertensive and glucose-control medications. A magnetic resonance image was obtained (**Figure**). The patient underwent exploratory laparotomy with right adrenalectomy and oophorectomy.

### What Is the Diagnosis?

- A. Renal cell carcinoma
- B. Pheochromocytoma
- C. Neuroblastoma
- D. Adrenocortical carcinoma

Author Affiliations: Department of Surgery, University of Texas Medical School at Houston.



**Figure.** Magnetic resonance images. A, Transverse view of the abdomen showing a right-sided mass. B, Coronal view of the intra-abdominal mass with questionable liver invasion.