PAPER

Predicting Nodal Status Using Dynamic Contrast-Enhanced Magnetic Resonance Imaging in Patients With Locally Advanced Breast Cancer Undergoing Neoadjuvant Chemotherapy With and Without Sequential Trastuzumab

David J. Hsiang, MD; Maki Yamamoto, MD; Rita S. Mehta, MD; Min-Ying Su, PhD; Choong H. Baick, MD; Karen T. Lane, MD; John A. Butler, MD

Hypothesis: Dynamic contrast-enhanced (DCE) magnetic resonance imaging (MRI) is a reliable and accurate method for monitoring primary tumor response in the breast and can be used as a surrogate to predict final axillary nodal status.

Design: Retrospective study (October 1, 2004, through February 28, 2006) of 46 patients with clinically staged locally advanced breast cancer.

Setting: Comprehensive cancer center.

Patients: Forty-six patients with locally advanced breast cancer.

Interventions: Neoadjuvant chemotherapy (NAC), DCE-MRI, mastectomy and lumpectomy, and axillary lymph node dissection.

Main Outcome Measures: The DCE-MRI results and pathologic response of the breast and axillary lymph nodes.

Results: Forty-six patients underwent NAC with doxorubicin hydrochloride and cyclophosphamide, followed by paclitaxel and carboplatin, with or without trastuzumab based on human epidermal growth factor receptor 2 (HER2/neu) status. Twenty-one patients (46%) had a complete pathologic response. For the HER2/neu-positive patients, the complete pathologic response rate was 70% (14/20). The accuracy, sensitivity, and specificity of the primary tumor response in predicting the axillary nodal status were 78%, 88%, and 72%, respectively. The accuracy, sensitivity, and specificity of the DCE-MRI–measured response in the primary tumor in predicting axillary nodal status were 74%, 62%, and 82%, respectively. For the HER2/neu-positive patients, the accuracy, sensitivity, and specificity improved to 80%, 75%, and 82%, respectively.

Conclusions: The results of DCE-MRI of the primary tumor can be predictive of axillary nodal status, especially in patients receiving trastuzumab who are HER2/neu positive. The HER2/neu-positive patients with a complete clinical response on DCE-MRI are highly unlikely to benefit from an axillary lymph node dissection. For HER2/neu-negative patients, sentinel lymph node sampling is warranted.

Arch Surg. 2007;142(9):855-861

THE OPTIMAL MANAGEMENT of axillary lymph nodes in patients with locally advanced breast cancer (LABC) remains a complex therapeutic problem.[1] Locally advanced breast cancer represents 5% to 20% of all newly diagnosed breast cancers in the United States, with a higher incidence in medically underserved areas.[2] During the past several decades, treatment for LABC has evolved from radical mastectomy to the use of neoadjuvant chemotherapy (NAC) followed by a mastectomy and an axillary node dissection.[3] The possibility of "lesser" surgery (breast conservation) has only recently been introduced because of the increased effectiveness of NAC regimens.

The optimal intensity and duration of NAC for LABC still remain controversial because of the difficulty in evaluating response to therapy.[2,4,5] Response to treatment has traditionally been assessed by physical examination, mammography, and/or ultrasonography. Several studies[6-8] have shown significant discrepancies between the clinical assessment of response to NAC and the pathologic assessment of response found in posttherapy surgical specimens.

Author Affiliations: Chao Family Comprehensive Cancer Center, University of California, Irvine, Orange.

©2007 American Medical Association. All rights reserved.
Downloaded From: http://archsurg.jamanetwork.com/ on 01/24/2017

Table 1. Characteristics of 46 Patients With Locally Advanced Breast Cancer Who Underwent Neoadjuvant Chemotherapy

Characteristic	No. (%) of Patients
Age, y	
≤50	21 (46)
>50	25 (54)
Size of tumor, cm	
≥5.0	32 (70)
2.1-4.9	12 (26)
≤2.0	2 (4)
Clinical node status (prechemotherapy)	
Positive	39 (85)
Negative	7 (15)
HER2/neu status	
Positive	20 (44)
Negative	26 (56)
Estrogen receptor status	
Positive	27 (59)
Negative	19 (41)

Newer imaging modalities are being tested to improve the presurgical assessment of residual disease after chemotherapy. Dynamic contrast-enhanced (DCE) magnetic resonance imaging (MRI) was recently shown to be accurate in determining both the tumor response and the amount of residual disease remaining in patients who have undergone NAC for LABC.[9-11]

Dynamic contrast-enhanced MRI has the ability to distinguish postchemotherapeutic fibrotic changes from vascularized tumor tissue based on the evaluation of tissue morphologic features and signal intensity changes after contrast medium administration.[12,13] The contrast agent used has both an intravascular and interstitial distribution that allows for increased signal intensity at sites of angiogenic foci, which correlates with viability of the residual tumor.

To date, no large studies have addressed the imaging of the axillary nodal status of patients who have undergone NAC for LABC. A few articles[14,15] are available on the use of ultrasmall superparamagnetic iron oxide agents with MRI, with and without positron emission tomography, in the assessment of axillary lymph node metastases before therapy in patients with breast cancer. The results of these studies are promising, but the sample sizes are small and the results are preliminary. The aim of this study is to evaluate the use of DCE-MRI in the measurement of residual disease in the primary breast tumor as a surrogate maker for disease status in the axilla for patients with LABC undergoing NAC.

METHODS

PATIENT SELECTION

From October 1, 2004, through February 28, 2006, a retrospective review of an ongoing prospective study, approved by the University of California, Irvine, institutional review board, identified 46 patients with LABC who underwent NAC with or without trastuzumab. Core needle biopsy specimens were obtained for all primary tumors before NAC. A small subset of patients underwent fine needle aspiration of their axillary nodes to detect the presence or absence of disease. The mean age of the group was 50 years (range, 30-70 years). The size of the tumor at presentation was greater than or equal to 5.0 cm in 32 patients (70%), 2.1 to 4.9 cm in 12 patients (26%), and less than or equal to 2.0 cm in 2 patients (4%). Thirty-nine patients (85%) were found on clinical examination to have involved axillary adenopathy at presentation. The remaining 7 patients (15%) had a clinically negative axilla at presentation. The human epidermal growth factor receptor 2 (HER2/neu) status was determined in all 46 patients. Twenty patients (44%) had an amplification of the *HER2/neu* gene. Twenty-seven patients (59%) had a positive estrogen receptor status (**Table 1**).

Thirty-five of the 46 patients were followed up sequentially with DCE-MRI throughout the chemotherapy regimen. Eleven patients did not undergo the DCE-MRI imaging protocol but completed the NAC protocol. The MRI sequencing consisted of a baseline study before induction of chemotherapy followed by 2 MRI measurements before the change of chemotherapeutic agents and a final MRI measurement before a partial mastectomy or mastectomy with a complete axillary lymph node dissection.

MRI STUDY PROTOCOL

The MRI study was performed using a 1.5-T Phillips Eclipse magnetic resonance scanner with a standard bilateral breast coil (Philips Medical Systems, Cleveland, Ohio). The imaging protocol consisted of high-resolution precontrast imaging, DCE imaging, and proton chemical-shift spectroscopic imaging. After the intravenous line was placed, the patient was placed into the scanner in a prone position. The breasts were gently cushioned inside the coil with rubber foam to reduce motion. Next a localizer study was performed to define the location of the breasts, sagittal view unilateral T1-weighted precontrast images were acquired from the breast of concern, using a spin echo pulse sequence with a repetition time of 1000 milliseconds, an echo time of 12 milliseconds, a field of vision of 20 cm, and a matrix size of 256×256. Thirty to 40 slices with 3- to 4-mm thickness were prescribed to cover the entire breast and part of the axillary region. After this, a 3-dimensional gradient echo sequence (radiofrequency-Fourier acquired steady state [RF-FAST]) pulse sequence with 16 frames (repetitions) was prescribed for bilateral dynamic imaging. Thirty-two axial slices with 4-mm thickness were used to cover both breasts. The imaging acquisition parameters were a repetition time of 8.1 milliseconds, an echo time of 4.0 milliseconds, a flip angle of 20°, a matrix size of 256×128, and a field of vision of 38 cm. The imaging time was 42 seconds per acquisition. The sequence was repeated 16 times for dynamic acquisitions (4 precontrast and 12 postcontrast sets). The contrast agent (Omniscan, 1 mL per 10 lb of body weight) was manually injected at the beginning of the fifth acquisition and was timed to finish in 12 seconds to make the bolus length consistent for all patients. Immediately after the contrast, 10 mL of isotonic sodium chloride solution was injected to flush in all the contrast medium.

TUMOR SIZE AND THERAPY RESPONSE EVALUATION

Two-dimensional tumor size was measured for evaluating therapy response. Measurement of the longest diameter and the longest perpendicular diameter of the tumor was performed based on maximum intensity projection of the subtraction images. The precontrast images acquired at the third frame in the DCE-MRI sequence were subtracted from the postcontrast images acquired at the sixth frame (approximately 1 minute after injection) to obtain subtraction images for each of the 32 slices, and the maxi-

©2007 American Medical Association. All rights reserved.
Downloaded From: http://archsurg.jamanetwork.com/ on 01/24/2017

mum intensity projection from these subtraction images was generated. One operator (M.-Y.S.) performed the size measurement for all patients. The pretreatment and posttreatment tumor sizes were measured during the same sitting to minimize any intrapatient variation in tumor definition. The product of the bidimensional diameters (product of the longest diameter and the longest perpendicular diameter) was then calculated, and the tumor size change was measured as the percentage change with respect to that in the baseline MRI. For those patients with multiple differentiable lesions, the largest lesion was used as the index lesion. The processing of subtraction, maximum intensity projection, and size measurements was performed using ImageJ software (National Institutes of Health, Bethesda, Md; http://rsb.info.nih.gov/ij/, 1.30v). The response to NAC was classified based on the Response Evaluation Criteria in Solid Tumors Groups criteria.[16,17] The primary lesion was measured with the longest diameter to be recorded. A complete response was defined as the disappearance of the primary lesion and all other secondary lesions. A partial response was at least a 30% decrease in the sum of the longest diameter of the primary and secondary lesions. Progressive disease was classified as at least a 20% increase in the total diameters of the lesions (**Figure**).

CHEMOTHERAPY REGIMEN

All patients received a chemotherapy regimen that consisted of 60 mg of doxorubicin hydrochloride intravenously per square meter of body surface area and 600 mg of cyclophosphamide intravenously per square meter every 14 days for 2 to 4 cycles, depending on clinical response. In addition, 500 µg of granulocyte-macrophage colony-stimulating factor was injected subcutaneously, beginning more than 72 hours after the treatments for 7 to 10 days. This treatment was followed sequentially with 80 mg of paclitaxel intravenously per square meter, as well as carboplatin equal to the area under the curve of 2, for 1 hour once a week for 3 weeks followed by 1 week off, for 9 to 12 doses. The HER2/neu-positive patients received trastuzumab intravenously in a loading dose of 4 mg/kg of body weight on day 1 of the first cycle, followed by a dose of 2 mg/kg once a week for 12 to 16 doses.

HER2/neu TESTING

Before beginning NAC, all the patients had histologically proven breast cancer. The biopsy specimens were tested for HER2/neu based on the American Society of Clinical Oncology/College of American Pathologists guidelines.[18] The HER2/neu status was determined by immunohistochemical assay and/or fluorescence in situ hybridization. Positive HER2/neu status was determined by an immunohistochemical assay result of 3+ and a fluorescence in situ hybridization ratio of 2 or more.

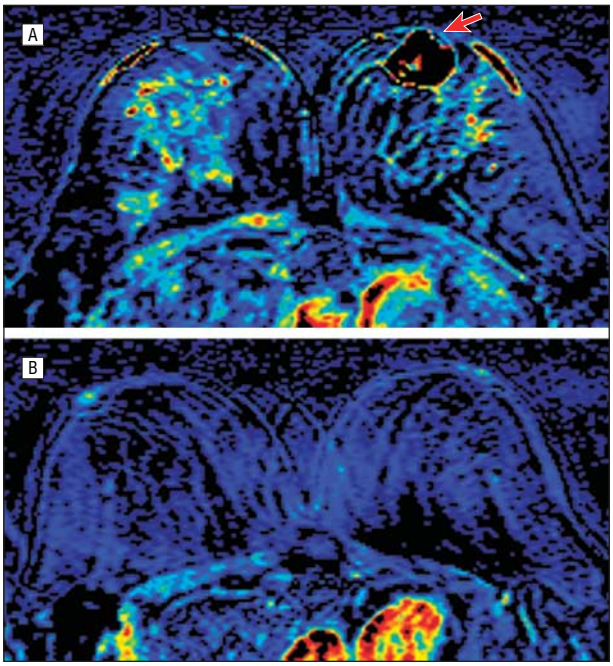

Figure. Magnetic resonance images from baseline to after completion of neoadjuvant chemotherapy. A, Baseline (arrow indicates area of malignancy). B, Clinical complete response after completion of neoadjuvant chemotherapy.

Table 2. Pathologic Response to Neoadjuvant Chemotherapy and Surgical Resection Performed

Characteristic	No. (%) of Patients (N=46)[a]		
Final Pathologic Response			
Complete response	21 (46)		
Partial response	23 (50)		
No response	2 (4)		
Final Pathologic Response Based on HER2/neu Status			
	Complete Response	Partial Response	No Response
HER2/neu positive	14	6	0
HER2/neu negative	7	17	2
Final Surgical Procedure			
Lumpectomy	20 (43)		
Mastectomy	26 (56)		

[a] Data are presented as number (percentage) of patients unless otherwise indicated.

RESULTS

All 46 patients underwent NAC with 2 to 4 cycles of doxorubicin and cyclophosphamide followed sequentially by paclitaxel, with or without trastuzumab, based on HER2/neu status. This treatment was followed by either lumpectomy or mastectomy with axillary nodal dissection, depending on residual disease and patient preference. In addition, 20 patients (43%) underwent sentinel lymph node biopsy (SLNB) via isosulfan blue and radioisotope mapping after NAC. The sentinel node identification rate was 100%.

In the overall group of 46 patients, the complete pathologic response rate was 46% (21/46), the partial pathologic response rate was 50% (23/46), and 4% (2/46) had no response. The HER2/neu-positive patients had a complete pathologic response rate of 70% (14/20) vs 27% (7/26) for the HER2/neu-negative patients. Twenty-six patients (56%) elected to have a mastectomy, and the remaining 20 received a lumpectomy or segmental resection (**Table 2**).

When the primary tumor response was used as a surrogate marker to predict the axillary lymph node status, the accuracy, sensitivity, and specificity were 78%, 88%, and 72%, respectively, with a negative predictive value (NPV) of 91% (**Table 3**). Thirty-five patients were followed up with serial DCE-MRI throughout chemotherapy. The accuracy, sensitivity, and specificity of the primary tumor response in pre-

©2007 American Medical Association. All rights reserved.
Downloaded From: http://archsurg.jamanetwork.com/ on 01/24/2017

Table 3. Primary Tumor Response to Neoadjuvant Chemotherapy as a Marker for Axillary Lymph Node Response[a]

Breast Pathologic Response	Axillary Lymph Node Pathologic Response: Positive	Negative	Total
Positive	15	8	**23**
Negative	2	21	**23**
Total	**17**	**29**	**46**

[a]Sensitivity was 88% (95% confidence interval [CI], not available); specificity, 72% (95% CI, 56%-89%); negative predictive value, 91% (95% CI, not available); and accuracy, 78% (95% CI, 66%-90%).

Table 4. Primary Tumor Response to Neoadjuvant Chemotherapy as a Marker for Axillary Lymph Node Response Based on HER2/neu Status Breast Pathologic Response

Breast Pathologic Response	Axillary Lymph Node Pathologic Response: Positive	Negative	Total
Total No. of patients[a]			
Positive	12	5	**17**
Negative	1	17	**18**
Total	**13**	**22**	**35**
HER2/neu-positive patients[b]			
Positive	4	0	**4**
Negative	0	11	**11**
Total	**4**	**11**	**15**
HER2/neu-negative patients[c]			
Positive	8	5	**13**
Negative	1	6	**7**
Total	9	11	**20**

[a]Sensitivity, 92% (95% confidence interval [CI], not available); specificity, 77% (95% CI, 60%-95%); negative predictive value, 94% (95% CI, not available); and accuracy, 83% (95% CI, 70%-95%).
[b]Sensitivity, 100%; specificity, 100%; negative predictive value, 100%; and accuracy, 100%.
[c]Sensitivity, 89% (95% CI, not available); specificity, 55% (95% CI, 25%-84%); negative predictive value, 86% (95% CI, not available); and accuracy, 70% (95% CI, 50%-90%).

dicting the axillary lymph node status in this MRI subgroup were 83%, 92%, and 77%, respectively, with an NPV of 94%. When stratified on the basis of HER2/neu status, the accuracy, sensitivity, specificity, and NPV were all 100% for the HER2/neu-positive patients and 70%, 89%, 55%, and 86%, respectively, for the HER2/neu-negative patients (**Table 4**).

When comparing the DCE-MRI–measured response of the primary tumor with the final pathologic test results (breast specimen), the accuracy was 69%, the sensitivity was 53%, the specificity was 83%, and the NPV was 65%. When stratified for HER2/neu status, HER2/neu-positive patients had an accuracy of 80%, a sensitivity of 75%, a specificity of 82%, and an NPV of 90%, compared with 60%, 46%, 86%, and 46%, respectively, for the HER2/neu-negative patients (**Table 5**).

Finally, the DCE-MRI–measured response of the primary tumor was compared with the residual disease in the axillary nodes. The accuracy, sensitivity, specificity, and NPV were 74%, 62%, 82%, and 78%, respectively. For the HER2/neu-positive patients, the rates were 80%, 75%, 82%, and 90%, respectively. For the HER2/neu-negative patients, the rates were 70%, 56%, 82%, and 69%, respectively (**Table 6**).

Table 5. DCE-MRI Evaluation of Primary Tumor Response to Neoadjuvant Chemotherapy Based on HER2/neu Status

DCE-MRI	Tumor Pathologic Response: Positive	Negative	Total
Total No. of patients[a]			
Positive	9	3	12
Negative	8	15	23
Total	**17**	**18**	**35**
HER2/neu-positive patients[b]			
Positive	3	2	5
Negative	1	9	10
Total	**4**	**11**	**15**
HER2/neu-negative patients[c]			
Positive	6	1	7
Negative	7	6	13
Total	**13**	**7**	**20**

Abbreviations: DCE, dynamic contrast-enhanced; MRI, magnetic resonance imaging.
[a]Sensitivity, 53% (95% confidence interval [CI], 29%-77%); specificity, 83% (95% CI, not available); negative predictive value, 65% (95% CI, 38%-92%); and accuracy, 69% (95% CI, 53%-84%).
[b]Sensitivity, 75% (95% CI, not available); specificity, 82% (95% CI, not available); negative predictive value, 90% (95% CI, not available); and accuracy, 80% (95% CI, 60%-100%).
[c]Sensitivity, 46% (95% CI, 19%-73%); specificity, 86% (95% CI, not available); negative predictive value, 46% (95% CI, 9%-83%); and accuracy, 60% (95% CI, 39%-81%).

Table 6. DCE-MRI Evaluation of Axillary Nodal Response to Neoadjuvant Chemotherapy Based on HER2/neu Status

DCE-MRI	Axillary Lymph Node Pathologic Response: Positive	Negative	Total
Total No. of patients[a]			
Positive	8	4	**12**
Negative	5	18	**23**
Total	**13**	**22**	**35**
HER2/neu-positive patients[b]			
Positive	3	2	**5**
Negative	1	9	**10**
Total	**4**	**11**	**15**
HER2/neu-negative patients[c]			
Positive	5	2	**7**
Negative	4	9	**13**
Total	**9**	**11**	**20**

Abbreviations: DCE, dynamic contrast-enhanced; MRI, magnetic resonance imaging.
[a]Sensitivity, 62% (95% confidence interval [CI], 35%-88%); specificity, 82% (95% CI, 66%-98%); negative predictive value, 78% (95% CI, not available); and accuracy, 74% (95% CI, 60%-89%).
[b]Sensitivity, 75% (95% CI, not available); specificity, 82% (95% CI, not available); negative predictive value, 90% (95% CI, not available); and accuracy, 80% (95% CI, 60%-100%).
[c]Sensitivity, 56% (95% CI, 23%-88%); specificity, 82% (95% CI, not available); negative predictive value, 69% (95% CI, not available); and accuracy, 70% (95% CI, 50%-90%).

©2007 American Medical Association. All rights reserved.
Downloaded From: http://archsurg.jamanetwork.com/ on 01/24/2017

COMMENT

The increasing use of NAC in LABC, coupled with the improved efficacy of newer regimens,[19] raises questions concerning the efficacy of routine axillary lymph node dissections performed in this group of patients. Currently, controversy exists about the utility of SLNB and the timing of the procedure (either before or after NAC).[20] To date, several small, single-institution studies[21-24] and 1 large, multi-institution collaborative study[25] on determining the optimal timing of the SLNB have been published. Questions have been raised about the effect of chemotherapy on lymphatic drainage patterns in the breast and whether chemotherapy has a similar effect on nodal disease as on the primary tumor. Interestingly, several studies have shown that NAC will downstage axillary nodal status in 20% to 30% of patients. The use of SLNB would be ideal in this setting to identify individuals who will not benefit from an axillary lymph node dissection after therapy. Although the published results on the timing of the SLNB are conflicting, all agree that SLNB will likely replace routine axillary lymph node dissection in the future management of LABC treated with NAC.

Until this question of the timing of SLNB is resolved, other imaging modalities are being evaluated to assess disease status in the axilla after NAC. The imaging modalities most commonly used to assess the axilla include computed tomography and ultrasonography. This assessment is based mainly on measurements of nodal dimensions, such as maximum transverse diameter[26,27] or ratios of maximum longitudinal to maximum transverse diameter.[28] Morphologic criteria, such as shape, absence of fatty hilus, and thickening of the lobular cortex, are also used to better discriminate between malignant and benign nodes. All of these criteria remain controversial, and their accuracy varies widely. To date, no large trials have demonstrated any imaging technique that can accurately assess the nodal disease in the preoperative patient after NAC. The most promising new technique is the use of ultrasmall superparamagnetic iron oxide agents with MRI, with and without positron emission tomography, in the assessment of axillary lymph node metastases before therapy in patients with breast cancer.[14,15]

Dynamic contrast-enhanced MRI was shown to be accurate in measuring the presence or absence of residual disease in the breasts of patients who had undergone NAC before surgery. This increased ability to discriminate between postchemotherapy fibrosis vs tumor vascularization is based on the use of the contrast agents that have both an intravascular and interstitial distribution.[12,13] This approach allows for increased signal intensity at sites of angiogenic foci, which studies have shown correlates with the viability of the residual tumor.

In our study, a pathologic complete response was obtained in 46% (21/46) of the patients receiving NAC. When stratified on the basis of HER2/neu status, a 70% complete response (14/20) was noted in the HER2/neu-positive group compared with 27% (7/26) for the HER2/neu-negative group. The pathologic analysis of the breast and axillary content demonstrated that the residual disease status of the primary tumor was predictive of disease status in the axilla (accuracy, 78%; sensitivity, 88%; specificity, 72%; and NPV, 91%). This correlation was exceptionally strong in HER2/neu-positive patients in whom the accuracy, sensitivity, specificity, and NPV were all 100%.

The accuracy of DCE-MRI in determining residual disease in the breast specimens of the 35 patients evaluated by DCE-MRI was 69%. There were 8 false-negative MRI readings. The residual disease in the breast specimens ranged in size from a 1.2-cm mass to a 1.5-mm focus of invasive cells (median, 2 mm). Seven of the 8 residual disease specimens were in the HER2/neu-negative group. There was only 1 false-negative MRI reading in the HER2/neu-positive group, in which there was a 2.5-mm focus of residual disease. The accuracy of the HER2/neu-positive group was 80%, with a sensitivity of 75%, a specificity of 82%, and an NPV of 90%. These rates were much higher than the overall group and the HER2/neu-negative group.

The DCE-MRI assessment of the primary tumor was then correlated with the disease status of the axillary nodes. As a surrogate marker for axillary disease status, the accuracy, specificity, specificity, and NPV of the DCE-MRI results in predicting axillary status were 74%, 62%, 82%, and 78%, respectively. Five false-negative readings were found in the overall group, with 1 false-negative reading in the HER2/neu-positive group. The residual disease in the HER2/neu-positive group was in 1 node and was 4 mm in size surrounded by postchemotherapy changes. This positive node was 1 of 11 from an axillary lymph node dissection. A sentinel lymph node biopsy was not performed in this patient.

In conclusion, the increasing efficacy of NAC for treating LABC mandates an individualized surgical approach based on response to therapy. The results of DCE-MRI of the breast were accurate in predicting the nodal status of the axilla after NAC. This correlation is especially strong in HER2/neu-positive patients receiving trastuzumab. The HER2/neu-positive patients with a complete clinical response on DCE-MRI after NAC are highly unlikely to benefit from an axillary lymph node dissection. For HER2/neu-negative patients, sentinel lymph node sampling is warranted for evaluation of the axillary nodal status after NAC.

Submitted for Publication: February 16, 2007; final revision received May 7, 2007; accepted May 8, 2007.
Correspondence: David J. Hsiang, MD, University of California Irvine Medical Center, 101 The City Drive South, Bldg 56, Route 81, Orange, CA 92868 (dhsiang@uci.edu).
Author Contributions: *Study concept and design:* Hsiang, Mehta, Su, Baick, and Butler. *Acquisition of data:* Hsiang, Yamamoto, Mehta, Su, and Butler. *Analysis and interpretation of data:* Hsiang, Yamamoto, Mehta, Su, Lane, and Butler. *Drafting of the manuscript:* Hsiang, Yamamoto, Mehta, Su, Baick, and Butler. *Critical revision of the manuscript for important intellectual content:* Hsiang, Yamamoto, Su, Lane, and Butler. *Statistical analysis:* Yamamoto. *Obtained funding:* Hsiang, Mehta and Su. *Administrative, technical, and material support:* Hsiang, Su, and Butler. *Study supervision:* Hsiang, Mehta, Su, Baick, Lane, and Butler.

©2007 American Medical Association. All rights reserved.
Downloaded From: http://archsurg.jamanetwork.com/ on 01/24/2017

Financial Disclosure: None reported.
Funding/Support: This study was supported by grant R01 CA90437 from the National Cancer Institute, National Institutes of Health (Dr Su), and by Berlex (Dr Mehta).
Previous Presentation: This paper was presented at the 78th Annual Meeting of the Pacific Coast Surgical Association; February 18, 2007; Kohala Coast, Hawaii; and is published after peer review and revision. The discussions that follow this article are based on the originally submitted manuscript and not the revised manuscript.

REFERENCES

1. Carlson RW, Favert AM. Multidisciplinary management of locally advanced breast cancer. *Breast J*. 1999;5(5):303-307.
2. Mankoff DA, Dunnwald LK, Gralow JR, Ellis GK, Drucker MJ, Livingston RB. Monitoring the response of patients with locally advanced breast carcinoma to neoadjuvant chemotherapy using [technetium 99m]–sestamibi scintimammography. *Cancer*. 1999;85(11):2410-2423.
3. Esteva FJ, Hortobagyi GN. Advances in breast cancer therapy. *Hematol Oncol Clin North Am*. 1999;13(2):458-473.
4. Hortobagyi GN. Comprehensive management of locally advanced breast cancer. *Cancer*. 1990;66(6)(suppl):1387-1391.
5. De Lena M, Varini M, Zucali R. Multimodal treatment for locally advanced breast cancer: result of chemotherapy-radiotherapy versus chemotherapy-surgery. *Cancer Clin Trials*. 1981;4(3):229-236.
6. Feldman LD, Hortobagyi GN, Buzudar AU, Ames FC, Blumenschein GR. Pathological assessment of response to induction chemotherapy in breast. *Cancer Res*. 1986;46(5):2578-2581.
7. Helvie MA, Joynt LK, Cody RL, Pierce LJ, Adler DD, Merajve SD. Locally advanced breast carcinoma: accuracy of mammography versus clinical examination in the prediction of residual disease after chemotherapy. *Radiology*. 1996; 198(2):327-332.
8. Vinnicombe SJ, MacVicar AD, Guy RL, et al. Primary breast cancer: mammographic changes after neoadjuvant chemotherapy, with pathologic correlation. *Radiology*. 1996;198(2):333-340.
9. Conrad C, Corfitsen MT, Gyldholm N, Christiansen FL. Pre-operative MR mammography in breast cancer patients. *Eur J Surg Oncol*. 1999;25(2):142-145.
10. Esserman L, Hylton N, Yassa L, Barclay J, Frankel S, Sickles E. Utility of magnetic resonance imaging in the management of breast cancer: evidence for improved preoperative staging. *J Clin Oncol*. 1999;17(1):110-119.
11. Partridge SC, Gibbs JE, Lu Y, Esserman LJ, Sudilovsky D, Hylton NM. Accuracy of MR imaging for revealing residual breast cancer in patients who have undergone neoadjuvant chemotherapy. *AJR Am J Roentgenol*. 2002;179(5):1193-1199.
12. Stomper PC, Winston JS, Herman S, Klippenstein DL, Arredondo MA, Blumenson LE. Angiogenesis and dynamic MR imaging gadolinium enhancement of malignant and benign breast lesions. *Breast Cancer Res Treat*. 1997;45(1): 39-46.
13. Belli P, Costantini M, Malaspina C, Magistrelli A, Latorre G, Bonomo L. MRI accuracy in residual disease evaluation in breast cancer patients treated with neoadjuvant chemotherapy. *Clin Radiol*. 2006;61(11):946-953.
14. Stadnik TW, Everaert H, Makkat S, Sacre R, Lamote J, Bourgain C. Breast imaging: preoperative breast cancer staging: comparison of USPIO-enhanced MR imaging and 18F-fluorodeoxyglucose (FDC) positron emission tomography (PET) imaging for axillary lymph node staging–initial findings. *Eur Radiol*. 2006;16(10):2153-2160.
15. Memarsadeghi M, Riedl CC, Kaneider A, et al. Axillary lymph node metastases in patients with breast carcinomas: assessment with nonenhanced versus USPIO-enhanced MR imaging. *Radiology*. 2006;241(2):367-377.
16. Park JO, Lee SI, Song SY, et al. Measuring response in solid tumors: comparison of RECIST and WHO response criteria. *Jpn J Clin Oncol*. 2003;33(10): 533-537.
17. Padhani AR, Ollivier L. The RECIST (Response Evaluation Criteria in Solid Tumors) criteria: implications for diagnostic radiologists. *Br J Radiol*. 2001;74 (887):983-986.
18. Wolff AC, Hammond EH, Schwartz JN, et al. American Society of Clinical Oncology/ College of American Pathologists guideline recommendations for human epidermal growth factor receptor 2 testing in breast cancer. *J Clin Oncol*. 2007; 25(1):118-145.
19. Mehta RS, Schubbert T, Kong K, Hsiang D, Butler J, Baick C. Pathologic response (pCR) following weekly (wkly) paclitaxel (cremophor or albumin-bound) and carboplatin (TC) ± trastuzumab (H), ± bevacizumab (B) in patients (pts) with doxorubicin/cyclophosphamide-resistant (AC-Res) and AC-sensitive (AC-S) large and inflammatory breast cancer (BC) [abstract 591]. *J Clin Oncol*. 2007;25(18S).
20. Jones JL, Zabicki K, Christian RL, et al. A comparison of sentinel node biopsy before and after neoadjuvant chemotherapy: timing is important. *Am J Surg*. 2005; 190(4):517-520.
21. Breslin TM, Cohen L, Sahin A, et al. Sentinel lymph node biopsy is accurate after neoadjuvant chemotherapy for breast cancer. *J Clin Oncol*. 2000;18(20):3480-3486.
22. Nason KS, Anderson BO, Byrd DR, et al. Increased false negative sentinel node biopsy rates after preoperative chemotherapy for invasive breast carcinoma. *Cancer*. 2000;89(11):2187-2194.
23. Julian TB, Patel N, Dusi D, et al. Sentinel lymph node biopsy after neoadjuvant chemotherapy for breast cancer. *Am J Surg*. 2001;182(4):407-410.
24. Haid A, Tausch C, Lang A, et al. Is sentinel lymph node biopsy reliable and indicated after preoperative chemotherapy in patients with breast carcinoma? *Cancer*. 2001;92(5):1080-1084.
25. Mamounas EP, Brown A, Anderson S, et al. Sentinel node biopsy after neoadjuvant chemotherapy in breast cancer: results from National Surgical Adjuvant Breast and Bowel Project Protocol B-27 (published correction appeared in *J Clin Oncol*. 2005;23(21):4808). *J Clin Oncol*. 2005;23(12):2694-2702.
26. Shin JH, Choi HY, Moon BI, Sung SH. In vitro sonographic evaluation of sentinel lymph nodes for detecting metastasis in breast cancer: comparison with histopathologic results. *J Ultrasound Med*. 2004;23(7):923-928.
27. Close LG, Merkel M, Vuitch MF, Reisch J, Schaefer SD. Computed tomographic evaluation of regional lymph node involvement in cancer of the oral cavity and oropharynx. *Head Neck*. 1989;11(4):309-317.
28. Shetty MK, Carpenter WS. Sonographic evaluation of isolated abnormal axillary lymph nodes identified on mammograms. *J Ultrasound Med*. 2004;23(1): 63-71.

DISCUSSION

John T. Vetto, MD, Portland, Oregon: There is an old saying, "If you want to get 6 opinions on how to treat breast cancer, ask 3 specialists." This saying has become all the more true in the era of the moving target of NAC for breast cancer. As the authors correctly point out, recent years have seen a plethora of papers presenting conflicting evidence and conclusions on every aspect of this treatment.

In fact, while the authors begin the paper with a statement that NAC is now considered the standard of care for locally advanced disease, I feel that even this statement is still debatable. While it is the standard of care in some centers, in others it is still being done on study. The reason for this spectrum of care is that this treatment has not yet been definitively shown to improve survival in all subgroups in all studies. It is clear that NAC does 2 things that postoperative therapy cannot: it downsizes tumors, potentially increasing the chance for successful lumpectomy for patients interested in a breast-preserving option, and it provides an in vivo biological test of tumor sensitivity to the drugs chosen.

As strategies for neoadjuvant treatment have improved, we are seeing an increasing percentage of patients who experience a pathologic complete response (CR) in the tumor and the nodes; an amazing 50% and 91%, respectively, in this study of patients treated with a fairly intensive carboplatin-containing chemotherapy regimen. This leaves patients and their medical oncologists asking us as surgeons how can we best evaluate the nodal response after chemotherapy and before subsequent operation and whether we should even be surgically staging the axilla in patients who have experienced a clinical CR.

To answer the first question, the authors looked at MRI evaluation of the primary tumor post chemotherapy, and they compared the results to postoperative breast and axillary dissection pathology to determine if MRI tumor assessment could serve as a surrogate for nodal status. Sensitivity was only 62%, but specificity and negative predictive value were higher. I took this to mean that MRI is best at predicting that nodes will be negative if the primary tumor is gone on subsequent imaging. This

©2007 American Medical Association. All rights reserved.
Downloaded From: http://archsurg.jamanetwork.com/ on 01/24/2017

seemed particularly true for HER2/neu-positive patients receiving preoperative trastuzumab, a group for whom the pathologic CR rates were particularly high in this study (70%).

I congratulate the authors for doing such a timely study, and a fairly "clean" one; all of their patients had axillary dissections so that we have complete nodal information, and the tumor response was recorded using RECIST [Response Evaluation Criteria in Solid Tumors Groups] criteria. Furthermore, they did try to answer the difficult question of how to surgically address the axilla after NAC. They suggest that for HER2/neu-positive tumors, routine axillary dissection may not be beneficial if the patient has had a clinical CR in the tumor.

At OHSU [Oregon Health & Science University] it is our routine to take the patients to the operating room and perform an SLNB at the same time that we place the port for chemotherapy and put a clip in to mark the tumor. We feel that performing sentinel node biopsy before chemotherapy more accurately stages the disease and eliminates the controversy about accuracy of SLNB after NAC. However, then the question arises whether one should complete the axillary dissection after chemotherapy if the sentinel lymph node was positive and the MRI shows a CR. As the authors have pointed out, a limitation of this study is the small numbers. Without comparative statistics, I am not convinced from these data that we can omit a completion dissection based on MRI assessment for patients with clinical CR.

I was therefore glad to learn that the authors plan to expand the size and hence the power of this study. I have 4 questions for the authors:

First, I note that in this series 15% of the patients were node negative and 30% had T1 or T2 lesions. How are you selecting patients for NAC at your institution?

Second, how are the authors using SLNB in their practice? Specifically, can you clarify how you plan to use these results to guide axillary staging for HER2/neu-positive tumors? On the basis of these data, are you currently omitting completion axillary dissection for HER2/neu patients with a clinical CR?

Regarding other imaging modalities of the nodes, my third question is, Have you looked at ultrasound staging of nodes during adjuvant therapy? In a recent study by Patel (Patel NA, Piper G, Patel JA, Malay MB, Julian TB. Accurate axillary nodal staging can be achieved after neoadjuvant therapy for locally advanced breast cancer. *Am Surg.* 2004;70[8]:696-699), ultrasound was 87% sensitive for predicting tumor response and was particularly useful if the residual tumor was 6 mm or larger. However, I should also note that ultrasound was not found to be accurate in a 2004 study done at Chapel Hill (Klauber-Demore N, Kuzmiak C, Rager EL, et al. High-resolution axillary ultrasound is a poor prognostic test for determining pathologic lymph node status in patients undergoing neoadjuvant chemotherapy for locally advanced breast cancer. *Am J Surg.* 2004;188[4]:386-389).

Finally, rather than using MRI to assess the primary tumor response as a surrogate for the nodal status, several groups have reported on the use of ultrasmall supraparamagnetic iron oxide–enhanced MRI to look directly at the nodes. Groups from Europe have reported accuracy rates with this technique as high as 98%. Do the authors have any experience with this MRI technique?

Dr Butler: Dr Vetto's first question was how we select patients for neoadjuvant treatment. Most of these patients had stage III, stage IIIA-IIIB, or stage IV disease. We will only include stage II patients with positive lymph nodes (IIB). We are beginning to assess neoadjuvant hormonal therapy in early-stage disease, but only in a protocol setting.

Another question Dr Vetto asked was when could we safely omit an axillary dissection. That really is the heart of the matter and the focus of the paper. At his institution and at many other institutions, in treating patients with locally advanced disease, an SLNB is done to confirm the presence of locally advanced disease. Once you have done that SLNB prior to initiating therapy, this effectively precludes you from performing a repeat SLNB subsequent to the therapy. With the increasing efficacy of these neoadjuvant regimens in achieving a CR, the crux of the matter is how to identify those patients who need no additional treatment to the axilla.

Another question Dr Vetto asked regarded looking at other imaging modalities, ultrasound in particular. With ultrasound, many reports have a very high sensitivity for detecting residual disease, but a much lower specificity. The critical aspect is the specificity (ie, if they say that the lymph node basin is negative for residual disease, will that lymph node basin always be negative?). In terms of the question regarding the new enhanced MRIs, there will be further advances in imaging techniques in the not too distant future. The one that Dr Vetto mentioned is an example of that, and it will further improve the results that we have in terms of documenting the extent of the disease after chemotherapy but prior to surgical intervention.

I want to get back to that final question about how we use the information on response to NAC now. Clearly, for patients who are HER2/neu positive, there is a dilemma. The dilemma is predicated on the efficacy of trastuzumab in conjunction with chemotherapy in eradicating disease. A 70% CR rate in these patients with stage III or IV disease is truly a spectacular result. In these patients we have to really critically assess what the value of an axillary dissection is, particularly if the MRI shows no evidence of residual disease at the site of the primary breast tumor. While I agree wholeheartedly that the numbers are small and we need to add additional numbers, I think we have to rethink the meaning of sentinel node results for patients completing NAC. Rather than documenting minimal disease in the node pre therapy, now we have to ask the question, What does a negative or minimally involved sentinel node mean post therapy? As a clear example of that, the 1 patient in the HER2/neu-positive group with a false-negative result had a single lymph node with a 4-mm focus of invasive disease. There was no evidence of residual lymphatic tissue. It was just on the basis of its location, deep in the axilla, that we knew this was a lymph node. If you had not given any therapy prior to surgery, that pathologic result would be interpreted as a replaced lymph node with extracapsular extension. That patient would get additional chemotherapy and radiation therapy to the axilla. However, in the postneoadjuvant setting that 4-mm focus of disease had extensive fibrotic changes around it, consistent with a postchemotherapeutic effect. The question now becomes not do we have disease but what is the clinical significance of that 4-mm deposit, and how should we treat it? That is the question that will become increasingly relevant, as the morbidity associated with breast surgery is almost exclusively in the realm of the axillary dissection.

Financial Disclosure: None reported.

©2007 American Medical Association. All rights reserved.
Downloaded From: http://archsurg.jamanetwork.com/ on 01/24/2017