Image of the Month

Satoshi Omori, MD; Yoichi Ishizaki, MD; Seiji Kawasaki, MD

A 23-YEAR-OLD WOMAN WAS REFERRED TO our hospital because of microscopic hematuria. Ultrasonographic examination revealed a huge mass in the left upper abdomen, and she was admitted for further evaluation. Results of physical and laboratory examinations were normal. Levels of tumor markers (carcinoembryonic antigen, cancer antigen 19-9, DUPAN 2, elastase I) were all within the normal ranges. A computed tomographic scan revealed a low-density, monolocular cystic lesion measuring 9 × 8 cm between the tail of the pancreas and the hilus of the spleen (**Figure 1**). Magnetic resonance cholangiopancreatography demonstrated no connection between the tumor and the main pancreatic duct. After celiotomy, the tumor was resected with the adjacent organ. The resected specimen included a cystic lesion measuring 9 × 8.5 cm (**Figure 2**).

Author Affiliations: Department of Hepatobiliary-Pancreatic Surgery, Juntendo University School of Medicine, Tokyo, Japan.

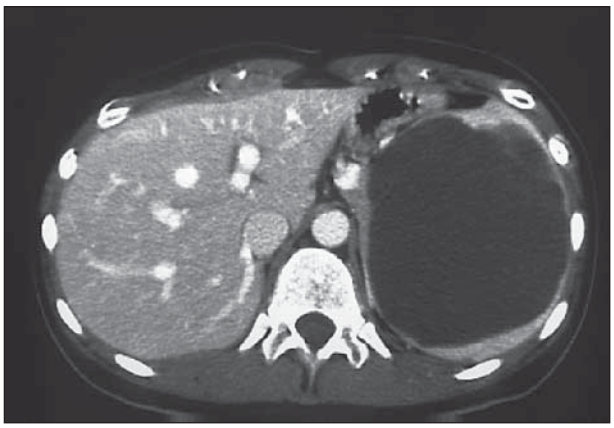

Figure 1. Computed tomographic scan shows an abnormal space-occupying cystic lesion of the pancreas measuring 9 × 8 cm. The mass is located between the tail of the pancreas and the hilus of the spleen.

What Is the Diagnosis?

A. Gastric duplication cyst
B. Epidermoid cyst of the spleen
C. Mucinous cystic tumor of the pancreas
D. Omental cyst

Figure 2. The cystic lesion in the spleen, which measured 9 × 8.5 cm and contained serous yellowish fluid. The cut surface of the surgical specimen revealed a monolocular cyst with slight dissepiment.

©2007 American Medical Association. All rights reserved.
Downloaded From: http://archsurg.jamanetwork.com/ on 01/21/2017