

Image of the Month

Giuseppe Virzi, MD; Salvatore Ragazzi, MD; Placido D'Agati, MD; Sergio Caputo, MD; Davide Mascali, MD; Giovanni Ciaccio, MD; Francesco Scaravilli, MD; Diego Piazza, MD

A WHITE 80-YEAR-OLD WOMAN WAS ADMITTED to our department with postprandial pain in the right hypochondrium for 2 months. The patient's anamnesis included arterial hypertension, diabetes mellitus, and hypercholesterolemia for 10 years. Her surgical history included bilateral inguinal herniorrhaphy.

Blood test results, including complete blood cell counts, renal and liver functions, amylase level, carcinoembryonic antigen level, and α -fetoprotein level, were all normal.

Author Affiliations: First Department of Surgery, Pr. Piazza, Ospedale Vittorio Emanuele, Catania, Italy.

She underwent abdominal echography, which revealed a parietal anterior thickening of the gallbladder with a 1.8-cm echogenic intraluminal formation (**Figure 1**). Computed tomographic scan results were normal. Laparoscopic cholecystectomy was performed without any complication. The patient tolerated the procedure well and was discharged home on the second postoperative day.

What Is the Diagnosis?

- A. Lithiasis of the gallbladder
- B. Adenocarcinoma of the gallbladder
- C. Neuroendocrine carcinoma of the gallbladder
- D. Cholesterol polyp

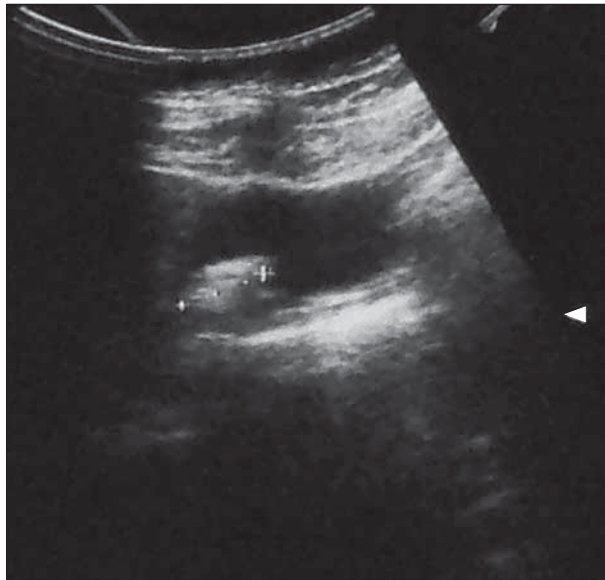


Figure 1. Abdominal echography showing a parietal thickening of the gallbladder.