

## Image of the Month

Yu-Chuan Teng, MD; Kao-Lang Liu, MD; Wen-Hsi Lin, MD, PhD; Shyh-Jye Chen, MD, PhD

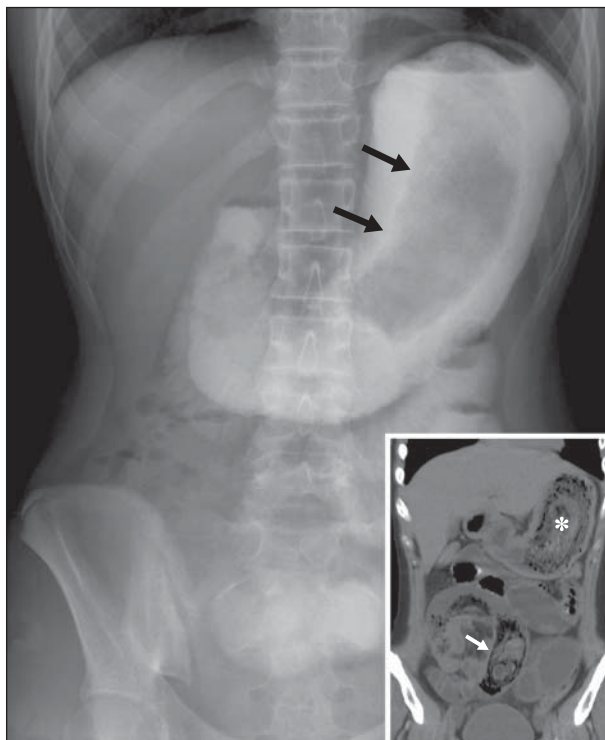
**A** 14-YEAR-OLD GIRL HAD A HISTORY OF CONSTIPATION and epilepsy with irregular anti-convulsant drug control since age 9 years. She had dull abdominal pain in the left lower quadrant that was relieved by bending forward and was aggravated in the supine position. This pain developed 7 days before she came to the emergency department. She also had poor appetite and

was passing only small amounts of stool. The pain became colic, accompanied by nausea and vomiting, 1 day before she came to the emergency department. Physical examination revealed tenderness in the left lower quadrant and hyperactive bowel sounds. An abdominal radiograph and an abdominal computed tomographic scan are shown in **Figure 1**.

What Is the Diagnosis?

- A. Constipation
- B. Bezoars
- C. Intussusception
- D. Volvulus

**Author Affiliations:** Departments of Medical Imaging (Drs Teng, Liu, and Chen) and Surgery (Dr Lin), National Taiwan University Hospital and National Taiwan University College of Medicine, Taipei, Taiwan.



**Figure 1.** The abdominal radiograph shows a large filling defect in the stomach, outlined by the water-soluble contrast medium (arrows). Inset, The reformatted coronal computed tomographic scan reveals the bowel obstruction with large fecal material–like masses impacted in the stomach (asterisk) and small bowel (arrow).