

Image of the Month

Eric Marcotte, MD, MSc; Cheguevara Afaneh, MD; Alfons Pomp, MD, FRCSC; Daniel Cherqui, MD

A 50-YEAR-OLD WOMAN OF CARIBBEAN DESCENT presented to an outside hospital with a history of several months of recurrent postprandial right upper quadrant pain associated with nausea and vomiting. Her white blood cell count and liver function test results were within normal limits. She underwent abdominal ultrasonography and a computed tomography scan of the abdomen, which showed cholelithiasis and a questionable cystic dilatation of the common bile duct. She requested a transfer to the Weill Cornell Medical Center. Serologic test results for *Echinococcus* were negative. A magnetic resonance cholangiopancreatography was ordered to characterize the anatomy. This showed a round

lesion centered in the hepatic hilum measuring $1.9 \times 1.9 \times 2.1$ cm with thin internal septations (**Figure 1**). Although it was in proximity to biliary structures, a direct communication was not visualized. There was no evidence of lymphadenopathy. She was scheduled for a laparoscopic cholecystectomy and resection of the lesion (**Figure 2**).

What Is the Diagnosis?

- A. Mirizzi syndrome
- B. Carcinoma of the gallbladder
- C. Cystadenoma of the cystic duct
- D. Cystic duct cyst

Author Affiliations: Department of Surgery, Centre Hospitalier Universitaire de Sherbrooke, Sherbrooke, Quebec, Canada (Dr Marcotte); Divisions of Laparoscopy and Bariatric Surgery (Drs Afaneh and Pomp) and Hepatobiliary Surgery and Liver Transplantation (Dr Cherqui), Department of Surgery (Drs Afaneh and Pomp), New York–Presbyterian Hospital/Weill Cornell Medical Center, New York.

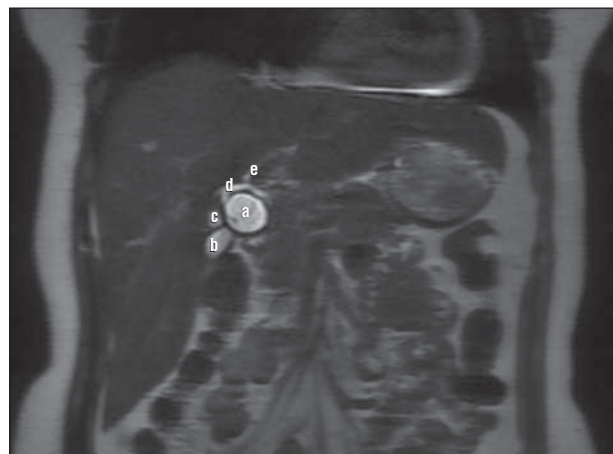

Figure 1. Coronal magnetic resonance cholangiopancreatography view showing the lesion (a) located in proximity to the gallbladder (b), the aberrant right hepatic duct (c), the main right hepatic duct (d), and the left hepatic duct (e).

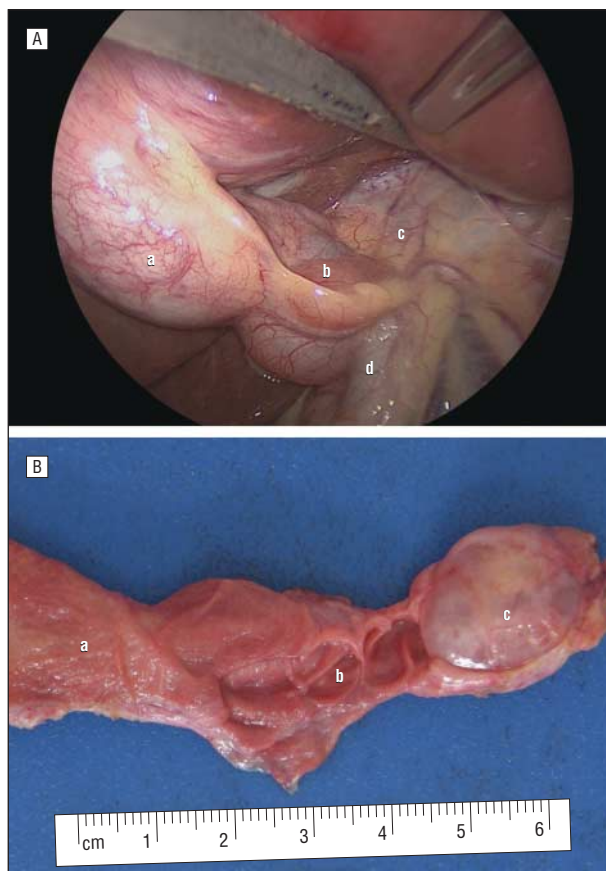


Figure 2. Laparoscopic and specimen images. A, Laparoscopic view at exploration. The gallbladder (a) is in close contact with the lesion (b), which is near the common hepatic duct (c) and the common bile duct (d). B, Macroscopic view of the lesion. Infundibulum of the gallbladder (a), proximal portion of the cystic duct (valves of Heister) (b), and cystadenoma (c).