

Image of the Month

Timothy L. Frankel, MD; Paul G. Gauger, MD

A 51-YEAR-OLD MAN WITH MULTIPLE ENDOCRINE neoplasia type I (MEN I) complained of indigestion, diarrhea, abdominal pain, and fatigue. Previous manifestations of MEN I had included hyperprolactinemia, hyperparathyroidism, pancreatic endocrine tumors, and hypergastrinemia. His symptoms were refractory to high doses of a proton pump inhibitor (oral omeprazole [Prilosec], 80 mg, twice daily). Previous operations included subtotal parathyroidectomy and 3 intra-abdominal neuroendocrine tumor resections (distal pancreatectomy, duodenotomy, and submucosal tumor resection and enucleation of multiple neuroendocrine tumors from the head and neck of the pancreas). Physical examination revealed only previous abdominal scars and slight epigastric tenderness. While the patient was under observation and coincident with worsening symptoms, fasting unstimulated serum gastrin levels increased to 2043 pg/mL (normal range, 25-110 pg/mL) (to convert to picomoles per liter, multiply by 0.481). The human pancreatic polypeptide level was elevated to 439 ng/mL (normal level, <290 ng/mL). Serum chromogranin A level was elevated at 803 pg/mL (normal level, <36 pg/mL). Serum calcium and intact parathyroid hor-

mone levels were normal. Computed tomography (CT) of the abdomen was performed with intravenous contrast and an oral contrast agent (VoLumen; EZ-EM Inc, Lake Success, New York). Several small duodenal wall masses (arterial enhancing) and multiple enhancing masses in the residual pancreatic tissue were detected (**Figure 1**). Endoscopic ultrasonography revealed multiple hypoechoic masses in the pancreas as large as 1.5 cm and abnormal peripancreatic lymph nodes that were oval, hypoechoic, and heterogeneous.

Because of tumor progression and refractory symptoms, an operation was offered. A modified pancreaticoduodenectomy was performed to resect the pancreatic and duodenal tumors and peripancreatic lymph nodes. Examination of the specimen revealed multiple pancreatic tumors and submucosal duodenal masses (**Figure 2**). Histologic examination confirmed that 1 peripancreatic lymph node contained neuroendocrine tumor. The postoperative unstimulated basal gastrin level was 146 pg/mL, and the pancreatic polypeptide level was less than 40 pg/mL.

What Is the Diagnosis?

- Iatrogenic gastric outlet obstruction
- Verner-Morrison syndrome
- Wermer syndrome and Zollinger-Ellison syndrome
- Gastrointestinal stromal tumor

Author Affiliations: Division of Endocrine Surgery, Department of Surgery, University of Michigan, Ann Arbor.

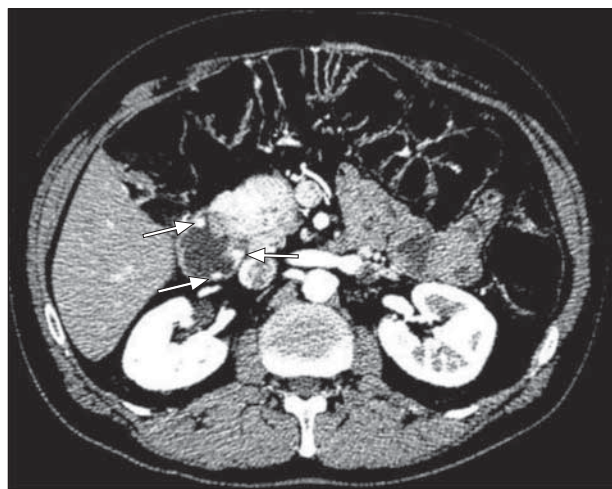


Figure 1. Computed tomography with intravenous and oral (VoLumen; EZ-EM Inc, Lake Success, New York) contrast detects pancreatic tumors and small duodenal tumors (arrows) consistent with neuroendocrine tumors.

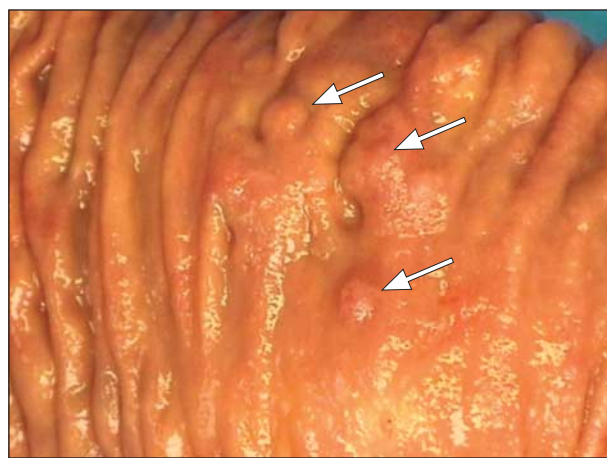


Figure 2. Gross view of the duodenal mucosa shows multiple small submucosal lesions (arrows), corresponding to those seen on computed tomography in Figure 1.