

Image of the Month

Paola Caprino, MD; Marco Pericoli Ridolfini, MD; Stefano Berardi, MD; Luigi Sofo, MD; Domenico D'Ugo, MD

A MAN AGED 57 YEARS WAS ADMITTED TO OUR department for a left cervical and submandibular nodal mass and continuous abdominal pain on his right side. The patient had a medical history of type 2 diabetes mellitus and B-cell chronic lymphocytic leukemia (B-CLL) diagnosed 4 years earlier (stage II according to Rai et al¹; stage C according to Binet et al²). The patient was previously unsuccessfully treated with many cycles of intravenous chemotherapy (chlorambucil plus prednisone and fludarabine) and human monoclonal antibodies (anti-CD52 MAbCampath; Bayer HealthCare Pharmaceuticals, Leverkusen, Germany) for CLL. A restaging computed tomographic total body scan showed a new suspicious mass arising from the thickened posterior wall

of the gallbladder. The lesion was solid, homogeneous, poorly enhanced, and had a large base that adhered to the liver bed (**Figure 1**). Ultrasound examination documented liver steatosis, no focal parenchymal lesion or dilatation of the bile ducts, and no biliary sludge or stones, and confirmed a nodular mass of the posterior wall of the gallbladder not infiltrating the liver bed.

The patient underwent surgery. During laparotomy, the gallbladder revealed a thin anterior wall and a hard sclerotic area of about 45 mm of the posterior wall on the liver bed. The mass did not involve the liver parenchyma. An antegrade cholecystectomy was performed.

What Is the Diagnosis?

- A. Gallbladder carcinoma
- B. Metastasis to the gallbladder neck
- C. Richter syndrome with gallbladder localization
- D. Cholecystitis

Author Affiliations: Department of Oncology, Surgical Oncology Unit, Catholic University, Campobasso, Italy.

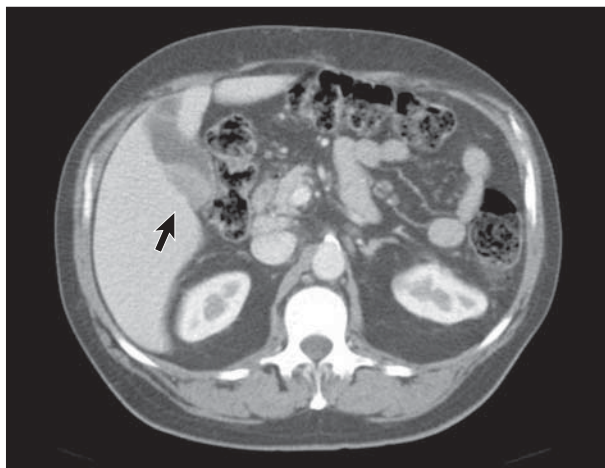


Figure 1. Gallbladder mass arising from the liver bed (arrow).