

## Image of the Month

Alexey Markelov, MD; Harjeet Kohli, MD

**A** 69-YEAR-OLD WOMAN WHO HAD HAD NO primary care physician for more than 40 years presented with swelling in her right arm. She stated that she had been in reasonably good health and had only noticed swelling in the right arm approximately 2 weeks

ago. The patient was found to have a widely neglected fungating chest wound (**Figure 1** and **Figure 2**) with lymphedema in her right upper arm.

### What Is the Diagnosis?

- A. Shingles
- B. Fungating malignant melanoma
- C. Inflammatory breast carcinoma
- D. Chest wall metastases from lung carcinoma

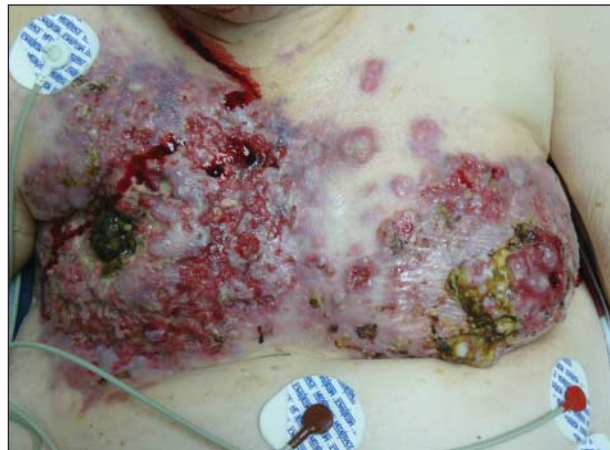

Figure 1. Breast image.

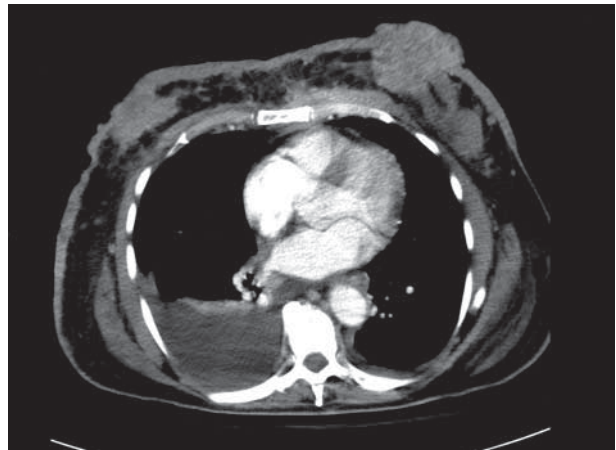


Figure 2. Computed tomographic scan of the chest.